

# CDA

Treatment  
Planning  
Education  
History

JOURNAL OF THE CALIFORNIA DENTAL ASSOCIATION VOL. 29 NO. 11

November 2001



## Implants Have Arrived

Allan C. Jones, DDS



OF THE CALIFORNIA DENTAL ASSOCIATION

# Journal

CDA Journal  
Volume 29, Number 11  
NOVEMBER 2001

## DEPARTMENTS

- 719** The Editor/*Reflection on the Impact of a National Tragedy*  
**723** Impressions/*New CDC Report Backs Fluoride Use*  
**794** Dr. Bob/*Medical Treatment That Suckse*

## FEATURES

- 735** **IMPLANTS HAVE ARRIVED IN CALIFORNIA**  
*An introduction to the issue.*  
 Allan C. Jones, DDS
- 737** **IMPLANT DENTISTRY AND THE CONCEPT OF OSSEOINTEGRATION: A HISTORICAL PERSPECTIVE**  
*Dental implants date back more than 1,000 years, but have really only entered mainstream U.S. dentistry in the past two decades.*  
 Richard M. Sullivan, DDS
- 747** **IMPLANT EDUCATION IN THE DENTAL CURRICULUM**  
*The predoctoral implant program at UCLA provides didactic and hand-on learning.*  
 Perry R. Klokkevold, DDS, MS
- 757** **IMPLANT DENTISTRY EDUCATION FOR THE PRACTICING DENTIST**  
*Universities, implant manufacturers, and study clubs can provide the practicing dentist with the education necessary to provide implant dentistry.*  
 Nicholas Caplanis, DMD, MS; Joseph Y.K. Kan, DDS, MS; and Jaime L. Lozada, DDS
- 766** **TREATMENT PLANNING FOR SUCCESS: WISE CHOICES FOR MAXILLARY SINGLE-TOOTH IMPLANTS**  
*Understanding the esthetic limitations of dental implants will improve the practitioner's chances for success with this treatment modality.*  
 Belinda L. Gregory-Head, BDS, MS; Alex McDonald, PhD, DDS; and Eugene LaBarre, DMD, MS
- 772** **IMPLANT-BORNE SINGLE TOOTH REPLACEMENT -- AN ILLUSTRATION AND RATIONALE**  
*The replacement of a single missing tooth with a dental implant system can simply and easily be incorporated into a general practice.*  
 Richard K. Rounsaville, DDS
- 779** **A CAREER IN IMPLANTOLOGY**  
*Dr. Mel Schwarz is one of the giants of implant dentistry in California.*  
 Steven A. Gold, DDS



## Reflections on the Impact of a National Tragedy

JACK F. CONLEY, DDS

**B**y now, the tragic terrorist-driven events in New York City and Washington, D.C., on Sept. 11, 2001, have been the subject of many discussions and reports. The live pictures and descriptions provided by television that day and in subsequent days will live on in the memory of not only those closely and tragically touched by the atrocity, but by all Americans old enough to understand the implications of this well-orchestrated inhumane act.

While the tragedy of the events was immediate, their larger impact, and the impact of emergency actions undertaken to prevent additional terrorist activity, will likely be to influence or change everything from the manner in which many daily human activities are carried out, to negative influences on the economics of individuals, institutions, and the U.S. government. As this is written, it is too early to forecast the impact of the enormity of the tragedy, or of subsequent actions or events, on our American way of life.

The immediate impact on dentistry in California probably depended upon several factors. If you were in your dental practice, the immediate impact might have ranged from minimal to significant, depending upon such factors as proximity of the dental office to governmental offices in a dense population area that might have been deemed a target for further terrorist acts. In such a case, you might have had to make a decision to close due to safety concerns. You might also have experienced a heavier than normal cancellation rate due to patient

fears. If either instance occurred, you would have likely experienced immediate, but limited, economic impact for a few days.

The impact on the California Dental Association was immediate. CDA headquarters, being mere footsteps from the seat of California government, made the necessary decision to close for the day for safety precautions as there was a real, although uncertain (and fortunately unrealized), threat perceived to hover over government facilities and areas with densely populated high-rise facilities.

The most severe impact on the California Dental Association and many individual members was the cancellation of the Fall Scientific Session that was to be held later that week. Many of the details have been chronicled elsewhere. Despite the obvious tragedy of the early morning events on Sept. 11, late that morning West Coast time, there were still very mixed feelings about whether to move forward with or cancel the Session. Air travel had been suspended until noon the following day, and that might interrupt or cancel the travel plans of East Coast or other out-of-town exhibitors, speakers, and dentists planning to attend. Initially, that did not seem to be a formidable problem when compared with the enormous task of canceling the meeting, informing the many people planning to travel to the meeting, and dealing with the potential economic implications of lost revenues to exhibitors, CDA, and CDA vendors. Of the calls CDA initially received, the attendance plans of exhibitors and members were mixed, with many still wanting the show to go on.

It is reasonable to say that the decision by Executive Staff and the Executive Committee late that day, for many good reasons, was still risky. There was some fear that it might be difficult to communicate the cancellation to individuals planning to attend, causing inconvenience to those who were not reached. There was also some concern that some exhibitors would be offended because of the lost sales opportunity. Many members can attest to the many mail offers and incentives to visit booths that they had received from various exhibitors in the preceding several weeks that would not be fulfilled. The bottom line was there was a nagging human fear that there would be public relations fallout from such an action. In fairness, there had been the contrary fear that a meeting held during a national period of mourning would present a negative.

However, the one unknown that no one could predict was the impact that the magnitude of the human tragedy would have. No one in this lifetime had experienced the after effects of such a catastrophic event on American soil -- thus, in retrospect, it was really not possible to predict what the outcomes would be. It had not been logical to expect that suspension of air flights would extend two additional full days, and then resume at exceedingly reduced levels for some time to come. That had never happened before and hopefully will never happen again. However, the logistics of this event would be felt for some time.

As of this writing, many of the major airlines have reduced their schedules by up to 20 percent and have laid off thousands of personnel. At least in the short term, many people are much more reluctant to undertake air travel, which affects the economics of the airline industry, travel industry, and hotels, and most likely, the attendance at major meetings such as those that CDA and other professional organizations offer. CDA will likely experience less attendance at the next San Francisco meeting

because, historically, when a meeting has not been held for a year (which happens periodically when ADA meetings are held in the city) attendance at the subsequent session shows a dip.

The negative economic impact of cancellation aside, a negative impact on public relations has not been experienced as of this writing. For many reasons, the most notable being the need for a period of mourning following an unexpected national tragedy, the initial results were rather positive. Most amazing to this observer was the information that fewer than a dozen individuals arrived on the Friday morning that the Sessions was scheduled to start. While others traveling shorter distances by car could have arrived later in the day or on the next two days, the very few that arrived at a time when the registration areas are normally overflowing was an indication that three good things had happened.

First, CDA's significant efforts to inform members via Web, fax, e-mail, and news media had been very successful. Second, the shutdown of air travel had probably helped many who might have been continuing to plan to attend realize that it would not be possible to get to San Francisco. Finally, and possibly most importantly, the American people saw the need to reflect and to honor those who had perished in the tragedy of Sept. 11.

Suddenly, the many issues facing California dentistry that had seemed so crucial prior to Sept. 11 were temporarily furloughed from a position of priority in the minds of CDA leadership. Issues such as licensure by credential, the future of the Dental Board, and the amalgam and Proposition 65 legal matters took a few days off from active discussion. A few days after the tragedy, one association volunteer even remarked that in light of the events and their impact on family considerations, he was considering resigning as a delegate to the American Dental Association House of Delegates in Kansas City. This emotion at the time was understandable. While most Americans

expect some modification in our future lifestyles as a result of terrorist threat, we believe that dentistry cannot allow such threats to divert our attention away from conducting the necessary business that will ensure our future ability to undertake our significant health care responsibility to the public. While most Americans seem to have some agreement that "things will never be the same" as they were before these attacks, we do believe that our routines will return to a state of normalcy, likely long before this column is read.

This terrible tragedy also provides us one more opportunity to recognize a segment of our profession that primarily only at times of mass fatality receives recognition for the outstanding continuing work it does for the public. We speak, of course, of those dentists who do forensic work. While it is unknown at this writing how many dentists from California ultimately might have participated, we know that at least three joined their colleagues from other regions of the country to undertake what would be expected to be an extremely difficult task of identifying victims, particularly at the New York site. Police and firefighters frequently are credited in the media for their contributions, largely because of the heroic rescue efforts they undertake in the early phases of a disaster. Having seen photos and descriptions of the work that forensic dentists do under the extremely trying circumstances of a crime or disaster scene, we believe that they should also be recognized for their valuable contributions to society and for the credit they bring to the dental profession.

Out of this tragedy, we have seen many expressions of patriotism and unity. Perhaps the unity demonstrated during this crisis will translate as a positive in many ways. For dentistry, the positive could be that it might help erase some of the hurdles that many believe have existed as the profession has sought to become more inclusive despite its increasing diversity.

## New CDC Report Offers Fluoride Use Tips

BY JANYCE HAMILTON

Dentistry has been touting the benefits of fluoride on dental health for years, and a well-referenced new report from the Centers for Disease Control and Prevention backs those claims.

The CDC in August published a series of fluoride-related findings in *Morbidity and Mortality Weekly Report: Recommendations and Reports*. With the release of "Recommendations for Using Fluoride to Prevent and Control Dental Caries in the United States," the CDC broke some new ground; and its fluoride work group weighed in on the quality of evidence for each fluoride modality's effectiveness, association with enamel fluorosis, and cost.

Marjorie Stocks, MPH, project director for the Dental Health Foundation's Fluoridation Implementation Project, greeted the report with enthusiasm. "We're glad to see that once again water fluoridation is promoted as one of the best measures for individual prevention of tooth decay."

"This report is particularly helpful because it provides a comprehensive review of fluoride modalities from community water fluoridation to professional application to self-administration of fluorides, classified according to grade of evidence, strength of recommendation, and appropriate target population," says Stanley B. Heifetz, DDS, MPH.

Heifetz, a diplomate of the American Board of Dental Public Health and a clinical professor in the Department of Dental Medicine and Public Health at USC School of Dentistry, also cited the report with its 270 references as a "source document for the state of the science of fluoride use."

For those in clinical practice, the report offers five recommendations:

- Continuing efforts to fluoridate community drinking water;
- Counseling parents and caregivers on the use of fluoride toothpaste for children younger than 6, particularly those younger than 2;
- Limiting fluoride mouthrinse

recommendations to patients at high risk for caries;

- Limiting high-concentration fluoride products to people at high risk for caries; and
- Judicious prescribing to and use of fluoride supplements for those at high risk for caries and whose primary drinking water has a low fluoride concentration. This should include informing parents and caregivers of the benefits of fluoride and risks of fluorosis.
- Dentists and others may offer tips to the patient. Such recommendations include:
  - Knowing the fluoride concentration in their primary source of drinking water;
  - Using an alternate source of drinking water for children younger than 8 if the primary source of drinking water is more than 2 ppm fluoride;
  - Frequently using small amounts of fluoride (easily accomplished via drinking optimally fluoridated water and brushing twice daily with fluoridated toothpaste); and
  - Supervising the use of fluoride toothpaste by children younger than 6.
- Dental product manufacturers and public health agencies are advised to take actions to ensure optimal dental health such as:
  - Labeling the fluoride concentration of bottled water;
  - Promoting supervised use of pea-sized amounts of fluoride among children younger than 6; and
  - Developing a low-fluoride toothpaste for children younger than 6.

"Because an appreciable percentage of the population, particularly in Southern California, drink bottled water rather than tap water, the recommendation for labeling fluoride content of bottled water -- whether naturally present or added -- is long overdue," Heifetz says.

According to Heifetz, some larger bottled water companies voluntarily offer their customers fluoride-free or optimally fluoridated water at the same cost.

"I recently had our water distributor switch the bottled water that they supply to the USC School of Dentistry to fluoridated water," Heifetz says.

The CDC report recommends several areas for research in the years ahead, including identifying biomarkers of fluoride, which will estimate a person's total fluoride intake and amount of fluoride in the body, and re-evaluating the existing method of determining optimal fluoride concentration of community drinking water to determine if fluoride consumption patterns and environmental changes necessitate improvements.

To obtain CDC's MMWR Recommendations and Reports Publication: "Recommendations for Using Fluoride to Prevent and Control Dental Caries in the United States" visit <http://www.cdc.gov/mmwr/mmwr.html>; call (202) 512-1800; or write Superintendent of Documents, U.S. Government Printing Office, Washington, D.C., 20402.

## California Water Fluoridation Status

- Seven of the 10 largest California cities currently or are planning to fluoridate their water.
- By 2002, 34 percent of California's population will receive fluoridated water.

Source: San Francisco Public Utilities Commission Water Quality Bureau -- Engineering Section. Fluoridation Feasibility Study: Final Report. February 2001:4.

## UCSF Finds Shortage of Dentists in Rural, Poor, Minority Areas

A shortage of dentists in many communities may contribute to poor access to dental care for many California rural, low-income, and minority residents, according to a new study by UCSF researchers at the Center for the Health Professions.

"We have a crisis in access to care in our state. The numbers of children with untreated dental decay is alarming, particularly in underserved communities," says lead author Elizabeth Mertz, MPA, project director at the center. Even more disturbing are the findings that the communities most in need of services are

the same communities least likely to have them, according to the study published in the summer issue of the *Journal of Public Health Dentistry*.

Access to dental services in California is a public health issue gaining increasing attention. Recent research on the extent of oral health problems has highlighted significant disparities by race and income, both in California and across the nation, Mertz says. The racial and ethnic composition of the health care workforce is also a public health issue, as minority health care providers are more likely to practice in underserved communities.

The study found that two-thirds of communities without dentists are rural, at least 20 percent of California communities may have a shortage of dentists, and many of the same communities do not enjoy the benefits of fluoridated water.

The study also found that minority dentists are more likely to practice in minority communities, but are a small portion of the dental workforce.

"Although this pattern has been previously demonstrated for doctors and nurses, the new study demonstrates this is also true for the dental profession," Mertz says.

Study objectives were to estimate the supply and geographic distribution of dentists in California and to examine the community characteristics associated with the supply of dentists. There were 19,801 dentists in the survey provided by a computerized file from the American Dental Association.

"The plight of rural communities in recruiting and retaining health professionals is not new," Mertz says. "Our research indicated that the undersupply of dentists in rural areas of California is extensive and is not adequately addressed by existing policies to recruit dentists to rural practice."

The report recommends that the issues of access to dentists and oral health care services should be addressed by public policy through programs such as expanded educational opportunities in dentistry for minority students, recruitment of students from rural backgrounds, and targeted den-

## Protein Links Perio and Heart Disease

Elevated levels of C-reactive protein explain one reason periodontal disease could be a risk factor for cardiovascular disease, according to a new study in the *Journal of Periodontology*.

Periodontal disease may cause oral bacteria to enter the bloodstream and trigger the liver to make proteins such as C-reactive that inflame arteries and clot blood, which can lead to heart attacks. C-reactive protein levels identify those patients whose inflammations systems respond most actively to stimuli.

"Until intervention studies are completed, we will not know with certainty whether periodontal disease really can cause heart disease. In the meantime, this study provides one more explanation for why it is very plausible that an infection in the mouth could lead to problems with the heart," says Ernesto De Nardin, PhD, one of the study's researchers.

The study carried out at the University at Buffalo compared C-reactive protein levels in 59 people with moderate and 50 people with advanced periodontal disease to 65 periodontally healthy patients. Adjustments were made for other factors that are known to be associated with elevated levels of C-reactive protein such as age, body mass index, smoking, and blood lipids. Researchers found that 25 percent of the 174 total subjects had C-reactive protein concentrations that have been associated with a higher risk of cardiovascular problems. However, among the 50 people with advanced periodontal disease, the percentage increased to 38. Furthermore, they found that those patients infected with bacteria that cause periodontal disease had the highest levels of C-reactive protein.

tal service programs for the underserved.

"Policies to promote greater participation of underrepresented minorities in dentistry are essential for producing a dental workforce that is responsive to the needs of underserved populations," Mertz adds.

## Time in Space Puts Astronauts' Teeth at Risk

It is well-documented that astronauts who spend weeks in orbit rapidly lose bone density and mass. What has not been recognized is the effect the lack of gravity has on teeth, Cmdr. William Stenberg recently told a meeting of the MARS Society.

Astronauts in space lose bone density and mass at rates up to 10 times that of the earth-bound, Stenberg says. This form of osteoporosis experienced in the zero-gravity environment of space during long missions -- such as a journey to Mars -- could also lead to tooth loss.

Stenberg, a periodontist with the U.S. Public Health Service, presented the difficulties of maintaining oral health in space during the annual meeting of the Mars Society recently at Stanford University. The Mars Society is dedicated to furthering the goals of exploration and settlement of the planet Mars.

As the bone repair mechanisms in the body shut down in space, bone density rapidly degrades and the body is depleted of calcium. While bones can regain strength once the astronaut returns to earth, the tooth loss would, of course, be permanent, Stenberg emphasizes.

Stenberg says the problem is not without possible solutions. Exercise and hormone treatments have shown promise in maintaining some bone density during long space missions.

## British Authorities Target Children's Dental Health

One million British children are to receive free toothbrushes and toothpaste during the next three years thanks to the Brushing for Life campaign.

The project aims to significantly reduce tooth decay in children. By 2003, 5-year-olds are to have no more than one decayed, missing or filled tooth, and seven out of 10 should have no tooth decay at all.

In addition to giving out free toothpaste and toothbrushes, "health visitors" will demonstrate correct brushing techniques and give oral health talks in day care facilities and to playgroups.

Health minister Hazel Blears says, "The government is determined to tackle oral health inequalities. Most recent figures show that over 60 percent of 5-year-olds now experience no tooth decay at all. This is excellent news, but research also shows that in some deprived areas, children can experience three times the amount of dental decay compared to children from more affluent areas.

"This is unacceptable when both dental decay and gum disease are avoidable simply by encouraging young children to develop the habit of brushing their teeth twice a day with fluoride toothpaste. Regular brushing not only helps people maintain stronger and whiter teeth but also improves the number of years people spend free from illness.

"Good oral health early on in life, is essential to prevent difficulties later on in life -- this is precisely what the Brushing for Life project aims to encourage."

## Tooth Tattoo May Encourage Kids to Brush

KidGenics, a children's oral hygiene company, has launched Tooth Tat 2s, a new dental care product disguised as decorative tooth art for kids.

Tooth Tat 2s are temporary, decorative appliques that are placed on tooth surfaces. They come in a variety of theme packages such as the Love Pac and Friendship Pac.

"Research shows that 5-year-olds, on average, reach about 25 percent of their tooth surfaces while brushing, while 11-year-olds reach 50 percent," said Loren Krok, executive vice president of KidGenics and its parent company, Oralgiene USA. "Tooth Tat 2s require a clean dental surface to adhere, therefore kids need to do a thorough job of cleaning their teeth to wear them."

Krok said the dental tattoos have tested well. "Kids loving making a 'statement' with designs on their teeth."

## Science abuzz over decay-fighting bee substance

The potent Brazilian variety of a substance excreted by honeybees to protect their hives could prove to be a powerful agent against tooth decay, scientists at the University of Rochester Medical Center have discovered.

In laboratory tests, the substance propolis, taken from beehives in southern Brazil, cut the caries rate in laboratory animals by about 50 percent, according to the scientists. Bees produce propolis from the digested secretions of trees and other plants and use the material to hold their hives together.

Key to the utility of propolis is its action against glucosyltransferase enzymes, which play an important role in the buildup of dental plaque. According to the scientists, the Brazilian propolis blocked up to 95 percent of the action of glucosyltransferase in a test tube and about 60 to 70 percent on tooth-like surfaces.

Human use of propolis dates back to at least 300 B.C. Today there are creams, lotions and even chewing gum that contain the substance and tout its antibacterial, anti-inflammatory and anti-oxidant properties, an August 31, 2001, UPMC news release said.

## Honors

Harold C. Slavkin, DDS, has been given the Callahan Award by the Ohio Dental Association for his compelling history of scientific research. Dr. Slavkin is dean of the University of Southern California School of Dentistry.

Jack F. Conley, DDS, has been named 2001 Alumnus of the Year for the USC School of Dentistry. Dr. Conley is an associate professor in the Division of Health Promotion, Disease Prevention and Epidemiology at USC and the long-time editor of the Journal of the California Dental Association.

# Implants Have Arrived in California

ALLAN C. JONES, DDS

## AUTHOR

Allan C. Jones, DDS, is a general dentist in Torrance, Calif.

“Implants Have Arrived in California” was chosen for the thematic title to this issue of the *Journal of the California Dental Association* because of its double meaning. Dental implants conforming to the Swedish concept of osseointegration came to California quietly and profoundly. In the sense that this technology came to our shores from foreign origins, dental implants have indeed “arrived” in a physical sense.

Osseointegrated implants did not come to us through our own traditional resources -- the beloved institutions that house the mentors to whom we have always looked for the truth in matters of dentistry. This is why many who read this issue may not be fully aware of what has transpired with regard to implant development. The first implant invasion was carried out by the Swedes, soon after came the Germans and the Swiss. They targeted a receptive group of dental specialists -- prosthodontists and oral surgeons -- who have long been vexed by the failures of conventional dentistry. As a result, some were induced to go abroad for implant training, as it was available in only those countries in which the science originated. Gradually, the dogmatic prescriptions of the originating Swede, P.I. Brånemark, were made available at carefully selected sources throughout the world. Today, the transformation

is complete. These specialist-disciples, -- having examined and utilized the process for some 15 years -- are unequivocally convinced of the efficacy of osseointegrated implants. These dentists have set the standard for all who practice dentistry, and thus dental implants are now the preferred method for tooth replacement in many situations that were formerly the province of traditional prosthodontics. Implants have, therefore, “arrived” in a more profound sense; implants, as used for implant-borne tooth replacements, are now acceptable for use by all dentists, not just dental specialists.

There has been a subtle transformation in dental implant technology that makes its use appropriate for dentists in general practice. The complexity of dental implant therapy has been reduced so that it can readily be used by those dentists with common restorative skills. That is, contemporary osseointegrated dental implant therapy is well within the capability of all who practice general dentistry in this trend-setting state of California. This is the underlying theme of this November 2001 edition of the *Journal of the California Dental Association*.

This issue begins with a history of osseointegration and its application to dental implants, by Richard Sullivan. His firm is the immediate descendant of the company that brought osseointegration to the United States. His comprehensive



article recounts the history that validates this technology. This issue closes with a legal opinion by Art Curley, an attorney frequently engaged in defending dentists who are accused of malpractice. His article makes the case that implants are an accepted, if not a required, method of tooth replacement when viewed from the perspective of jurisprudence. In between are articles that will inform the reader about a variety of aspects of implants such as the current status of dental education regarding dental implants, by Perry Klokkevold; where experienced dentists may gain the knowledge essential to providing implants, by Nicholas Caplanis; treatment planning, by Belinda Gregory-Head; clinical rationale, by Rick Rounsavelle; the limitations of conventional prostheses, by David Felton; and an interview with Mel Schwarz, one of California's most influential implantologists, by Steve Gold. These articles define an achievable standard in the use of osseointegrated implants for all dental practices in California.

I am a general dentist who has been involved with osseointegration since its earliest days in California. The privilege of creating an issue of the Journal was accorded to me by one of my former students, Steve Gold, the associate editor of the CDA Journal. He asked me to create an issue that would be helpful to dentists who have not yet begun to offer dental implants to their patients. He is, like many who have graduated from our best institutions, without a defining dental school foundation in this area. Even though he is a recent graduate, his status is typical of many good dentists who are still wondering what they must know about dental implants.

The authors represent the best in implantology theory and practice. In spite of my limited purview, I believe

that this issue will give the uninitiated a foundation of knowledge for the appropriate application of dental implant technology in their dental practices.

On a personal note, I would like to thank the authors. This issue has required a lot of work and, most generously, a lot of time. On a final note, this issue is also the result of the efforts of my devoted office staff and, in particular, Chris Perez, RDA. I thank them for their many hours of effort outside of their usual job descriptions.

# Implant Dentistry and the Concept of Osseointegration: A Historical Perspective

RICHARD M. SULLIVAN, DDS

**ABSTRACT** Only 20 years ago, the term “osseointegration” was virtually unknown within the United States. The use of endosseous implants to replace dentition, although not unheard of in 1980, fell outside the American dental mainstream in general practice. This article reviews some of the key developments that have ensued since then. Special attention is paid to the concept of osseointegration as it applies to dental general practitioners.

---

## AUTHOR

**Richard M. Sullivan, DDS,**  
is the clinical director of  
Nobel Biocare USA, Inc.

**T**ooth loss is a traumatic, even devastating, occurrence; and this has doubtless been true throughout human history. It is not surprising, then, that humans for millennia have sought to replace their lost dentition.<sup>1</sup> The Etruscans are believed to have created bridgework fashioned from oxen bones some 2,500 years ago. Likewise, the notion of dental implants has its roots in antiquity. Archeologists have found evidence that occupants of what is now Honduras as long as 1,000 years ago developed a way to use tooth-shaped stones as dental implants.

In Europe, the earliest reference to an implant in modern literature appeared in a French work published in 1809; and by the late 1800s, dentists on both

sides of the Atlantic were experimenting with implants made of such things as extracted teeth (human and animal) and lead. As the first half of the 20th century unfolded, dental innovators continued to search for materials and designs that would survive for more than a brief period after implantation. One breakthrough came in 1941, when a Swedish doctor named Gustav Dahl placed a metal structure below the periosteum; vertical extensions protruded through the gingiva. Impressed by this work, two dentists from Providence, R.I., Aaron Gershkoff and Norman Goldberg, brought the technique for placing subperiosteal implants to the United States, an achievement that attracted attention from other American dental practitioners. In 1951, 30 dentists met in St. Louis to form the American

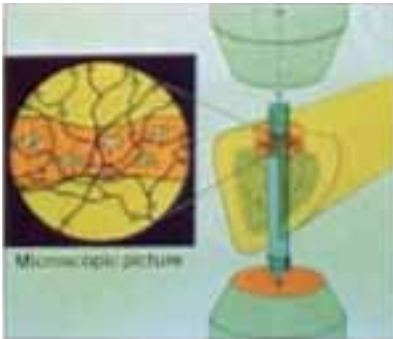


FIGURE 1.



FIGURE 3.

Academy of Implant Dentures (later known as the American Academy of Implant Dentistry).<sup>2</sup>

Another advance came with the work of Leonard I. Linkow of New York, who in 1964 introduced a self-tapping titanium implant. For cases in which bone was limited, Linkow later created a blade implant that eventually became the most widely used implant design in the 1970s.<sup>3</sup>

By 1978, a National Institutes of Health-Harvard University consensus conference was held to examine the implant modalities predominant at that time: subperiosteal, blade, vitreous

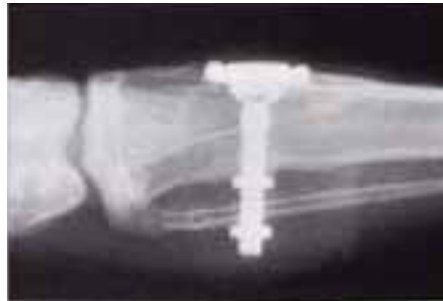


FIGURE 2.

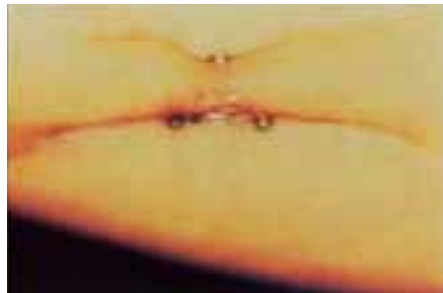

FIGURE 4.

**FIGURE 1 THROUGH 4.** Brånemark first used a lens encased in titanium to be installed in the bones of living rabbits. This method of observation is called vital microscopy. This was followed by titanium-sheathed lenses placed in graduate students' upper arms. These experiments in vital microscopy established both the bone and soft tissue compatibility of titanium as an accidental finding.

carbon, and staple. This conference identified benefits and risks of implants, and a panel made specific recommendations for patient informed consent. As a historical note, Dr. Isaih Lew, then associate clinical professor of implant dentistry at New York University, had wanted screw-shaped implants to be included in the conference. Because they were not "current technology" in the United States at the time and the conference organizers were unaware of European developments, the program excluded them.<sup>4</sup>

## European Efforts

By the time the first Harvard consensus conference was held, a number of crucial developments were already under way in Europe. In Switzerland, Dr. Andre Schroeder, chairman of the University of Berne, was working to develop a dental implant system for clinical use. This work was done in conjunction with the Institute Straumann, a pioneer in the use of metal products in orthopedic surgery. Dr. Schroeder's experiments, first reported in 1976 in the German-language Swiss Dental Journal, histologically demonstrated the in-growth of bone into titanium plasma-sprayed hollow endosseous implants.<sup>5</sup>

At the same time, Professor Willi Schulte of the University of Tübingen in Germany was reporting success with immediate placement of vitreous carbon implants after dental extraction.<sup>6</sup> Work with this design would eventually lead to the Frialit-2 implant.

## Brånemark's Contribution

In Sweden, similar research was to have an even more profound impact on dentistry. It had its genesis in an accidental discovery made in the 1950s by a Swedish physician named Per-Ingvar Brånemark. An anatomical and experimental biologist, Brånemark was interested in studying bone healing response and regeneration. To observe the functioning of bone marrow in vivo, a process known as vital microscopy, he adapted an experimental chamber that had been used in England for insertion into rabbit ears. Unable to obtain tantalum (the material used in the original design), he instead used titanium to make a chamber that could be inserted into rabbit legs to allow microscopic visualization of vital processes. After a months-long series of investigations, he sought to retrieve the chamber for reuse and found to his annoyance that it could not be removed from the rabbit bone.<sup>6</sup>

Brånemark reportedly was not struck by the significance of this turn

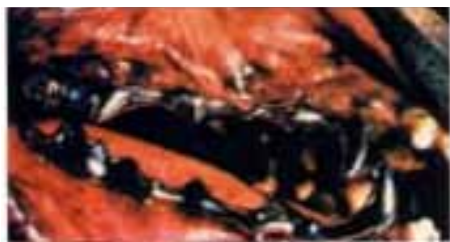

FIGURE 5.



FIGURE 6.

**FIGURE 5 THROUGH 7.** Functioning implants supporting fixed bridges in dogs and the eventual analysis of the implants provided understanding of the mechanisms to achieve this state of osseointegration before the first humans were operated on.



FIGURE 7.

of events until some time after 1960, when he accepted a professorship in the Department of Anatomy at Gothenburg University. There, using an adaptation of the titanium chamber placed in the upper arms of human “volunteers” (also known as graduate students), he and his team investigated the workings and structure of human blood cells under a number of conditions, including response to cigarette smoking. This work yielded a great deal of information about the nature of blood, and it showed the researchers that the titanium serving as lens casings appeared uniquely compatible with the human soft tissue and skin, provoking no adverse immunological reactions. At this point, Brånemark began to contemplate using titanium for medical applications (Figures 1 through 4).

In the years that followed, Brånemark and his team pursued this vision along a number of fronts. They designed titanium screws and inserted them into the jaws of beagle dogs, studying the conditions needed to achieve a solid bond between the bone and the metal (Figures 5 through 7). They studied the biomolecular processes that occur when titanium is placed in living tissue. As this understanding advanced, Brånemark believed it necessary to coin a new term to refer to the in-growth of the bone into the threads and crevices of titanium. He finally settled upon “osseointegration,” derived from the Latin words *os* (bone) and *integro* (to renew).

By 1965, the Swedish team felt ready

to apply its findings to human patients. Although they had originally planned to work with knee and hip joint surgeries, they instead selected as their first human subject a 34-year-old man who had been born with a deformed chin and jaw. Brånemark inserted four titanium fixtures into the man’s mandible, and several months later he used the fixtures as the foundation for a fixed set of false teeth. The fixtures survived, the patient’s life was transformed, and Brånemark resolved to develop more techniques for dealing with dental rehabilitation.

By 1975, Brånemark’s findings and techniques had won approval from an independent team of three professors who reported to the Swedish National Health and Welfare Board that “treatment with a jawbone-anchored bridge construction can and should be used as a complement to conventional prosthetics.” A year later, in April of 1976, the Brånemark method became fully covered by the Swedish national health insurance system, and Brånemark began training the first Swedish dental experts in his techniques in October 1977.

Almost five more years would pass, however, before Brånemark’s findings would explode like a bombshell upon the consciousness of North American dentists. George Zarb, a dentistry professor from Toronto University who had trained under Brånemark in Sweden and then replicated his results independently, orchestrated this development. In May of 1982, Zarb

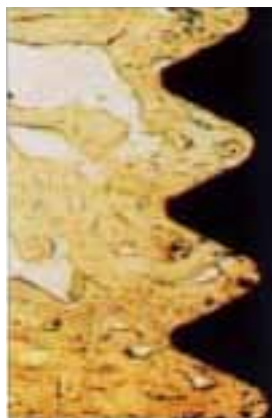organized the Toronto Conference on Osseointegration in Clinical Dentistry. The well-respected Zarb personally invited all the leading researchers in American and Canadian dentistry to the conference, and representatives from more than 70 universities responded. At this forum, Brånemark presented the results of his 15 years of meticulous human and animal research.

### U.S. Developments After the Toronto Conference

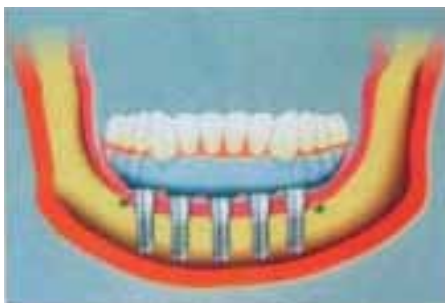The weight of the scientific evidence, combined with Brånemark’s charismatic personality, convinced a substantial percentage of the Toronto attendees that dental implants should at last be taken seriously. Shortly after the conference, researchers from the Mayo Clinic and Mayo Medical School obtained training in Brånemark’s methods in Sweden; and the following year, the Mayo Clinic became one of five academic institutions in North America designated to train dental specialists (oral surgeons and, later, periodontists) in the surgical techniques. Under Brånemark’s initial policy, restoration was to be carried out by prosthodontic specialists (with general dentists to follow).

Another consequence of the 1982 Toronto conference was the formation of a study club by a group of dental clinicians from the greater New York area. Their intent was to share research and information about osseointegration, and they eventually formed a national



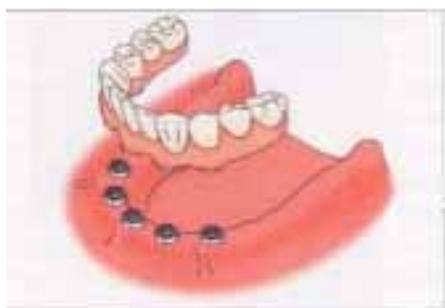

**FIGURE 8.** "Osseointegration" implies rigid adaptation of the implant in the host bone site, with no intervening soft tissue layer visible at the light microscope level.

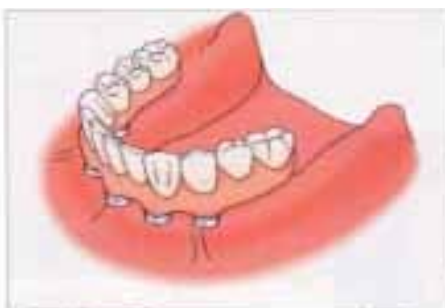

**FIGURE 9.**

organization to foster education and advancement in the field of implant dentistry. In April of 1986, the first annual meeting of the Academy of Osseointegration was held in Chicago. It was at this point that a differentiation between implant-delivery formats became apparent in the United States. In a general sense, "multimodal implant dentistry" encompasses a wide range of formats,



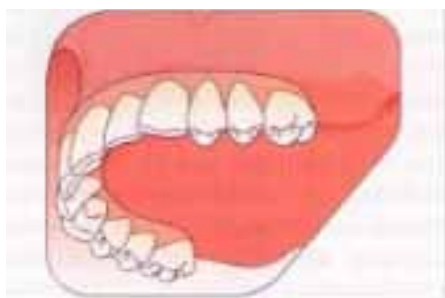**FIGURE 10.**



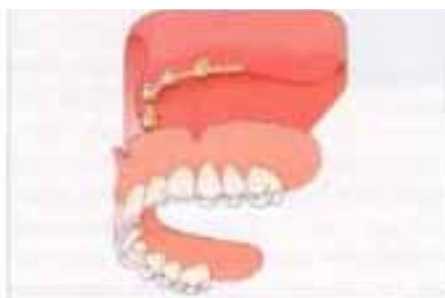**FIGURE 11.**



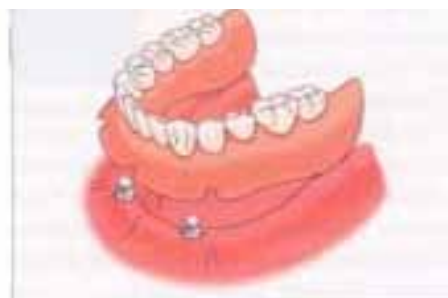**FIGURE 12.**



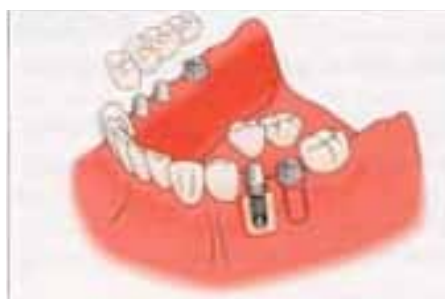**FIGURE 13.**



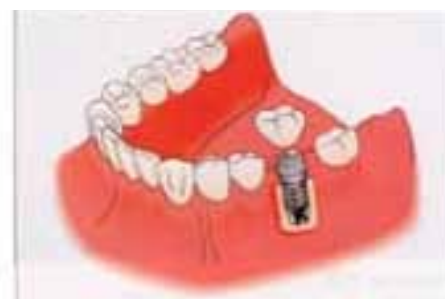**FIGURE 14.**



**FIGURE 15.**



**FIGURE 16.**



**FIGURE 17.**

**FIGURES 9 THROUGH 15.** Osseointegrated dental implants were first applied to the fully edentulous jaws. The rigid functional stability they provided was superior to previous augmentation methods. In Sweden, there was an emphasis on fixed restorations in both jaws. Other parts of the world, including the United States, have developed overdenture alternatives utilizing dental implants.

**FIGURES 16 THROUGH 17.** Soon after rehabilitation of the fully edentulous patient was introduced, American dentists started applying these principles to the missing single tooth and short-span segmental restoration.

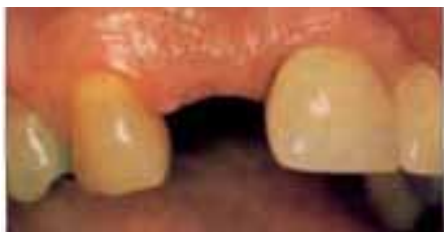

FIGURE 18.

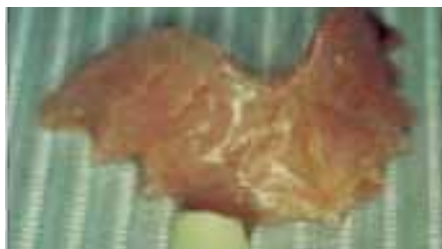

FIGURE 19.

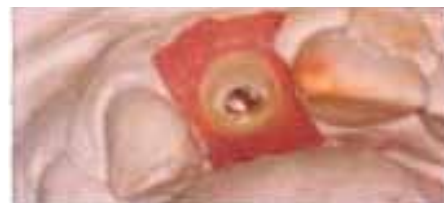

FIGURE 20.

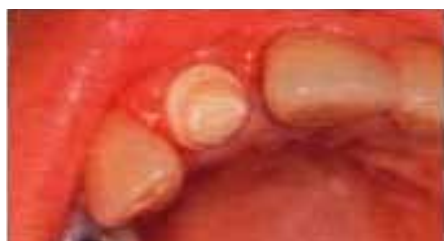

FIGURE 21.

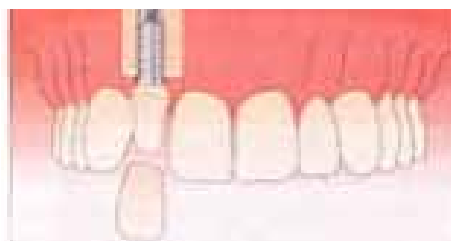

FIGURE 22.

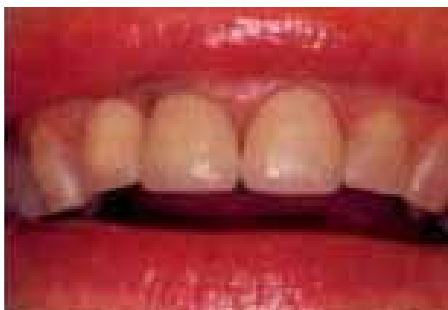

FIGURE 24.

**FIGURES 18 AND 24.** The transition from function full arch to esthetic single tooth replacement has entailed a deeper understanding of the implications of soft tissue on the esthetic result. Advances in components, such as this ceramic abutment, allow cemented restorations analogous to everyday restorative procedures in general practice. In this instance, the osseointegration approach prevents the preparation of an unrestored canine tooth, and also prevents the remaking of a crown that would require a midline shade match.

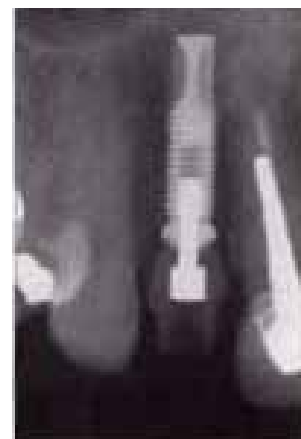

FIGURE 23.

including blade or plate-form implants, subperiosteal, ramus frame, and cylindrical endosseous implants. These implants may rest on or be encapsulated within the bone. Today, when people use the term “osseointegration” they generally imply the installation of cylindrical implants in a manner to ensure rigid fixation of the implant without an intervening fibrous or soft-tissue layer. The osseointegration approach as the foundation for tooth replacement by far predominates other methods, but other implant modalities continue to have adherents.

In the early 1980s, recognizing the need for research to substantiate patient safety for dental implants based on research, an American Dental Association council adopted

a resolution that permitted dental implants to be submitted for review. In 1985, Nobelpharma, the company manufacturing Brånemark's implants for commercial use, submitted the first application, with approval coming the following year.

Since 1985, the American Dental Association's initial use of the word “approval” has given way to the term “acceptance.” Eleven implant systems have received the ADA Seal of Acceptance (**TABLE 1**). In addition, two implant systems have received provisional acceptance: Astra Tech Implants for partially edentulous indications (Astra Tech, Inc.) and MicroVent Dental Implants (Sulzer Dental, Inc.).

## A Continuing Evolution

During the past 20 years, the field of osseointegration has witnessed a number of significant developments in the United States. One of the most notable is the expansion of the treatment indications. Treatment indications are a method of segmenting the field of osseointegration for discussion purposes; historically, dental restorations supported by osseointegrated implants evolved in this order:

- The fully edentulous lower jaw (Figures 9 through 15);
- The fully edentulous upper jaw;
- The short-span edentulous segment; and
- The missing single tooth.

Treatment indications are important

in any discussion of osseointegrated dental implants because not all concepts apply to all indications. The subjective symptoms of the patient seeking treatment, the patient's expectations regarding treatment outcome, anatomical limitations, and the components used all may vary widely, depending upon the treatment indication.

When Brånemark presented his findings at the 1982 Toronto conference, dental implants up to that point had only been utilized for fully edentulous jaws (upper or lower), and the treatment was only recommended for individuals in this category. That might appear to defy logic, since placement of implants for a fully edentulous arch may appear more complex than replacing only one tooth or using implants to support a short-span bridge.

However, the context of Brånemark's early research explains why the field developed as it did. Anxious to avoid the possibility of making any patient's condition worse, Brånemark selected

**Table 1. Implant Systems with ADA Acceptance**

Manufacturer	Implant System
Astra Tech, Inc.	Astra Tech Implants
Nobel Biocare USA, Inc.	Brånemark System Dental Implants
	IMZ 4.0mm Implant System
	Steri-Oss HA-Coated Titanium Screw Type Dental Implants
	Steri-Oss Titanium Screw Type Dental Implants
Straumann Co.	ITI Dental Implants
Sulzer Dental, Inc.	Integral Endosseous Implant System
	Integral Omniloc Endosseous Implant System
	Omniloc Dental Implant System with Interface Ring
	Spline HA-Coated Cylinder Dental Implant System

for his early research subjects only individuals whom he classified as “dental cripples.” These were people suffering from catastrophic dental failures, for whom traditional treatments were no longer an option. For such people, any success with dental implants would be an improvement.

Soon after the first Americans were trained in Brånemark's method in Sweden, they began to adapt and apply these methods for other treatment indications, specifically single-tooth and short-span fixed partial dentures. In one sense, this was a logical thing to do. If Brånemark demonstrated that a full arch of teeth could be successfully restored on four or five implants, it seemed an obvious extrapolation that a three-unit bridge could be done on two implants (Figures 16 and 17).

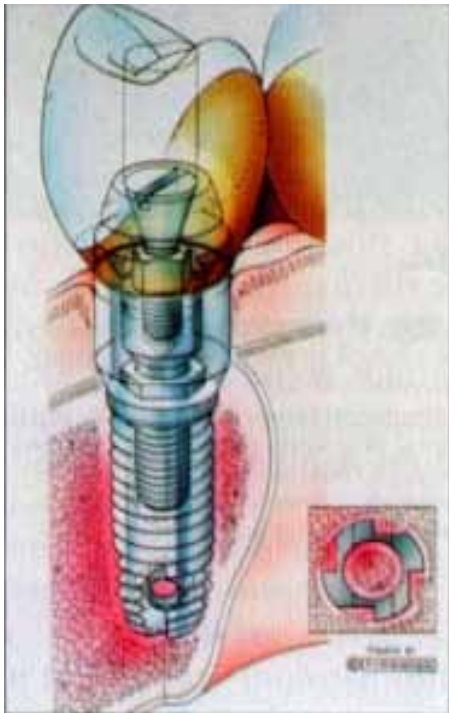
However, while the early adopters experienced many successes with the expanded utilization, unanticipated complications and failures also resulted. The first studies demonstrating the efficacy of implants for single-tooth and short edentulous span indications began appearing in the early 1990s. As they have accumulated, understanding has grown of the unique biomechanical factors that must be considered for each treatment indication. Dentists and their patients can benefit from the experiences gained

during these developmental years.

A second important development has been the gradual shift in attention to the creation of esthetic restorations. In the mid-1980s, implant practitioners were focusing on functional rehabilitation of the fully edentulous patient. Esthetic results were secondary to the profound impact on patients' life quality that resulted from having a truly fixed restoration after functioning with denture adhesives for 30 years or more. But as dentists sought to offer osseointegrated dental implants on a more routine and elective basis, demand for esthetic results that were at least comparable to other forms of dentistry grew.

Implant dentistry in the 1990s experienced a transition from functional rehabilitation to esthetics, with esthetic results improving throughout the decade. One aspect of this transition has been the development of components specifically designed for the single-tooth restoration or segmental bridge (Figures 18 through 24).

What has also emerged is a more detailed understanding of the relationship between residual bone volume and papilla height, along with treatment planning to correct soft-tissue deficits either surgically or prosthetically. It has become apparent that changes in the soft-tissue contours in the post-tooth-loss resorptive process have the greatest impact upon the final



**FIGURES 25.** The physiologic health of the living bone, peri-implant tissue, and functioning restoration help determine long term success.



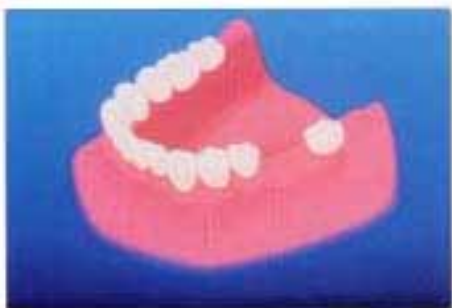

FIGURE 26.

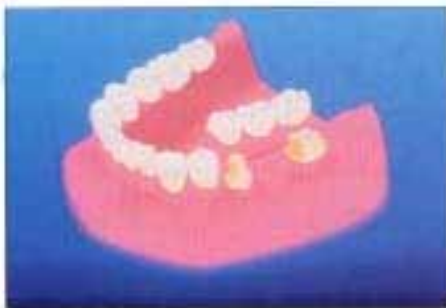

FIGURE 27.

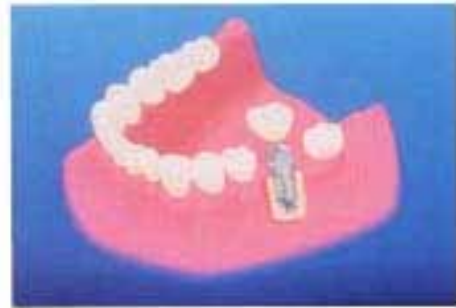

FIGURE 28.

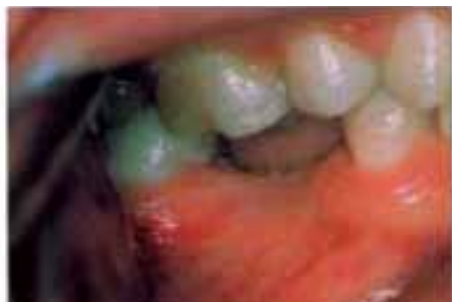

FIGURE 29.

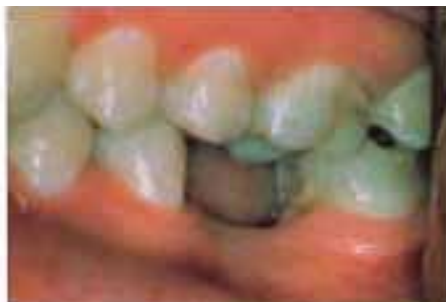

FIGURE 30.

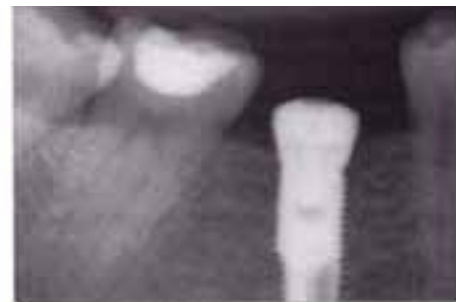

FIGURE 31.

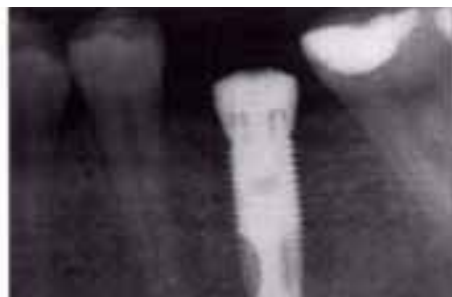

FIGURE 32.

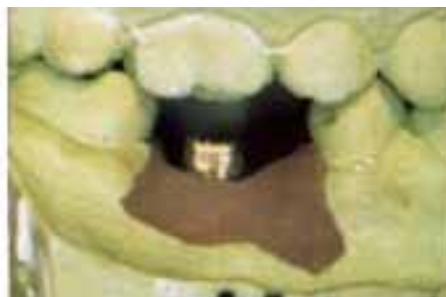


FIGURE 33.

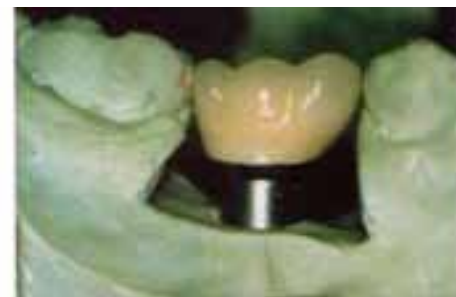

FIGURE 34.

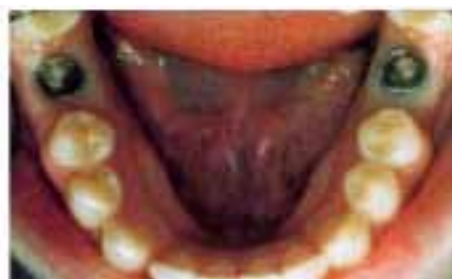

FIGURE 35.

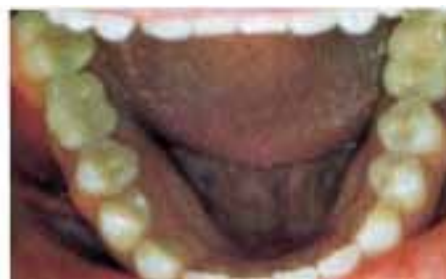

FIGURE 36.

**FIGURE 26 THROUGH 36.** Dental implants have evolved to the point of becoming the more conservative treatment to replace a missing single tooth. Placement of two implants in a one-stage surgical procedure provide the foundation for customized titanium abutments and all-ceramic crowns to be cemented without preparation of unrestored and vital potential abutment teeth.



restorative esthetic result. During the past two decades, the focus on bone and implants has been joined with an equal focus on ceramics and soft tissue (FIGURE 25).

Another significant change has come in the manner in which osseointegrated dental implant restorations are delivered. In the 1980s, dental implant restorations were not only primarily of a full-arch nature, but they were also screw-retained. That is, the dental restoration was attached to the implant or implant abutments with the use of small set screws. From a research perspective, especially with unknown outcomes at the outset, this was very practical. It made the restoration retrievable by the dentist so it could be modified or the status of the individual implants could be experimentally assessed. During the 1990s, however, as more general dentists and dental laboratory technicians have entered the field, a rapid changeover to cemented restorations has occurred. These implant restorations more closely resemble their natural tooth counterparts and do not require the same intricacies in fabrication as a screw-retained restoration. Long-term provisional cements seek to retain the retrievability of cemented restorations. Today, virtually any restoration can be done in either a screw-retained or cemented fashion, provided this preference is accounted for in the treatment-planning process.

### Current and Future Perspectives

Today, approximately 450,000 osseointegrated implants are being placed every year. The fastest-growing treatment indication is the single-tooth replacement. At one time, a dental implant was thought to be an aggressive treatment of last resort. Today, replacing a missing single tooth with an implant-supported crown has a reasonable expectation of a 95 percent success rate. Compared to the preparation of healthy, vital natural abutment teeth, many dentists realize and embrace the idea that the single-tooth implant is actually a more conservative

treatment for the patient in the long term (Figures 26 through 36).

Despite all the successes, a couple of factors have impeded still wider acceptance of implants as a treatment modality. For one thing, dental insurance continues to lag behind the technology. Academic training in implant techniques has also developed slowly. For the most part, implant dentistry still is not being taught at the undergraduate level. Dentists must acquire their knowledge about treatment planning, implant placement, and hands-on restorative procedures as a postgraduate pursuit, either from residencies or approved continuing education courses. Ongoing study-club participation supports development in a group-learning context and provides the opportunity for mentorship.

Even with the obstacle of dental implant proficiency being a post-graduate pursuit, implant-supported dental restorations are definitely on an upswing in the United States. More patients are choosing to have their teeth replaced without having their adjacent teeth ground. They are understanding the long-term benefits and decreased risk of complications by avoiding preparation of abutment teeth.

Dentists are recognizing that implant-supported restorations are often the most conservative and predictable approach to tooth replacement. Offering patients this alternative represents the standard of care in informed consent. The author's position is that every restorative dentist in the United States should at least be providing cemented single-tooth and short-span segmental restorations on dental implants, and lower overdentures on ball attachments.

The historical perspective of osseointegration demonstrates that these developments are now part of the mainstream armamentarium for routine treatment planning for the replacement of missing teeth. Dental patients can experience routine benefits with

minimum risks and complications based on the careful developmental footsteps established by the foresight of the early innovators.

### REFERENCES

1. Ring ME, A thousand years of dental implants: a definitive history -- Part 1. *Compendium* 16(10):1060-9, 1995.
2. American Academy of Implant Dentistry (<http://www.aaaid-implant.org>).
3. Ring ME, A thousand years of dental implants: a definitive history -- Part 2. *Compendium* 16(11):1132-42, 1995.
4. Schnitman PA, Shulman LB, Dental implants: benefits and risks. *Proceedings of an NIH-Harvard Consensus Development Conference, U.S. Department of Health and Human Services, December 1980, Publication No. 81-1531.*
5. Laney WR, In recognition of an implant pioneer: Professor Dr. André Schroeder. *Int J Oral Maxillofac Impl* 8(2):135-6, 1993.
6. Schulte W, Heimke G, The Tübingen immediate implant. *Quintessence* 27(6):17-23, 1976.
7. Williams E, A Matter of Balance. AB Akademiförlaget, Göteborg, Sweden.

# Implant Education in the Dental Curriculum

PERRY R. KLOKKEVOLD, DDS, MS

**ABSTRACT** The success of osseointegrated dental implants has forever changed dentistry and, thus, undergraduate dental education. With the tremendous clinical acceptance and increased patient demand for dental implants, dental school educational programs must prepare students to treat patients with this modality. The purpose of this article is to provide an overview of the predoctoral dental implant educational program at the University of California at Los Angeles School of Dentistry.

---

## AUTHOR

**Perry R. Klokkevold, DDS, MS**, is an associate professor and the clinical director of the postgraduate periodontics residency at the University of California at Los Angeles School of Dentistry in the Division of Associated Specialties, Section of Periodontics.

**D**ental implant therapy is an essential part of dentistry. Research has established the biological basis for and documented the long-term predictability of dental implants, which has promoted the acceptance of their clinical use. The success of osseointegrated dental implants has forever changed dentistry and, thus, undergraduate dental education. It has changed the perspective of clinicians and educators on many aspects of dental therapy. Dentists have witnessed a paradigm shift from the practice of saving teeth at all cost to one that considers extraction of compromised teeth to improve the esthetics, function, and long-term prognosis of the entire dentition with the application of this technology. For some cases, such as the

missing single tooth, implant therapy is becoming the standard of care because it is predictable and often more conservative than a conventional crown and bridge.<sup>1</sup> Additionally, patients have become educated and appreciate how implants can benefit their oral health, esthetics, and function. As a result, more and more patients are seeking dental implant therapy. According to a recent American Dental Association survey, the number of dental implant procedures being done in the United States tripled from 1986 to 1997; and this trend is expected to continue.<sup>2</sup>

In July 1990, 62 faculty members from 49 U.S. dental schools gathered in Chicago to review, revise, and approve curriculum guidelines for predoctoral implant dentistry.<sup>3</sup> This conference was a joint effort

by the American College of Oral Implantologists, the University of Pittsburgh School of Dentistry, and the American Association of Dental Schools.<sup>4</sup> The curriculum guidelines established at the conference were embraced by many dental schools, which have used them to design their implant educational programs.<sup>5</sup> The guidelines suggested that upon completion of the dental school program, dental students should be able to identify and discuss aspects of implant dentistry, including a historical background and current trends in dental implantology. With this knowledge, students would be expected to describe both surgical and prosthetic procedures used to provide implant therapy. The proceedings of this conference made no recommendations for laboratory and/or clinical experience in the predoctoral curriculum guidelines. The guidelines recommended that dental students be given lecture format instruction in implant dentistry and that courses should be taught to the level that achieved exposure and understanding.

In an article written for the *Journal of the California Dental Association* nearly a decade ago, Dr. Howard Landesman stated, "A student graduating in 1996 should have a background in implant dentistry which permits him/her to use this treatment option in any individual who is partially or totally edentulous."<sup>6</sup> He was referring to the need for a curriculum in implant dentistry, as part of the predoctoral curriculum, that conferred competence greater than that of exposure and understanding. Obviously, with the tremendous clinical acceptance and increased patient demand for dental implants, dental school educational programs must prepare students to be able to assess for, plan for treatment with, and treat patients with dental implants.

Clearly, there is a need for dental implant education in the predoctoral curriculum of dental students. In response to this need, most North American dental schools have implemented some form of dental implant education.<sup>7-9</sup> However,

incorporating new dental implant courses into an existing dental school curriculum has not been without challenge. The most commonly cited challenges include:

- A lack of adequately trained faculty to teach courses;
- Not enough time in an already overfilled dental school curriculum; and
- Scarce financial resources.<sup>9-11</sup>

Today, many specialists have been trained; thus, the first challenge should not be an issue. The second challenge remains because of the difficulty in eliminating more-traditional aspects of dental school education curriculum in order to accommodate an implant educational program. The financial challenge has been addressed in some cases with the aid of implant companies.<sup>11</sup>

The purpose of this article is to provide an overview of the current predoctoral dental implant educational program offered at the University of California at Los Angeles School of Dentistry. The dental implant educational program within this institution evolved as an extension of the advanced prosthodontic courses. It is structured to provide dental students with a basic learning experience in implant dentistry, including hands-on laboratory sessions and opportunities to provide implant therapy for patients.

### Didactic Educational Program

Implant dentistry is a multidisciplinary therapy comprising surgical and restorative requirements. For this reason, dental implant education is typically taught in segments, with specialists teaching within their respective domains. Implant education began with specialists teaching only their respective (surgical or prosthetic) areas of implant dentistry to dental students as part of their specialty departmental courses. However, the separation of surgical and restorative aspects of implant dentistry sends the wrong message to dental students. To teach the concept that the surgical procedures are performed to achieve a restorative goal, a more-integrated approach has been created. Teaching

different aspects of implant dentistry in separate courses unnecessarily segments the treatment concepts into separate entities. Since implant therapy always results from a surgical procedure followed by a restorative procedure, it is more logical and effective to teach these different aspects as part of a continuous course. Furthermore, teaching courses that are separated by specialty results in an unnecessary repetition of certain subjects, such as history and treatment planning.

The primary concept being taught at the UCLA School of Dentistry is that treatment plans are primarily driven by restorative needs. That is, the restorative plan ultimately determines the surgical needs. For this reason, the dental implant curriculum at UCLA has been developed to bring specialists together with a unifying curriculum designed to teach students in a continuous series of courses. This curriculum, which emphasizes the prosthetic/restorative aspects of implant dentistry, is an extension of the advanced prosthodontic courses with lectures given primarily by the prosthodontic specialists and restorative faculty augmented with lectures given by the periodontal and oral and maxillofacial surgery faculty. Lecture presentations cover topics including but not limited to:

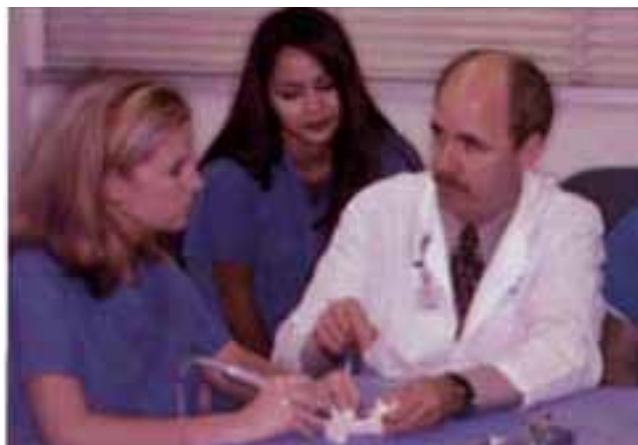- The biologic and scientific basis of osseointegration;
- Patient evaluation, diagnosis, and treatment planning;
- Basic implant surgery procedures along with postoperative patient management;
- Basic implant prosthodontic procedures; and
- Implant maintenance protocols.

The predoctoral didactic educational program in advanced prosthodontics and implant dentistry at UCLA consists of 30 hours of lecture over two quarters with a minimum of four hours of laboratory hands-on experience. The Section of Removable Prosthodontics teaches the primary core course in implant dentistry for predoctoral dental students with

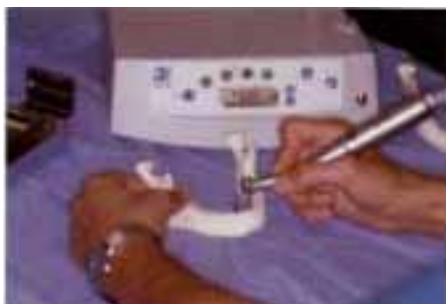prosthodontists providing most of the didactic educational program. Surgical specialists (periodontists and oral surgeons) provide instruction on the surgical aspects of implant dentistry as part of this core educational course. The Sections of Periodontics and Oral and Maxillofacial Surgery continue to teach some aspects of surgical implant therapy as part of their respective specialty courses. This facilitates their ability to stress the importance of implant surgery in their courses.

The course format consists of a series of lecture presentations, laboratory hands-on experience, and Internet access to study materials. The didactic course begins with a historical perspective on dental implants from subperiosteal implants to the current status of osseointegrated endosseous dental implants. The biological basis for osseointegration is supported with evidence from the literature. Patient assessment, diagnosis, and treatment planning for the various types of implant cases are emphasized as a major part of the course. Evidence from the literature is used to support the concepts being taught. Procedures used in implant therapy are presented in detail with follow-up laboratory sessions in which students participate. Tables 1 and 2 list the behavioral objectives and lecture topics for the UCLA predoctoral series of dental implantology courses.

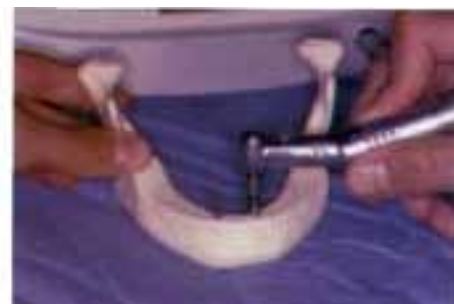Recently, the Internet has been utilized effectively as a means of providing study materials to students. Lecture materials prepared by faculty are accessible to students via the Internet. A password-protected Web site has been established, which makes available the entire course lecture material as given in class with photos, figures, and text. The Web site offering of this course is intended to give students unlimited access to lecture material for study and review rather than as a substitute for class attendance. Class attendance is required, and a written final examination is given at the end of each quarter to test competence in learning course materials.



FIGURES 1A.



FIGURES 1B.



FIGURES 1C.

FIGURES 1A-1C.

Laboratory hands-on experience in the surgical preparation and placement of screw-type, cylindrical dental implants in a plastic jaw.

### Laboratory Hands-on Experience

As part of the dental implant education, dental students participate in both surgical and prosthetic hands-on sessions in the laboratory. In the surgical hands-on session, students prepare and place multiple screw-type, cylindrical implants in a prefabricated edentulous mandible model. Clinical slides and a video presentation are shown prior to the exercise to stress the importance of gentle surgical techniques, irrigation for cooling, and the use of surgical guides for the proper "prosthetically driven" implant placement. The hands-on exercise teaches the proper use of sequential drilling with an emphasis on precise management of the osteotomy site. Figure 1 illustrates the preparation and placement of two implants in an edentulous mandible model simulating the positions for an implant-assisted overdenture.

The prosthetic hands-on experience enables students to become familiar with a variety of implant restorative components. Students apply both direct and indirect impression-taking techniques to externally hexed implants in a plastic model. Several abutment choices are fitted on the model with explanations for the use of each type. Students practice taking impressions with the various impression copings and use implant analogs to pour working models of the simulated implant case. These prosthetic hands-on sessions are completed in conjunction with a treatment planning discussion of real patient cases. The faculty-to-student ratio for these sessions is 1-to-4 so that each student gets ample attention and has the opportunity to ask questions. Figure 2 illustrates the models used for the simulation of impressions and abut-





FIGURE 2A.

**FIGURES 2A-2E.**  
Laboratory hands-on  
experience in the restorative  
aspects of implant dentistry,  
including impression taking.



FIGURE 2B.

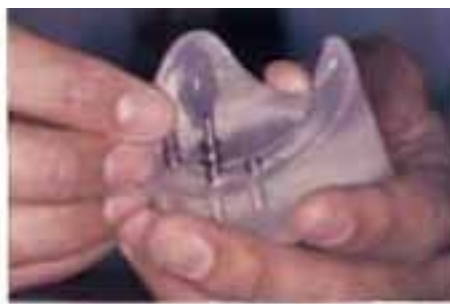

FIGURE 2C.



FIGURE 2D.

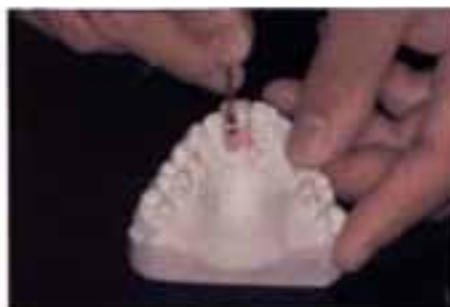

FIGURE 2E.

ment placement in a partially edentulous patient with an implant-supported fixed partial denture. The laboratory hands-on experience serves to familiarize dental students with the various components and procedures for implant dentistry in an environment that is conducive to learning without patients.

### Clinical Experience

In addition to the required didactic and laboratory aspects of the implant educational program, dental students are encouraged to treat patients with implants. The current curriculum does not require dental students to complete dental implant cases as part of their

graduation requirements, but they are given extra-credit incentives to seek and complete implant cases. Students are highly encouraged to do some simple implant cases as part of their restorative and removable prosthodontic experience. The types of implant cases that students are encouraged to do include implant-assisted overdentures, single-implant restorations, and simple multi-unit fixed restorations. The most common type of case students treat is the mandibular implant-assisted complete overdenture. Figure 3 demonstrates a typical dental student case with two mandibular implants used to retain a lower denture with a bar and Hader clip design.

Dental students have the opportunity to gain clinical experience with the surgical aspects of implant therapy by assisting and observing cases performed by postgraduate residents and faculty in the periodontal and oral and maxillofacial surgery programs. This experience allows students to observe implant surgery first hand and provides ample opportunity to ask questions. Extra credit is given for assisting, but it is not required as part of the dental implant experience for predoctoral students.

Perhaps more important than any actual experience with dental implant procedures, students are taught to think about dental implant treatment options as part of their diagnostic work-up and treatment planning for patients. All potential implant patients are taken through an advanced treatment planning session with several faculty representing each of the specialty sections. In preparation for the advanced treatment planning session, students take a complete history, examine the patient, prepare mounted study models, and request appropriate diagnostic radiographs. At the advanced treatment planning appointment, the dental student presents his or her case to the faculty. Each faculty member examines the patient and provides his or her respective specialist view on the problems that present. As an interactive learning

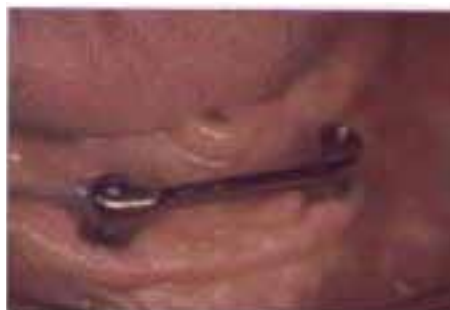

FIGURE 3A.

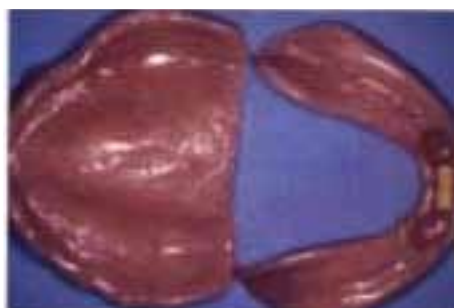

FIGURE 3B.

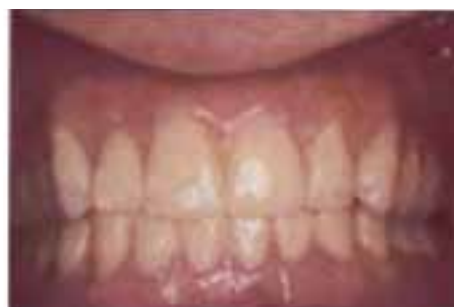

FIGURE 3C.

**FIGURES 3A-3C.** Clinical view of typical dental student implant case of an implant-assisted overdenture.

experience, the student is asked questions that stimulate thoughts about the treatment options. Ultimately, a treatment plan is developed for the patient with consideration for patient desires and all presenting problems, including finances. This interactive treatment-planning session allows faculty to teach patient-driven concepts to students on an individual basis and facilitates the development of ideal treatment plans for patients.

**Table 1. Behavioral Objectives for Predoctoral Dental Implantology Courses Taught at UCLA**

- 1. With respect to osseointegration, students will understand:**
  - a. The relationship between subperiosteal implants, and bone and the enveloping soft tissues;
  - b. The definition of osseointegration;
  - c. The unique biocompatibility of titanium;
  - d. The influence of temperature generated during bone preparation on osseointegration;
  - e. The importance of the delay of occlusal loading after placement of osseointegrated implants;
  - f. The relationship between oral mucosa and osseointegrated implants;
  - g. Bone repair mechanisms around implants;
  - h. Implant biomechanics;
  - i. Nature of the bone-implant interface; and
  - j. Nature of bone repair around implants with different surface morphology.
- 2. Students will become familiar with the prosthodontic and surgical components and the terminology used to describe them.**
- 3. With respect to the placement of osseointegrated implants, the students will understand:**
  - a. The means of patient selection with respect to hard and soft tissues in both edentulous and partially edentulous patients;
  - b. The medical contraindications;
  - c. The basic surgical procedures used in implant placement;
  - d. The basic surgical procedures used at second-stage surgery; and
  - e. The fabrication of templates used during implant placement.
- 4. When fabricating a fixed edentulous bridge, students will be familiar with:**
  - a. The management of the soft tissues surrounding the implants;
  - b. The methods of making impressions;
  - c. The means of fabricating record bases;
  - d. The method of making centric-relation records;
  - e. The method for determining cantilever length;
  - f. Determining the occlusal scheme; and
  - g. The procedure used during processing, delivery, and follow-up.
- 5. When fabricating implant-assisted or -supported overlay dentures, the student will be familiar with:**
  - a. The criteria for patient selection;
  - b. Design principles regarding implant-supported prostheses vs. implant-assisted prostheses;
  - c. The attachment employed and the rationale for choosing them;
  - d. Impression methods;
  - e. Means of making and fabricating record bases;
  - f. The methods used in making centric-relation records;
  - g. Developing an appropriate occlusal scheme; and
  - h. Methods employed in processing, delivery, and follow-up.
- 6. When constructing fixed partial dentures for partially edentulous patients, students will learn:**
  - a. The principles of patient selection and workup;
  - b. The use of surgical templates in implant placement;
  - c. The basic biomechanics and occlusal principals employed;
  - d. The clinical and laboratory steps used in fabrication of these restorations;
  - e. The rationale, design, and application of abutment selection; and
  - f. The indications of single-tooth implants in the anterior and posterior quadrants.
- 7. With regard to periodontal considerations, students will be familiar with:**
  - a. The importance of attached mucosa around implants;
  - b. Microbiology of the implant-gingiva interface;
  - c. The differences between the implant-bone interface and the periodontal ligament;
  - d. The methods of follow-up and maintenance; and
  - e. The treatment of peri-implantitis.

## Conclusion

Nearly three decades of evidence supports the use of osseointegrated dental implants, and it is now considered a predictable means of replacing missing teeth with long-term success. More and more patients are becoming educated about dental implants and seeking implant solutions. Dental school curriculums need to continue to evolve with implant dentistry to prepare dental students in the assessment, treatment planning, and restorative aspects of dental implant therapy. This article has outlined the current status of dental implant education at the predoctoral level taught at the UCLA School of Dentistry. Future directions for dental implant education at the predoctoral level will likely include interdisciplinary applications, more clinical experiences for dental students, and computer-simulation experience.

## Acknowledgments

The author would like to acknowledge and thank Dr. E.B. Kenney (professor and chair, UCLA Periodontics), Dr. John Beumer (professor and chair, UCLA Removable Prosthodontics), and Dr. Earl Freymiller (clinical associate professor and chair, UCLA Oral and Maxillofacial Surgery) for their review of and advice on the preparation of this manuscript.

## REFERENCES

1. Newman MG, The single-tooth implant as a standard of care -- editorial. *Int J Oral Maxillofac Implants* 14(5):621-2, 1999.
2. Dental Implants Nearly Triple Over 10-Year Period: ADA Survey, May, 1999. Available at: <http://www.ada.org>.
3. Ismail JYH, Predoctoral curriculum guidelines in implant dentistry. *Int J Oral Implant* 7(1):67-9, 1990.
4. Simons AM, Bell FA, et al, Undergraduate education in implant dentistry. *Implant Dent* 4(1):40-3, 1995.
5. The American Association of Dental Schools, Curriculum guidelines for predoctoral implant dentistry. *J Dent Educ* 55(11):751-3, 1991.
6. Landesman HM, Dental implants in the predoctoral curriculum. *J Calif Dent Assoc* 20(5):58-9, 1992.
7. Arbree NS, Chapman RJ, Implant education programs in North American dental schools. *J Dent Educ* 55(6):378-80, 1991.
8. Wilcox CW, Huebner GR, et al, Placement and restoration of implants by predoctoral students: the Creighton experience. *J Prosthodont* 6(1):61-5, 1997.
9. Weintraub AM, Seckinger R, et al, Predoctoral implant dentistry programs in U.S. dental schools. *J Prosthodont* 4(2):116-21, 1995.
10. Seckinger RJ, Weintraub AM, et al, The status of undergraduate implant education in dental schools outside the United States. *Implant Dent* 4(2):105-9, 1995.

**Table 2. Lecture Topics for Predoctoral Dental Implantology Courses Taught at UCLA**

- |  |  |
|--|--|
| <b>1. Historical perspective on implant dentistry</b>                          | e. Materials   |
| <b>2. Biologic basis of osseointegration</b>                                   | f. Hygiene access  |
| <b>3. Patient selection and treatment planning</b>                             | <b>9. Implant restorations in the esthetic zone</b>            |
| a. Edentulous  | a. Single-tooth restorations (bone and soft-tissue contours)   |
| b. Partially edentulous  | b. Multiple-tooth restorations (bone and soft tissue contours) |
| <b>4. Stage I surgery -- implant placement</b>                                 | c. Prosthodontic procedures                                    |
| a. Edentulous maxilla  | <b>10. Restoration of the edentulous maxilla</b>               |
| b. Edentulous mandible   | a. Implant-assisted overlay dentures                           |
| c. Partially edentulous  | b. Hader, ERA design   |
| d. Role of bone grafting   | c. Implant-supported overlay dentures                          |
| <b>5. Stage II surgery -- implant exposure</b>                                 | d. Milled bars   |
| a. Edentulous patients   | e. Porcelain-fused-to-metal fixed edentulous bridges           |
| b. Partially edentulous  | <b>11. Restoration of the edentulous mandible</b>              |
| c. Special soft-tissue considerations  | a. Implant-assisted overlay dentures                           |
| <b>6. Prosthodontic components and nomenclature</b>                            | b. Hader, ERA design   |
| a. Implant analogues   | c. Implant-supported overlay dentures                          |
| b. Impression copings  | d. Milled bars   |
| c. Abutments   | e. Porcelain-fused-to-metal fixed edentulous bridges           |
| d. Abutment analogues  | <b>12. Hands-on session (surgical)</b>                         |
| <b>7. Prosthodontic procedures</b>   | a. Sequential drilling procedure                               |
| a. UCLA abutments  | b. Osteotomy preparation                                       |
| b. Conical abutments   | c. Placement of threaded implants                              |
| c. Custom abutments  | <b>13. Hands-on session (prosthetic)</b>                       |
| <b>8. Restoration of the posterior quadrants/partially edentulous patients</b> | a. Impressions   |
| a. Provisionals  | b. Record bases  |
| b. Occlusal factors  | c. Records   |
| c. Cusp angles   | d. Implant-assisted bar designs                                |
| d. Width of occlusal table   |  |

11. Taylor TD, Dental students and dental implants: what's the right combination? -- editorial. *Int J Oral Maxillofac Implants* 16(1):19-20, 2001.

To request a printed copy of this article, please contact/ Perry R. Klokkevold, DDS, MS, UCLA School of Dentistry, Box 951668, Los Angeles, CA 90095-1668 or [pklok@ucla.edu](mailto:pklok@ucla.edu).

# Implant Dentistry Education for the Practicing Dentist

NICHOLAS CAPLANIS, DMD, MS; JOSEPH Y.K. KAN, DDS, MS; JAIME L. LOZADA, DDS

**ABSTRACT** Contemporary standards of care, as well as ethical and legal issues, dictate the incorporation of dental implants into the general dental practice. Given the simplicity of current implant systems, most general dentists already possess the clinical expertise necessary to provide basic implant restorative services to their patients. However, due to the restricted manner in which dental implant training was propagated in the United States, and perhaps due to its foreign origins, many competent dentists seem unaware of this greatly beneficial innovation. There are a variety of educational resources available for the uninitiated dentist to gain proficiency in basic implant dentistry. The ideal education in implant dentistry provides supervised hands-on clinical training on live patients as well as didactic instruction by recognized teachers in implant dentistry. Such education may or may not be devoid of commercial bias. This paper will describe many of these opportunities.

---

## AUTHORS

**Nicholas Caplanis, DMD, MS**, is an assistant professor in the Graduate Program in Implant Dentistry at Loma Linda University. He also maintains a private practice in Mission Viejo, Calif., that is limited to periodontics and implant dentistry.

**Joseph Y.K. Kan, DDS, MS**, is an associate professor in the Graduate Program in Implant Dentistry at Loma Linda.

**Jaime L. Lozada, DDS**, is a professor and the program director of the Graduate Program in Implant Dentistry at Loma Linda.

**T**he original, or Brånemark, concept of the “team approach” to implant dentistry promoted the notion that implants be placed exclusively by oral and maxillofacial surgeons and restored by prosthodontists. This model was understandably helpful in the past, given the complexity of the surgical and prosthodontic procedures of earlier implant systems. This exclusive and elitist orientation has impeded the pervasiveness of implant dentistry in general practice by restricting education to a privileged few. However, it did allow the science of implant dentistry to be extensively studied, documented, and perfected.<sup>1-4</sup> Regardless of its restricted availability and foreign origins, implant dentistry has flourished into what is today

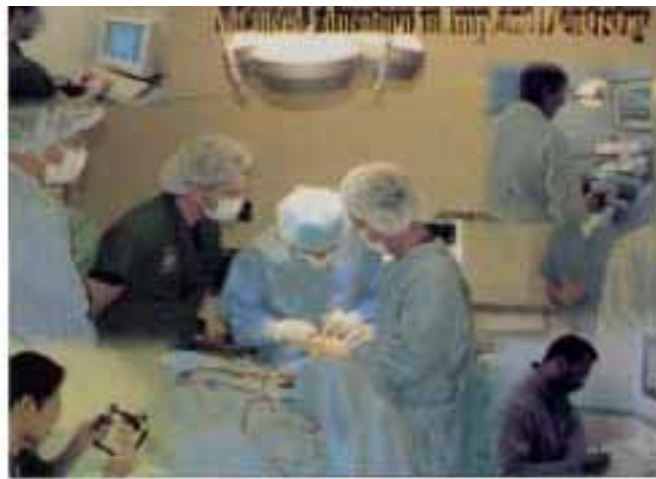an extremely predictable treatment for edentulism. Dental implants have become an appropriate part of the general as well as specialty dental practice.

Implant-supported dentistry has proven to be extraordinarily successful when compared with more-traditional methods of dental treatment. Long-term success rates of dental implants have been reported as high as 97 percent for single-tooth replacements and 94 percent for implant-supported fixed partial dentures.<sup>5-9</sup> Given long-term reported failure rates of 10 percent for fixed partial dentures,<sup>10</sup> 19 percent for resin bonded bridges,<sup>11</sup> 13 percent for hemisection and root amputation,<sup>12</sup> 15 percent for endodontic therapy,<sup>13</sup> and 34 percent for endodontic retreatment,<sup>14-15</sup> implant therapy may now be regarded as a more





**FIGURES 1.** The Loma Linda University School of Dentistry.



**FIGURES 2.** The Advanced Education Program in Implant Dentistry, Loma Linda University.

predictably successful method of restoring the dentition than the conventional means with which California dentists have been treating failing teeth.

Today, oral and maxillofacial surgeons and periodontists perform the vast majority of dental implant surgeries.<sup>16</sup> General dentists perform the majority of simple implant restorations while prosthodontists treat more-complex oral rehabilitation.<sup>17</sup> Periodontists have gained, at minimum, equal credibility as qualified implant surgeons during the past two decades. This should be of no surprise to the dental community given its unique background in comprehensive treatment planning, soft- and hard-tissue management, and meticulous attention to detail, as well as its vital role in oral health maintenance. With the simplicity of current implant systems,<sup>18</sup> particularly those with cemented final restorations, many general dentists are providing implant restorative treatment to their patients in a similar manner to traditional crowns. This article is directed to dentists of little or no experience in dental implantology who are desirous of providing this most beneficial of new technologies to their patients.

There are a variety of educational resources available from which California dentists can gain proficiency in basic

implant dentistry. These programs can be grouped into five basic categories:

- University programs;
- Private programs;
- National/international implant organizations;
- Manufacturer-sponsored educational programs; and
- Local study clubs.

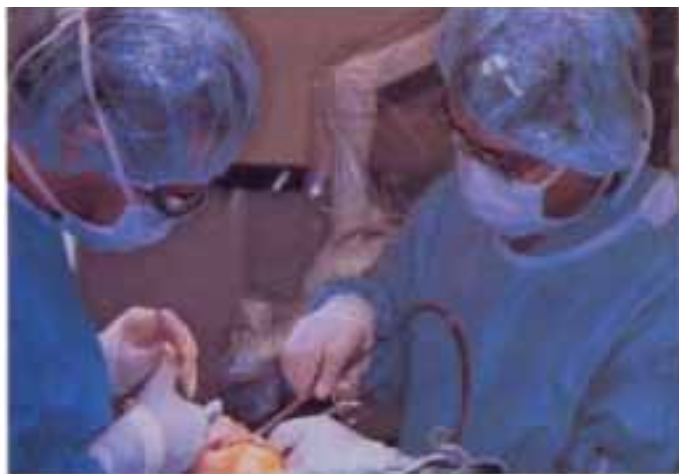The ideal education in implant dentistry will provide supervised hands-on clinical training on live patients as well as a broad didactic education by recognized teachers in implant dentistry, devoid of commercial bias. Unfortunately, there are very few programs that can offer all these ideals in one neat package. Therefore, dentists should consider pursuing several programs to achieve proficiency.

### University Programs

Loma Linda University

The Implant Dentistry Center at Loma Linda University provides the perfect example of the ideal educational resource center for implant dentistry in Southern California (**FIGURE 1**). The late Dr. Robert A. James established the residency program in 1976. The residency is a three-year full-time program admitting qualified general dentists and offering an extensive education in complex

oral diagnosis and treatment planning. Clinical training includes implant surgery, implant prosthodontics, and advanced surgical techniques including immediate implant placement, immediate implant loading, sinus grafting, autogenous bone harvesting techniques, ridge augmentation, nerve lateralization, and distraction osteogenesis.<sup>19</sup> Advanced postgraduate education in biomedical science, anatomy, pathology, radiology, statistics, and nutrition complement the didactic training, which also includes extensive literature reviews in current and historic implant dentistry, removable and fixed prosthodontics, periodontics, and occlusion. Advanced procedures are supervised by attending faculty members who are experts in implant dentistry and specialists in the fields of prosthodontics, periodontics, and oral and maxillofacial surgery as well as general dentists with extensive backgrounds in implantology. Residents also obtain extensive laboratory training and upon completion of the program have achieved competency in all facets of implant dentistry laboratory techniques. In addition to a Certificate in Implant Dentistry, the program confers a master's of science in implantology with the successful defense of a master's thesis in addition to completing the educational curriculum. Up to three residents per year



**FIGURES 3.** Implant dentistry residents, preceptors, and fellows perform surgery in state-of-the-art operating rooms in the Implant Dentistry Center at Loma Linda University.



**FIGURES 4.** Dr. Jaime Lozada lectures to the study club participants at Loma Linda University.

are admitted to this prestigious program, which attracts general dentists from around the world (**FIGURE 2**).

General dentists in private practice who are unable to return to full-time postgraduate study can enhance their backgrounds in implant dentistry by enrolling in the Preceptorship Program in the LLU Implant Dentistry Center. The Preceptorship Program can be tailored to fulfill a dentist's specific needs and schedule. Preceptors are exposed to both the didactic instruction as well as hand-on clinical training. The majority of clinical exposure is gained through assisting the implant dentistry residents with patient care. Given the extensive volume of procedures performed in the center, preceptors obtain a diverse and extensive clinical exposure to all facets of implant dentistry. Preceptors can attend the training one to five days per week for three months or longer depending on their needs and desires. Obviously, the greatest opportunity to maximize education, training, and experience will be through increased and consistent participation.

Through the Continuing Education Department, the LLU Implant Dentistry Center offers a program for general dentists and specialists called Clinical Experience in Implant Dentistry. After

proving minimum proficiency in implant dentistry, for example through the completion of the preceptorship program or a specialty residency, general dentists and specialists are permitted to bring their own implant patients to the center and render treatment under the direct supervision of attending staff. This allows the dentist to perfect his or her clinical skills. Patient care can be geared toward implant prosthodontics, implant surgery, or both (**FIGURE 3**).

The fellowship program for specialists is a one-year full-time program designed to complement the specialist's education in his or her respective discipline. Periodontists and oral and maxillofacial surgeons can enroll in the program to gain additional expertise in advanced surgical techniques related to implant dentistry. These include sinus lift and grafting, intra- and extraoral autogenous bone harvest, ridge augmentation, distraction osteogenesis, and the use of cutting edge as well as experimental materials such as platelet-rich plasma. Prosthodontists enrolled in the fellowship program perform only complex implant prosthodontics, including laboratory procedures.

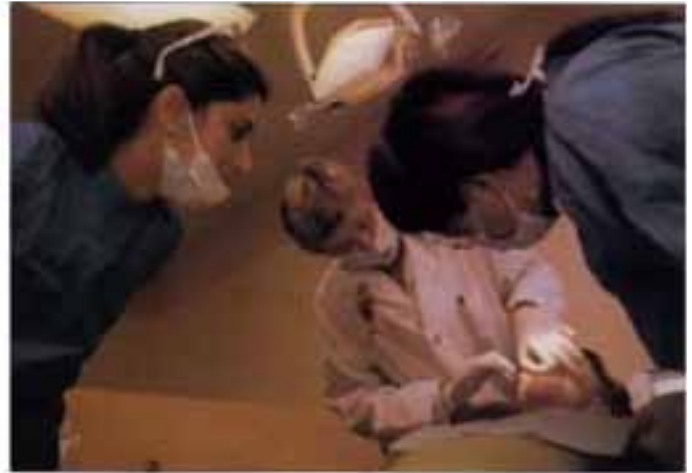Through the Department of Continuing Education, the LLU Implant Dentistry Center also offers a study club one

evening a week (usually on Wednesdays from 5 to 10 p.m.) that provides basic didactic education through lecture presentations and hands-on training in the laboratory. In addition, live surgery is performed and projected on a screen for study club participants, which leads to informal treatment discussions in a small-group setting (**FIGURE 4**). Loma Linda University also hosts an Implant Dentistry Symposium held approximately every five years with the world's premier experts in implant dentistry as invited speakers.

Recently, the Implant Dentistry Center has begun offering educational programs through the Internet. A number of courses are available. Topics include problem-based learning in implant dentistry and immediate loading. Live Web conferencing is available once a month with a lecture given by Dr. Jaime Lozada, professor and director of the Implant Dentistry Program. Topics range from the basics of diagnosis and treatment planning to advanced surgical and prosthetic concepts in implant dentistry. These Internet programs offer C.E. credit and allow dentists to attend a course or lecture from the comforts of their own homes and/or offices thereby eliminating travel and lodging expenses. These programs can be accessed through the Loma Linda University home page at <http://www.llu.edu>. The LLU Implant



**FIGURES 5.** Dr. George Perri reviews an implant case in the laboratory with a student of the implant dentistry mini-residency program at the University of California at Los Angeles.



**FIGURES 6.** Dr. Belinda Gregory-Head discusses the progress of an implant case with students at the University of the Pacific. Photo by Warren Hsu.

Dentistry Center can also provide further information on the residency, preceptor or fellowship programs, and the Department of Continuing Education can provide further information on the study club, implant symposium, or online courses.

### The University of California at Los Angeles

UCLA is in the process of establishing an implant dentistry teaching program, according to Dr. Sascha Jovanovic, research associate and director of preceptorship studies, and Dr. Earl Freymiller, chair of oral and maxillofacial surgery at UCLA. Although plans are not finalized, it is anticipated that a teaching program will be available soon for general dentists and specialists. The UCLA Dental and Maxillofacial Implant Center may be in operation by the end of this year.

At present, UCLA offers a mini-residency in implant dentistry directed by Dr. George Perri, lecturer in the Section of Advanced Prosthodontics, and Dr. Jovanovic. The program runs from October to May and meets one Monday per month from 8 a.m. to 5 p.m. The mini-residency incorporates lectures, hands-on laboratory instruction in implant prosthodontics, hands-on surgical experience on animal jaws, and live

surgery demonstrations to teach dentists the basics of implant surgery. The small group setting of approximately 20 to 25 residents per year is ideal for personalized instruction (**FIGURE 5**).

UCLA offers several preceptorship programs for general dentists. Preceptors are exposed to didactic instruction and observe implant surgery and implant restorative procedures performed by faculty and postgraduate students. The preceptorship programs are full-time programs of three or more months in duration. However, there is some flexibility in the number of days attended, depending on an individual's needs and desires. Once again, the more days spent in the program, the better the training.

UCLA also offers fellowship programs specifically designed for the periodontist, oral maxillofacial surgeon, or prosthodontist to gain advanced training in his or her specialty area. These fellowships are one-year full-time programs offered by the graduate prosthodontics and periodontics programs. Dr. Perri can provide further information on the mini-residency in Implant Dentistry and staff at the graduate programs in prosthodontics and periodontics have further information on the preceptorship and fellowship programs.

### University of the Pacific

The University of the Pacific offers a hands-on implant program through its Department of Continuing Education. According to Dr. Belinda Gregory-Head, prosthodontist and director of dental implants at the University of the Pacific, this program is designed for general dentists seeking to increase their level of expertise in implant dentistry. The course consists of two weekend sessions that combine lectures with clinical demonstration on live patients and hands-on laboratory training. The program follows several patients through treatment, from the initial consultation and examination, to implant surgery and final restoration. Each day of the course includes a lecture followed by hands-on laboratory training or live patient demonstration (**FIGURE 6**). The Department of Continuing Education at the University of the Pacific can provide more information.

### Private Educational Programs

Many well-known and respected practitioners in the field of implant dentistry promote their own educational programs. A university or an implant organization such as the American Academy of Implant Dentistry may

**Table 1. Private Education Programs Offering Instruction in Implant Surgery and Prosthodontics**

Course Description	Instructors/Sponsors	Location	Contact
Misch Implant Institute	Dr. Carl Misch	Beverly Hills, Mich.	(888) Misch99
Maxi-Course in Implant Dentistry	Dr. Norman Cranin, AAID	New York	(718) 240-6282
Maxi-Course in Implant Dentistry	Dr. Michael Billman, Dr. Edward Mills, Medical College of Georgia, AAID	Atlanta	(800) 221-6437
Maxi-Course in Implant Dentistry	Howard University, AAID	Washington, D.C.	(202) 806-0349

sponsor or endorse some of these programs. The main advantage of these programs is the personal exposure to the expert who sponsors the program as well as the informal, small-group learning environment. These programs may be somewhat biased, however, by that individual's training, experience, opinions, and interpretations of implant dentistry. For example, programs by implant surgeons may not offer implant prosthodontic training. As a general rule, the more respected and well-known the expert is, the better the program should be. Some of these programs offer hands-on training in addition to lecture presentations. Topics range from basic implant dentistry to advanced implant prosthodontics and implant surgery. Many of these programs are excellent ways to get started in implant dentistry as well as to expand proficiency. Programs offering both surgical and prosthetic education in implant dentistry are listed in **TABLE 1**.

### Implant Organizations

All dentists involved in implant dentistry should be a member of at least one national implant organization. The benefits to membership are overwhelming. These groups offer their members national and international meetings and symposia that are exclusively devoted to implant dentistry. They also provide educational programs for office staff members, hygienists, and laboratory technicians that encourage better communication to enhance implant dentistry success. In addition, members are eligible to receive the respective

organizations journals containing the latest information on implant dentistry in order to keep current (**TABLE 2**).

The American Academy of Implant Dentistry is the world's oldest professional organization dedicated to the advancement of implant dentistry. Established in 1951, the organization boasts more than 2,000 members across the globe. It is also the only organization that offers court-protected credentials in some states, including California. AAID maintains a peer-reviewed credentialing process that awards the statuses of associate fellow and fellow. AAID is also the sponsoring organization of the American Board of Oral Implantology/Implant Dentistry, which confers diplomate status to eligible implant dentists following successful completion of written and oral case defense examinations. AAID's membership includes nondentists, general dentists, periodontists, oral surgeons, and prosthodontists. The Academy's goal is to maintain the highest standards of practice and education by supporting research and maintaining a forum for the exchange of comprehensive implant knowledge. Membership to AAID includes a subscription to the Journal of Oral Implantology, which is published six times per year.

The Academy of Osseointegration is the fastest-growing professional organization dedicated to advancement of the art and science of osseointegration. It is arguably the premier organization at this time, as demonstrated by the quality of presentations and participation at its annual meetings. The first annual meeting

of AO was held in Chicago in April 1986. Since that time, membership has grown to more than 4,200 in 70 countries. Academy members share the common goal of moving the field of osseointegrated implants forward through clinical and evidence-based research and education. AO is the sponsoring organization for The International Journal of Oral & Maxillofacial Implants, the leading dental implant journal in the United States and possibly the world. Members of AO receive a subscription to the Journal, which is published six times per year.

The International Congress of Oral Implantologists is the world's largest oral implantology/implant dentistry organization. It has more than 50 component or affiliated societies representing more than 20,000 members in more than 70 countries. ICOI is dedicated to education, research, communication, membership recognition, and fraternity. The organization publishes a quarterly journal, Implant Dentistry, for its members with summary translations in Spanish, German, Japanese, and Portuguese. ICOI administers an international fellowship and diplomate recognition program for its members and sponsors a world implant congress annually.

### Manufacturer Programs

It is difficult to keep up with all the dental implant manufacturers and their educational programs. As new companies emerge, others file for bankruptcy, merge, or consolidate. The noteworthy dental implant manufacturers include Nobel Biocare (Brånemark and Steri-Oss implants), Straumann dental (ITI dental implant system), Sulzer/



**Table 2. National Implant Organizations**

Implant Organization	Instructors/Sponsors	Location	Contact
Journal	Dr. Carl Misch	Beverly Hills, Mich.	(888) Misch99
Next Annual Meeting	Dr. Norman Cranin, AAID	New York	(718) 240-6282
Contact	Dr. Michael Billman, Dr. Edward Mills, Medical College of Georgia, AAID	Atlanta	(800) 221-6437
American Academy of Implant Dentistry	Journal of Oral Implantology, published 6/year	50th Anniversary AAID Meeting, Nov 14-18, 2001, New Orleans	(877) 335-2243
Academy of Osseointegration International	Journal of Oral & Maxillofacial Implants, Published 6/year	17th Annual Meeting, March 13-16, 2002, Dallas	(800) 656-7736
International Congress of Oral Implantologists	Implant Dentistry, Published 4/year	ICOI Winter Symposium, April 11-14, 2002, San Juan, Puerto Rico	(973) 783-6300

Medica, Lifecore Biomedical, Friadent, 3I (Implant Innovations), and Astra. Manufacturer-sponsored educational programs can be extremely informative, especially when the company sponsors a nationally recognized speaker. The only disadvantage with these forums is the obvious commercial bias. Manufacturer who sponsor programs want participants to buy their products. Hence, it should be obvious that nothing negative will be said regarding their product lines. Therefore, one should attend educational programs from only those companies that have valid scientific research published in peer-reviewed journals to support the successful use of their implants and prosthetic components. These include companies such as Nobel Biocare and Straumann, which also sponsor annual symposia.

### Study Clubs

Local study clubs present an excellent venue for dentists to obtain knowledge in implant dentistry. Study clubs have recently become an increasingly popular method of continuing education. These clubs are commonly established by specialists to increase the quality and level of dental care in their areas and to facilitate communication between their referring offices, as well as to market their practices to their community. The benefits of a study club include small group size,

personable and informal presentations, and member influence on programming. These groups also offer excellent opportunities to meet and fraternize with colleagues in a local area. In addition, meetings are extremely convenient since travel, lodging, and extensive time away from the family and office is eliminated. Some study clubs offer hands-on laboratory training with the support of various dental implant manufacturers in addition to lectures and treatment-planning sessions.

Worthy of mention is the Seattle Study Club. The Seattle Study Club is a large network of local study clubs across the United States, Canada, and Australia with approximately 150 chapters and more than 4,000 members. Each club provides clinical treatment-planning sessions designed to increase total case management incorporating the use of dental implants. Meetings include problem-solving sessions, a network of specialists, and dedication to comprehensive treatment planning. National lecturers are showcased in small-group settings, allowing intimate sharing of state-of-the-art treatment for patients. Members of this unique network receive a quarterly interdisciplinary treatment-planning journal, as well newsletters, and are eligible to participate in the national meetings and symposia. There are approximately 17 chapters in California

(TABLE 3). For additional information on the Seattle Study Club network, one can visit their Web site at <http://www.seattlestudyclub.com>.

### Conclusion

Patients suffering from partial or complete edentulism must comprehend the benefits of implant dentistry. Dentists have moral, ethical, and legal obligations to educate partially and completely edentulous patients about the benefits of implant dentistry. Given extremely successful long-term treatment outcomes as well as the simplicity of current implant dentistry techniques, every dentist has the opportunity to provide basic implant dentistry services within his or her practice. There are a number of educational resources within as well as outside the universities for the dentist who wants to increase his or her level of expertise in implant dentistry. When treatment complexity exceeds a dentist's level of training and expertise, appropriate referral to an experienced implant surgeon and prosthodontist should be made.

**Table 3.** Seattle Study Club Chapters in California

Study Club	Location	Sponsoring Doctor	Telephone
Delta Study Club	Antioch	Dr. Sloan McDonald	(925) 778-2100
Sacramento River Dental Study Club	Folsom	Dr. Gordon Douglass	(916) 483-4964
Advanced Dental Seminars	Fremont	Drs. Dale Minkin and Tim Shahbazian	(510) 797-9100
Central Valley Dental Forum	Fresno	Dr. L. Anton Jonker	(559) 432-4911
South Valley Study Club	Gilroy	Dr. Joseph McMurray	(408) 847-6725
Inland Empire Forum for Dental Excellence West Valley Study Club Orange County Dental Academy	Loma Linda	Dr. Harvey Zalsman	(909) 558-6288
West Valley Study Club	Los Gatos	Dr. John Bond	(408) 356-3151
Orange County Dental Academy	Mission Viejo	Dr. Nicholas Caplanis	(949) 830-1322
Modesto Study Club	Modesto	Dr. Stan Baker	(209) 527-5050
Diablo Study Club	Oakland	Dr. Don Morris	(925) 939-2911
East Bay Study Club	Pinole	Dr. Ken Lyons	(510) 724-3922
Redding Advanced Dental Studies Forum	Redding	Dr. Russell Holpuch	(530) 241-3302
Northern California Dental Forum	Sacramento	Dr. Mark Zablotsky	(916) 641-1200
San Diego Advanced Study Group Central Coast Dental Study Club	San Diego	Drs. Cary Behle, Fred Hammond, Tim Smith	(619) 298-2200
Central Coast Dental Study Club	San Luis Obispo	Drs. Ron Mead, Bruce Whitcher	(805) 541-3220
Colleagues for Comprehensive Treatment	Santa Rosa	Dr. Paul Steigerwald	(707) 525-1228
Silicon Valley Study Group	Sunnyvale	Dr. Rik Vanooteghem	(408) 738-3423
Mt. Baldy Study Club	Upland	Dr. David Gilbert	(909) 982-8888

## REFERENCES

- Brånemark PI, Introduction to osseointegration. In: Brånemark PI, Zarb GA, Albrektsson T, Tissue Integrated Prostheses, Quintessence Publishing Co, Chicago, 1985.
- Brånemark PI, Hansson BO, et al, Osseointegrated implants in the edentulous jaw: Experience from a 10-year period. *Scand J Plast Reconstr Surg* 21:1-132, 1977.
- Adell R, Lekholm U, et al, A 15-year study of osseointegrated implants in the treatment of the edentulous jaw. *Int J Oral Surg* 10:387-414, 1981.
- Adell R, Ericksson B, et al, A long-term follow-up study of osseointegrated implants in the treatment of totally edentulous jaws. *Int J Oral Maxillofac Implants* 5:347-59, 1990.
- Henry PJ, Laney WR, et al, Osseointegrated implants for single-tooth replacement: a prospective 5 year multicenter study. *Int J Oral Maxillofac Implants* 11(4):450-5, 1996.
- van-Steenberghe D, Lekholm U, et al, Applicability of osseointegrated oral implants in the rehabilitation of partial edentulism: A retrospective multicenter study on 558 fixtures. *Int J Oral Maxillofac Implants* 5(3):272-81, 1990.
- Zarb GA, Schmitt A, The longitudinal clinical effectiveness of osseointegrated dental implants in posterior partially edentulous patients. *Int J Prosthodont* 6(2):189-96, 1993.
- Lindhe T, Gunne J, et al, A meta-analysis of implants in partial edentulism. *Clin Oral Implants Res* 9(2):80-90, 1998.
- Jemt T, Pettersson P, A 3-year follow-up study on single implant treatment. *J Dent* 21(4):203-8, 1993.
- Samama Y, Fixed bonded prosthodontics: a 10-year follow-up report. Part II. Clinical assessment. *Int J Periodontics Restorative Dent* 16(1):52-9, 1996.
- Corrente G, Vergnano L, et al, Resin-bonded fixed partial dentures and splints in periodontally compromised patients: a 10 year follow-up. *Int J Periodontics Restorative Dent* 20(6):628-36, 2000.
- Buhler H, Survival rates of hemisected teeth: an attempt to compare them with survival rates of alloplastic implants. *Int J Periodontics Restorative Dent* 14(6):536-43, 1994.
- Peak JD, The success of endodontic treatment in general dental practice: a retrospective clinical and radiographic study. *Prim Dent Care* 1(1):9-13, 1994.
- August DS, Long-term postsurgical results on teeth with periapical radiolucencies. *J Endod* 22(7):380-3, 1996.
- Allen RK, Newton CW, Brown CE Jr, A statistical analysis of surgical and nonsurgical endodontic retreatment cases. *J Endod* 15(6):261-6, 1989.
- Meraw SJ, Eckert SE, et al, Analysis of surgical referral patterns for endosseous dental implants. *Int J Oral Maxillofac Implants* 14(2):265-70, 1999.
- Brandt RL, Fitzpatrick BJ, et al, Continuing dental education in osseointegrated implants. A survey. *Aust Dent J* 45(4):285-8, 2000.
- Taylor TD, Prosthodontic considerations. *Clin Oral Impl Res* 11(suppl):101-7, 2000.
- Caplanis N, Kan J, Lozada JL, Osseointegration: contemporary concepts and treatment. *J Cal Dent Assoc* 25(12):843-51, 1997.

# Treatment Planning for Success: Wise Choices for Maxillary Single-Tooth Implants

BELINDA L. GREGORY-HEAD, BDS, MS; ALEX McDONALD PhD, DDS; AND EUGENE LABARRE DMD, MS

**ABSTRACT** The purpose of this article is to demonstrate to general practitioners who have no experience with dental implant treatment the esthetic limitations of such treatment. The criteria for wise case selection will be described so that esthetic excellence can be predictably achieved in general practice. A checklist of criteria will be provided as a treatment-planning tool to determine if a patient is likely to have an esthetically successful outcome.

---

## AUTHORS

**Belinda L. Gregory-Head, BDS, MS**, is an associate professor and director of dental implants at the University of the Pacific School of Dentistry.

**Alex McDonald, PhD, DDS**, is an associate professor and surgical coordinator at the Implant Clinic at UOP School of Dentistry.

**Eugene LaBarre, DMD, MS**, is an associate professor and chair of removable prosthodontics at UOP.

While the anterior implant patient may come into the office fixed on the notion of having an implant, further questioning often reveals that his or her chief concern is to have a missing tooth replaced with something that looks good, feels good, and works like a real tooth. The challenge of treatment planning is to fulfill these goals. If any of these criteria cannot be satisfied, then the treatment may be considered a failure.<sup>1-3</sup>

California dentists may very well face a greater challenge than most in satisfying the esthetic demands of their patients. Practitioners here must satisfy an extremely esthetically aware population. Unreasonable demands from patients and unrealistic promises by practitioners

can lead to unsatisfactory experiences for all parties. A clear understanding of the esthetic limitations of dental implants and the practitioner's own expertise in this area will reduce the risk of unforeseen problems.

Long-term data on the success of implant-supported single-tooth restorations in the anterior maxilla have been available since 1996<sup>4</sup> and have been corroborated in many more-recent studies.<sup>5-7</sup> Success rates of between 90 percent and 98 percent have been consistently reported. Early papers documented complications as being mainly mechanical in nature, including screw loosening, component fracture, and loss of integration. Studies seeking to define success in the anterior region have, until recently, focused on retention and

not on esthetic success.

The push for better function and esthetics has led to a growing appreciation of the biomechanical limitations of implants. Wider-diameter implants have been introduced.<sup>8,9</sup> This addition to the armamentarium along with better engineering of the components and screw-tightening systems<sup>10,11</sup> have brought us to a time when a dental implant can be a predictable and functional success. Advances in determining the ideal position of the implant and more-accurate surgical techniques have greatly enhanced esthetic outcomes.<sup>12</sup> These have been significant improvements, but they may never be enough to allow a dental implant to be the treatment of choice for all edentulous spaces in the anterior region.

### Functional Success With Esthetic Failure

The purpose of this article is to demonstrate that there are some esthetic limitations to dental implant treatment. It is aimed at practitioners with no experience with implant treatment. The criteria for wise case selection will be described so that esthetic excellence can be predictably achieved in general practice.

The following checklist of nine issues will be discussed. The checklist provides a treatment-planning tool to determine if a patient is likely to have an esthetically successful outcome:

- Assessment of patient expectations;
- Assessment of gingival display;
- Gingival thickness;
- Papilla presence or absence;
- Morphology of adjacent teeth (crown-to-root ratio);
- Size and shape of contact areas of adjacent teeth;
- Available bone height;
- Available bone width; and
- Studies appropriate for final decision making.

### Assessment of Patient Expectations

Patients' desires are often overlooked in guides to treatment planning, yet they may be the most important criterion assessed by the dentist. An experienced practitioner will be better able to judge a patient's esthetic demands, but in any case a clear understanding of the patient's wishes must be established before any treatment recommendations are made. It is possible to satisfy some demanding patients, but significant co-operation is required of them. It is critical that the patient be involved and educated as to the risks, esthetic or otherwise, that may be inherent in the treatment. The patient will be expected to maintain rigorous dental hygiene and deal with various provisional restorations as treatment progresses. For this reason, an emphasis on the team approach is recommended. The patient should become an integral member of the treatment team along with the laboratory technician, hygienist, and dentists.<sup>13,14</sup> Pretreatment intraoral photographs and carefully selected patient-education videos can help bring the patient's level of understanding up to that required for an esthetic case.<sup>15</sup> For a practitioner's first anterior implant case, it is recommended that he or she choose a co-operative patient with realistic expectations.

### Assessment of Gingival Display

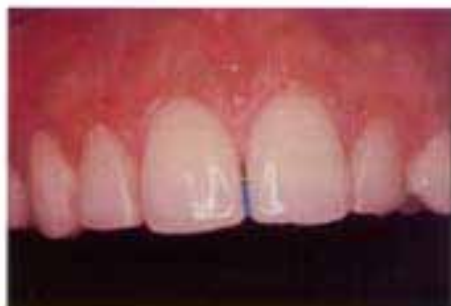After initial assessment of patient expectations, the evaluation of the smile line or gingival display will provide the best indicator as to the esthetic risk of the case. Excessive gingival display may be due to a number of factors, including vertical maxillary excess, short clinical crowns, and hypermobility of the upper lip.<sup>16</sup> Whatever the underlying etiology, it is important to evaluate the patient's ability to display gingiva.<sup>17,18</sup> Being asked to smile can result in a forced or half smile and may be misleading. It is recommended that the patient be asked to sneer or lift his or her upper lip as high as possible so the dentist can assess the situation. If a "gummy"

smile is presented, the patient should be fully informed of the difficulties ahead. Additional periodontal procedures such as crown lengthening of remaining maxillary dentition may be considered.<sup>19</sup> If the patient is unable to display gingival tissue, it is still important to discuss the risks, but it is also possible to reassure the patient that any gingival esthetic compromise will be hidden from view. The single most important factor for esthetic success in anterior implants is the smile line. It is highly recommended that the first few patients treated in a practice have a low lip line.

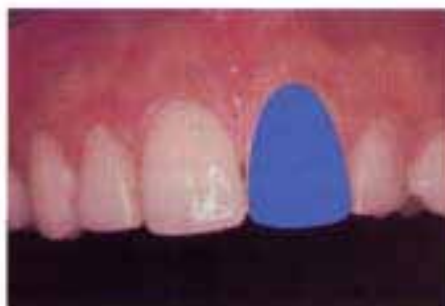### Gingival Form

The morphology of gingival tissue has been discussed extensively in the periodontal literature. It is relevant to esthetic success with anterior implants since gingival recession has been identified as a significant complication in these cases.<sup>20</sup> The forms of periodontium can be broadly divided into two distinct "biotypes," which have been correlated to specific tooth forms.<sup>21</sup> Thin, highly scalloped gingival tissues are associated with long, narrow, and tapered tooth forms. The second important biotype is the thick, flat more fibrous form associated with a shorter, wider, and squarer tooth shape. The two tissue types are associated with different responses to inflammatory stimuli. The thin, highly scalloped type tends to respond with marginal recession and loss of papillary height, while the thick, fibrous type tends to develop a chronic inflammatory response that may result in periodontal pocketing.<sup>22</sup> An ideal first implant patient would have an abundance of thick, flat, fibrous gingival tissue and therefore be more resistant to gingival recession around the restoration. This biotype also allows for the use of metal abutments with less chance of show-through at the gingival margin. This gingival form is also associated with a favorable square tooth form.

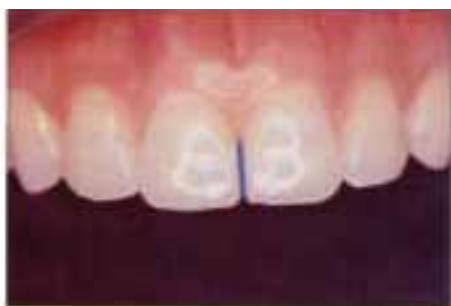



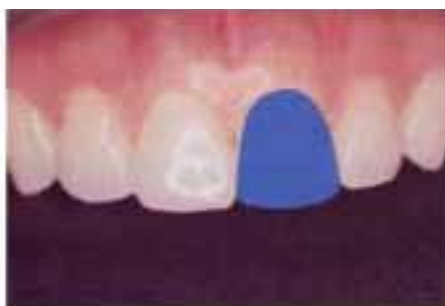**FIGURES 1.** The tapered crown form results in a short, incisally positioned contact area. A small interdental space is visible in this natural dentition.



**FIGURES 2.** The triangular crown form is associated with thin, highly scalloped gingival tissues.



**FIGURES 3.** Shorter, broader tooth forms have longer contact areas and better prognosis for fill of the interdental space.



**FIGURES 4.** The broader, squarer tooth form is associated with thicker, flatter gingival tissue.

### Papilla Presence or Absence

The existence of papillae filling the interdental spaces is a key indicator for future success. If the remaining dentition exhibits “black triangles” due to lack of complete fill of the spaces, then the risk of similar incomplete fill around the implant restoration is high. “Black triangles” may be pre-existing for a number of reasons, including gingival recession, highly tapered triangular tooth form, and previous periodontal surgery. The problem is difficult to resolve, and the patient should be educated as to the esthetic risks involved. Attempts have been made to classify loss of papillae and provide prognostic indicators.<sup>23</sup> Surgical techniques aimed at regenerating lost papillae have been developed.<sup>24,25</sup> Such regeneration remains challenging, and it may be unwise for a general dentist who is new to implants to treatment plan a first

case anticipating the need for additional periodontal plastic procedures.

The position of the osseous crest is a critical indicator for potential loss of papillae after a surgical intervention such as extraction or implant placement.<sup>26</sup> The greater the distance from the free gingival margin to the osseous crest, the greater the esthetic risk. A sounding depth of greater than 3 mm at the midfacial aspect or 4 mm at the interproximal position would indicate an esthetic risk.<sup>27</sup> An ideal patient would therefore have excellent periodontal health and a high, flat bone profile.

### Adjacent Tooth Morphology

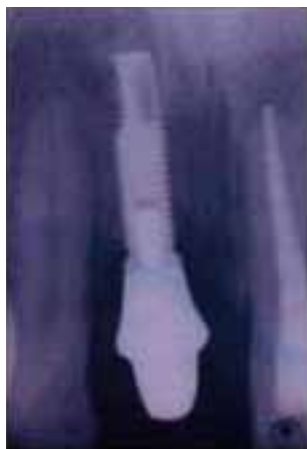Complete papillary fill of the interdental space after implant restoration is also closely related to tooth form, particularly the position and shape of the contact areas.

It has been determined that if the

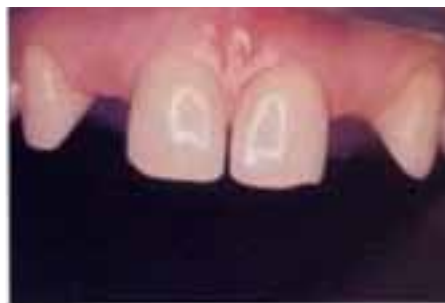apical limit of the contact area is 5 mm or less from the osseous crest, then a papilla will be present almost 100 percent of the time in the natural dentition. An additional 1 mm distance drops the likelihood of a papilla being present to only 56 percent.<sup>28</sup> While the position of the osseous crest may be difficult to adjust, the position of the contact areas may be changed by the restorative dentist. A careful evaluation of the patient's natural tooth morphology should be made. Long, narrow tapered teeth tend to have short incisally positioned contact areas (**FIGURE 1**) likely to be further from the osseous crest and therefore likely to have incomplete fill of the interdental space. The triangular shape (**FIGURE 2**) is also associated with thinner highly scalloped gingival tissue that tends to recede. More predictable anterior esthetics will be gained with patients who have broader tooth forms and longer, more cervically positioned contact areas (**Figures 3 and 4**). Pretreatment photographs are an essential tool for evaluation of tooth shape and educating the patient as to potential risks.

Crown shape is related to root form. Ironically, unfavorable clinical crowns with a triangular morphology taper into a narrow neck and narrow, tapered root form with more interdental bone. This would be a favorable variable providing for more bone between the titanium implant and the adjacent natural roots. This makes placement easier and reduces the risk of root proximity issues. It is generally believed that at least 1.5 mm of healthy bone should exist between the dental implant and the adjacent root surface. Recent work on treatment-planning criteria for multiple implant restorations has suggested that at least 3 mm should separate neighboring implants to reduce interimplant crestal bone loss and hence preserve vital osseous support for the interimplant papillae.<sup>29</sup>

Adjacent tooth morphology has an additional effect on treatment planning a single dental implant. The length of



**FIGURES 5.** Ideal vertical placement of implant 3 mm apical to the cemento-enamel junction of adjacent teeth allows for appropriate emergence of crown form (Nobel Biocare implant with a custom abutment).



**FIGURES 6.** Example of a patient with excellent bone height and favorable tooth form, note long contact areas.

the adjacent clinical crowns will have biomechanical consequences for the implant restoration regardless of tooth shape. Neighboring long clinical crowns must be replicated in the final restoration and may result in a long lever arm acting on the dental implant itself. Unless excellent bone height is available to facilitate the placement of a long implant, an unfavorable crown-to-implant ratio will result for most implant systems available.

In relation to adjacent tooth morphology, the ideal implant patient would have short, wide clinical crowns with long contact areas and existing papillae.

### Available Bone Height

Occlusal forces act obliquely on anterior teeth. Likewise, an anterior implant restoration will be loaded nonaxially. Longer implants resist nonaxial loading better and have been associated with higher success rates. Implants of 11 mm or longer have proven to be successful in the anterior maxilla.<sup>30</sup> If the replacement being proposed is for a single tooth only, there is often adequate remaining bone height to facilitate fixture placement. However, the osseous crest may be positioned apical to ideal. Ideal placement of a dental implant will result in the top of the fixture being placed

2-4 mm apical to the cemento-enamel junction of the adjacent teeth (**FIGURE 5**). The exact ideal distance will be modified by the diameter of the chosen implant, the desired emergence profile of the final crown, and the tissue biotype. If the top of the implant closely replicates the diameter of the missing tooth, the placement will be more coronal. If the top of the implant is narrower, then placement will be deeper to facilitate harmonious broadening of the crown form as it emerges from the tissue. Implant placement in a patient with thin, highly scalloped tissue would also be deeper to accommodate the tendency to recede and to reduce the risk of metal show-through.

Available bone height can be evaluated with periapical radiographs and clinical examination. The ideal patient would have adequate height to house a long implant (13 mm or more) with the crest of the residual ridge 2 mm below the cemento-enamel junction of the adjacent teeth (**FIGURE 6**).

### Available Bone Width

Successful placement of dental implants depends on adequate osseous housing in all dimensions. At least 1.5 mm of healthy bone is required between the implant and neighboring root surfaces and the “standard” implant from most

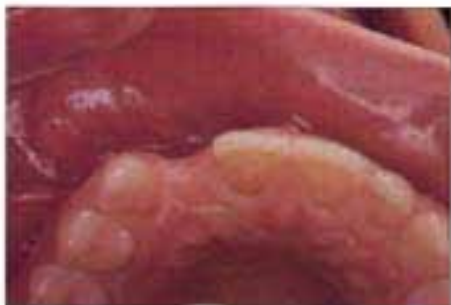manufacturers approximates 4 mm in diameter. Therefore the minimum mesiodistal space that can accommodate an implant between two teeth is 7 mm. Replacement of a central incisor or cuspid would not usually present a problem in this dimension, but loss of a small lateral incisor could present risk. In such a case, a narrower implant may be considered or orthodontic correction carried out.

The implant must also be fully encased in bone in the labiolingual dimension. Again, a minimum of 7 mm is required for a standard diameter implant. It is this requirement that presents the most common complication of treatment planning for the anterior maxilla. The labial plate of cortical bone is often missing and remodeled before implant treatment planning begins. This may be due to previous periodontal or periapical infection, traumatic loss, or loss during extraction. Even if an atraumatic extraction technique is employed, the labial plate will inevitably remodel and become positioned lingually within three to six months. A distinct labial concavity will be evident when the site is viewed from the occlusal aspect (Figures 7 and 8).

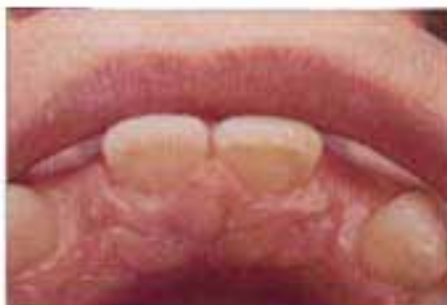A significant labial defect that would result in the facial aspect of the implant being located entirely outside the osseous structures should be considered for hard tissue augmentation prior to implant placement. A less-significant defect may be accommodated by slightly deeper and more lingual placement of the fixture to allow for good osseous contact while maintaining the proper emergence profile (**FIGURE 9**).

### Determining Available Bone

Assessment of available bone in the mesiodistal and buccolingual dimensions can be achieved with a thorough clinical examination, or measuring directly from study casts. Anesthesia and “sounding” of the osseous structures is also a useful technique. The most accurate diagnostic aid is the CT scan (**FIGURE 10**). Unlike Panorex films, where measurements have



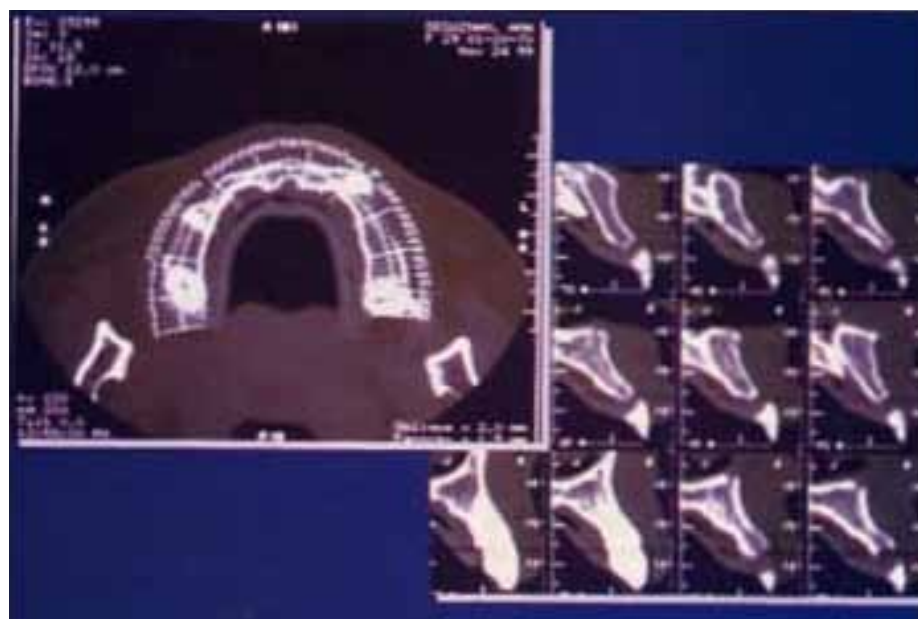
**FIGURES 7.** Occlusal view of potential implant site showing significant labial concavity. Hard tissue onlay grafting will idealize the site prior to implant placement.



**FIGURES 8.** The same patient as Figure 6. Excellent ridge width in both edentulous lateral incisor sites.



**FIGURES 9.** Graphic illustration of placement lingually and apically from ideal due to loss of labial cortex. This technique can be used to avoid grafting but should be employed with caution since significant deviation from ideal position can result in unfavorable cantilevers and maintenance problems (Illustration by Annette Kramer).



**FIGURES 10.** CT scans can significantly increase accuracy in determining available bone for fixture placement (Image made with GE Lightspeed Plus, Advanced Imaging Center, Sacramento, Calif.).

to be corrected for varying magnification, the CT film can be measured directly and is accurate to within 0.1 mm. Dental CT scans have become economic (as low as \$275 to \$350 per arch). They should be considered if there is a question as to whether bone augmentation will be required.

### Completing the Case

After thorough treatment planning and ideal fixture placement, there is still opportunity for esthetic excellence or mediocrity in the restoration phase.

Several months of provisionalization allows for maturation of the gingival tissues to an appropriate (noncylindrical) emergence profile. The tooth form generated through excellent provisionalization must be carried through to the final restoration so that crown and papilla form is maintained (Figures 11 through 13).

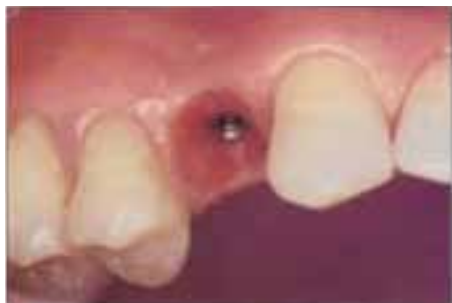### Conclusion

Restoring dental implants in the esthetic zone can be fun if wise choices are made. If the factors discussed above

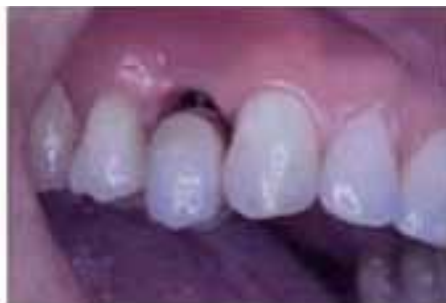are carefully considered, patients who present significant esthetic risks will be screened out and patients with predictably good prognoses will be taken on. While much emphasis has been placed on the anatomic features of the ideal first patient (**FIGURE 14**) possibly more important is the patient's desire to cooperate with the team and have realistic expectations. A thorough understanding of the esthetic limitations of dental implants by all members of the team will result in a rewarding and satisfying experience.

### REFERENCES

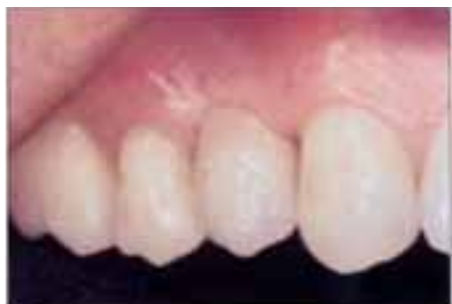1. Weisgold AS, Arnoux JP, Lu J, Single-tooth anterior implant: a word of caution. Part 1. *J Esthet Dent* 9(5):225-33, 1997.
2. Garber D, The esthetic dental implant: letting restoration be the guide. *J Am Dent Assoc* 126(3):319-25, 1995.
3. Watson CJ, Tinsley, Sharma S, Implant complications and failures: the single-tooth restoration. *Dent Update* 27(1):35-8, 2000.
4. Walther W, Klemke J, et al, Implant-supported single-tooth replacements: risk of implant and prosthesis failure. *J Oral Implantol* 22(3-4):236-9, 1996.
5. Henry PJ, Laney WR, et al, Osseointegrated implants for single-tooth replacement: a prospective 5-year multicenter study. *Int J Oral Maxillofac Implants* 11(4):450-5, 1996.
6. Naert I, Koutsikakis G, et al, Biologic outcome of single-tooth implant restorations as tooth replacements: a long-term follow-up study. *Clin Implant Dent Relat Res* 2(4):209-18, 2000.
7. Scholander S, A retrospective evaluation of 259 single-tooth replacements by the use of Brånemark implants. *Int J Prosthodont* 12(6):483-91, 1999.
8. Boggan RS, Strong JT, et al, Influence of hex geometry and prosthetic table width on static and fatigue strength of dental implants. *J Prosthet Dent* 82(4):436-40, 1999.
9. Ivanoff CJ, Sennerby L, et al, Influence of implant diameters on the integration of screw implants. An experimental study in rabbits. *Int J Oral and Maxillofac Surg* 26(2):141-8, 1997.
10. Lang LA, May KB, Wang RF, The effect of the use of a counter-torque device on the abutment-implant interface. *J Prosthet Dent* 81(4):411-7, 1999.



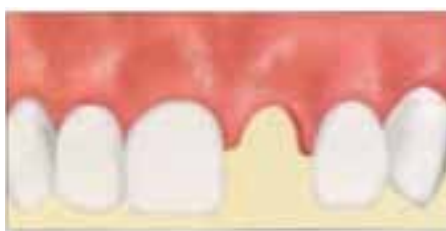**FIGURES 11.** Ideal placement and provisionalization of implant #5 site results in excellent emergence profile.



**FIGURES 12.** Morphology of provisional is accurately duplicated in final restoration.



**FIGURES 13.** Final restoration in place.



**FIGURES 14.** Key anatomic features of an ideal anterior implant patient: low smile line; abundance of attached keratinized tissue (thick, flat biotype); papillae preserved after extraction; wide, square-shaped teeth with long contact areas; and excellent bone height and width (Illustration by Annette Kramer).

edu.

11. Schulte JK, Coffey J, Comparison of screw retention of nine abutment systems: a pilot study. *Implant Dent* 6(1):28-31, 1997.
12. Davarpanah M, Martinez H, Tecucianu JF, Apical-coronal implant position: recent surgical proposals. Technical note. *Int J Oral Maxillofac Implants* 15(6):865-72, 2000.
13. Narcisi EM, Culp L, Diagnosis and treatment planning for ceramic restorations. *Dent Clin North Am* 45(1):127-42, 2001.
14. Hess D, Buser D, et al, Esthetic single-tooth replacement with implants: a team approach. *Quintessence Int* 29(2):77-86, 1998.
15. Dunn JR, Hutson B, Levato CM, Photographic imaging for esthetic restorative dentistry. *Compend Contin Educ Dent* 20(8):766-8, 1999.
16. Robbins JW, Differential diagnosis and treatment of excess gingival display. *Pract Periodontics Aesthet Dent* 11(2):265-72, 1999.
17. Morley J, Eubank J, Macroesthetic elements of smile design. *J Am Dent Assoc* 132(1):39-45, 2001.
18. Paul SJ, Smile analysis and face-bow transfer: enhancing aesthetic restorative treatment. *Pract Proced Aesthet Dent* 13(3):217-22, 2001.
19. Levine RA, McGuire M, the diagnosis and treatment of the gummy smile. *Compend Contin Educ Dent* 18(8):757-62, 1997.
20. Goodacre CJ, Kan JY, Rungcharassaeng K, Clinical complications of osseointegrated implants. *J Prosthet Dent* 81(5):537-52, 1999.
21. Siebert J, Lindhe J, Esthetics and periodontal therapy. In Lindhe J, ed, *Textbook of Clinical Periodontology*, 2nd ed. Munksgaard, Copenhagen, 1989, Chap 19.
22. Olsson M, Lindhe J, Periodontal characteristics in

- individuals with varying forms of upper central incisors. *J Clin Periodontol* 18:78-82, 1991.
23. Nordland WP, Tarnow DP, A classification system for loss of papillary height. *J Periodontol* 69:1124-26, 1998.
24. Blatz MB, Hurdeler MB, Strub JR, Reconstruction of the lost interproximal papilla-presentation of surgical and nonsurgical approaches. *Int J Periodontics Restorative Dent* 19(4):395-406, 1999.
25. Salama H, Salama M, et al, Developing optimal peri-implant papillae within the esthetic zone: guided soft tissue augmentation. *J Esthet Dent* 7(3):125-9, 1995.
26. Kois JC, Predictable single tooth peri-implant esthetics: Five diagnostic keys. *Comp Contin Educ Dent* 22(3):199-206, 2001.
27. Kois JC, Altering gingival levels: the restorative connection part 1: biologic variables. *J Esthet Dent* 6:3-9, 1994.
28. Tarnow DP, Magner AW, Fletcher P, The effect of the distance from the contact point to the crest of bone on the presence or absence of the interproximal dental papilla. *J Periodontol* 63:995-6, 1992.
29. Tarnow DP, Cho SC, Wallace SS, The effect of inter-implant distance on the height of inter-implant bone crest. *J Periodontol* 71:546-9, 2000.
30. Goodacre CJ, Kan JY, Rungcharassaeng K, Clinical complications of osseointegrated implants. *J Prosthet Dent* 81(5):537-52, 1999.

To request a printed copy of this article, please contact/  
Belinda L. Gregory-Head, BDS, MS, UOP School of Dentistry,  
2155 Webster St., San Francisco, CA 94115, or bhead@sfsu.edu.



# Implant-Borne Single Tooth Replacement — An Illustration and Rationale

RICHARD K. ROUNSAVELLE, DDS

**ABSTRACT** This article demonstrates a method for the replacement of a single missing tooth with a dental implant system that can simply and easily be incorporated into a general practice. Recent innovations in implant abutment design and impression procedures have resulted in a technique that is very similar to traditional crown and bridge procedures. This article describes a step-by-step protocol for the restoration of a single missing tooth with an implant-borne, cemented crown.

---

## AUTHOR

**Richard K. Rounsavelle, DDS,** is a general dentist in Torrance, Calif.

**T**he replacement of diseased natural tooth substance with an optimal material is the essence of restorative dentistry. The restoration should be durable, be reasonably esthetic, and require minimally invasive procedures. Dental schools have taught the art and science of partial coverage cast gold restorations (Figures 1a and b) with the ultimate intent of conserving healthy tooth structure. The implant-borne single tooth replacement, like the partial gold casting, embodies the principle of tooth conservation which all dentists should espouse in serving their patients.

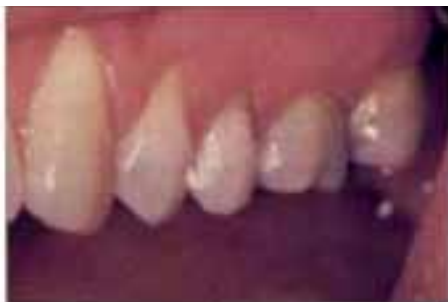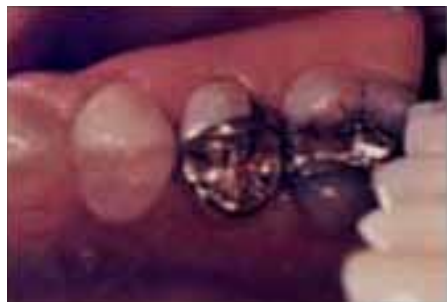With an implant, the adjacent teeth, when healthy, need no longer be prepared solely for the purpose of providing support for a fixed bridge. On occasion,

every dentist has seen a formerly healthy tooth progress through a series of destructive events following restoration for crown retainers. This scenario is now avoidable.

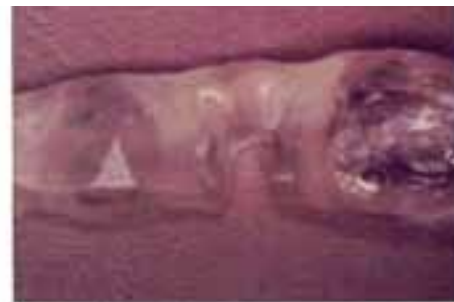The ITI Solid Abutment System, described herein, heralded a breakthrough in simplifying the restorative process. Dental implants, formerly the province of a few specialists, now may be routinely accomplished by all general dentists.

## Treatment Planning

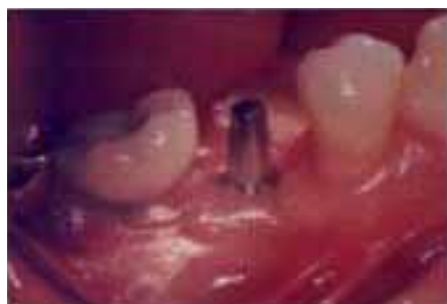A team approach is best for treating implant patients. The general practitioner should refer his or her patients to a qualified specialist for surgical placement of implant fixtures, along with bone grafting and soft-tissue manipulation where indicated. In consultation



**FIGURES 1A AND B.** Partial gold coverage can be both conservative and esthetic.



**FIGURES 2.** Implant positioning guide for single tooth with lingual acrylic of replacement tooth removed.



**FIGURES 3.** Standard solid abutment torqued into ITI implant fixture.



**FIGURES 4.** Standard abutment impression cap.



**FIGURES 5.** Impression cap in place over abutment.

with a surgeon, the G.P. will share the responsibility for evaluating such factors as medical history, availability of supporting bone, soft tissue contours, occlusion, and cosmetics. The use of mounted study casts with a diagnostic wax-up of the replacement tooth greatly facilitates the shared evaluation of a given case. In addition to the wax-up, the G.P. may also provide guidance as to implant location by using a surgical stent or template for surgical implant positioning. This appliance may take many forms, but for single tooth replacement, a tooth-borne device is usually most appropriate. This device may transfer from the diagnostic wax-up the facial or lingual anatomy of the proposed final restoration, depending on the surgeon's preference. This transfer conveys to the surgeon the G.P.'s intent for the final restoration at the time of implant placement (**FIGURE 2**).

### Standard Abutment-Final Impressions

After the implant has "osseointegrated," or united to the surrounding bone, the patient is ready for restoration. The technique described involves a solid abutment, which is analogous to a tooth preparation (**FIGURE 3**); an impression cap and cylinder; and a laboratory replica of the abutment.

First, one places the white impression cap over the implant collar (**FIGURE 4**). This impression coping eliminates the need for tissue retraction and, therefore, local anesthesia. To be certain that complete seating has occurred, one should rotate the cap while viewing it from an occlusal direction. If the cap rotates without dislodging and the abutment appears to be centered, it is seated properly. Seating requires firm pressure and, when achieved, will result in a palpable "click" (**FIGURE 5**).

Next, the positioning cylinder (**FIGURE 6**) is placed into the impression cap. The trick here is to view the abutment again from an occlusal perspective to orient the flat section of the abutment and match it to the corresponding flat area of the positioning cylinder. It, too, will seat with firm pressure and must go completely into place (**FIGURE 7**).

One is then ready to take the impression. The best impression material to use is the most rigid: vinyl polysiloxane. Polyether and polysulfide also work well. Nonrigid materials, such as hydrocolloid, are contraindicated. One should be sure to block out any large undercuts created by teeth within the arch. Syringe hydrocolloid works well for blocking.

One should inject and place the tray as for any other crown impression. The cap and cylinder assembly should lift off the

abutment and be embedded within the impression (**FIGURE 8**).

The actual "prep" or abutment that the lab will use is called an analog or abutment replica (**FIGURE 9**). This is a small metal component that one must next mate to the impression component assembly. Again, one carefully matches the flat side of the analog with the flat side of the positioning cylinder and firmly

pushes it into place. If the analog does not snap into the impression cap, it is not seated completely (Figures 10 and 11).

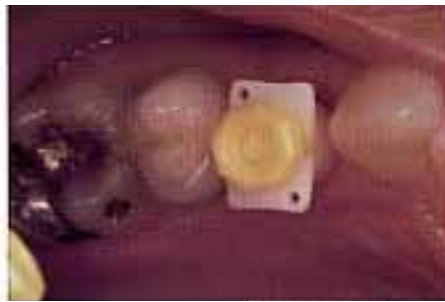The impression is now ready for the lab. The lab will use a prefabricated plastic coping (**FIGURE 12**) to act as a base onto which wax is added to create the appropriate contour from which the crown is completed via conventional procedures.

### Temporary Crowns

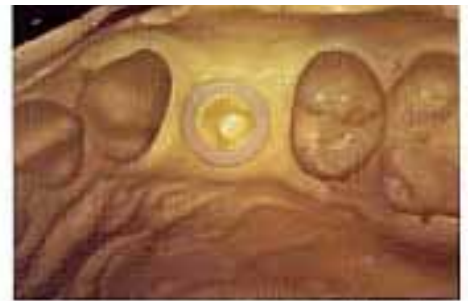The options for placing a temporary crown depend upon the patient and the situation. A very simple approach is to use temporary cement to place a temporary protective cap available from the manufacturer (**FIGURE 13**). If the patient requires a more esthetic temporary crown, one may modify a plastic coping (the same one used in the laboratory phase)



**FIGURES 6.** Positioning cylinder for 5.5 mm solid abutment.



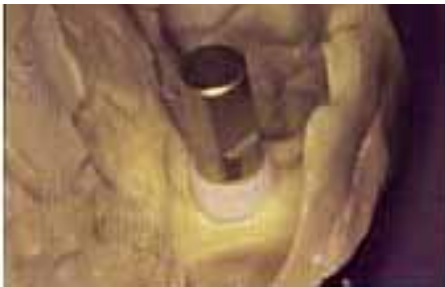**FIGURES 7.** Positioning cylinder seated into impression cap.



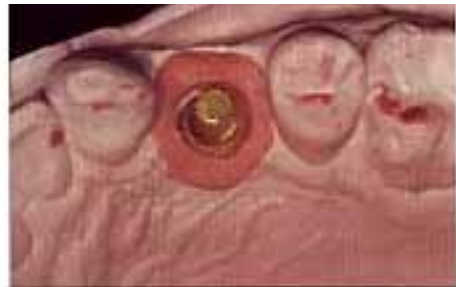**FIGURES 8.** Impression cap/positioning cylinder imbedded within final impression.



**FIGURES 9.** Analog of a 5.5 mm solid abutment.



**FIGURES 10.** Analog seated into place in the impression cap/positioning cylinder assembly.



**FIGURES 11.** Final laboratory cast for crown fabrication.



**FIGURES 12.** Plastic coping for laboratory procedures (seated on analog).



**FIGURES 13.** Protective cap for temporization.



**FIGURES 14.** Plastic coping shortened and air abraded for inclusion in an acrylic provisional crown.

and incorporate the coping with acrylic resin into a crown form or clear plastic shell. This latter technique requires more chair time but is greatly appreciated by a patient who needs a tooth and has been without a fixed replacement. The procedure for this is as follows:

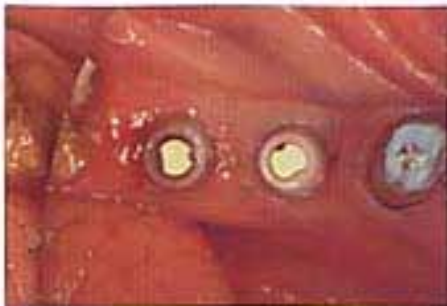First, one shortens, scores, and air abrades the coping in the lab. Then one seats the coping until it snaps into place over the abutment (**FIGURE 15**). The crown form or clear matrix filled with acrylic is allowed to set completely on the coping (Figures 16a and b). It is very important to remove all acrylic from any undercuts prior to the final set. The coping “over-crown” is then taken to the lab; and,

very carefully, using the salt and pepper technique, one fills in the spaces between the acrylic and the margin of the coping (**FIGURE 17**). Once this is achieved, one may finish and polish to create the final crown contour and emergence profile. The final provisional must snap into place on the abutment to prevent soft tissue encroachment over the implant collar. To achieve this fit, one must remove a small amount of acrylic from the occlusal aspect of the provisional internally with a straight fissure lab bur. One then cements with temporary cement and thoroughly removes any gingival excess, as it commonly lodges just below the implant collar.

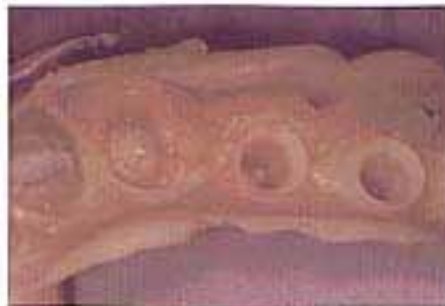### Delivery of Final Restoration

The beauty of this implant system is its simplicity and similarity to conventional crown and bridge procedures: One tries the crown in place, adjusts contacts and occlusion, and cements. The following are helpful hints on adjusting these crowns:

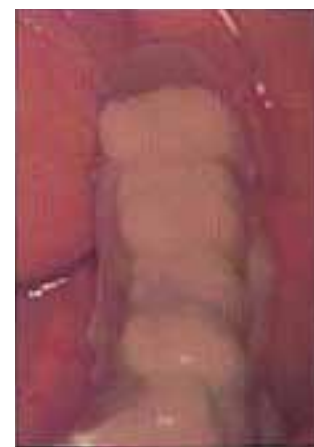- One should be very careful in adjusting contacts because there is no periodontal ligament “cushion” on the implant to absorb small discrepancies. If the contact is excessive, the crown will not seat completely.
- One should relieve all eccentric occlusal contacts—especially those that occupy the extreme periphery of the occlusal table.



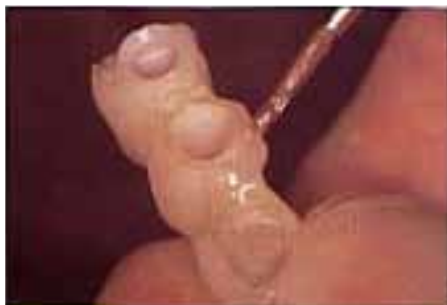**FIGURES 15.** Modified copings seated on solid abutment.



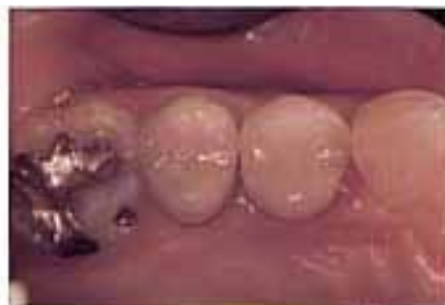**FIGURES 16A.** Acrylic filled shell seated over modified copings.



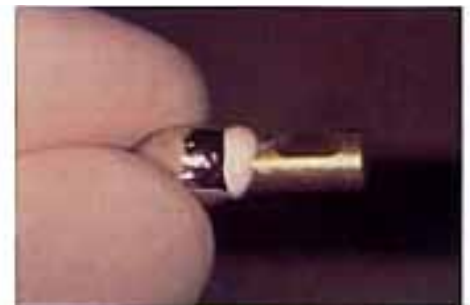**FIGURES 16B.** Shell with acrylic and copings incorporated.



**FIGURES 17.** Addition of acrylic to establish contour and marginal adaptation.

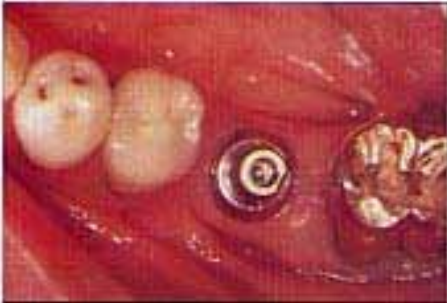

**FIGURES 18.** Final first premolar restoration cemented to place.

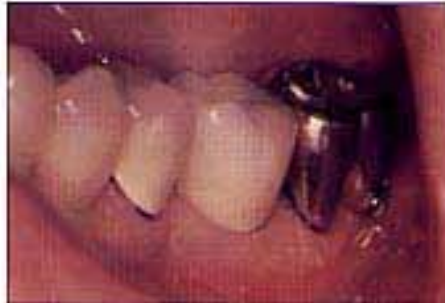

**FIGURES 19.** Partial displacement of excess cement using laboratory analog prior to cementation.

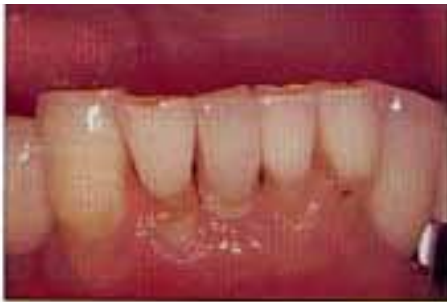



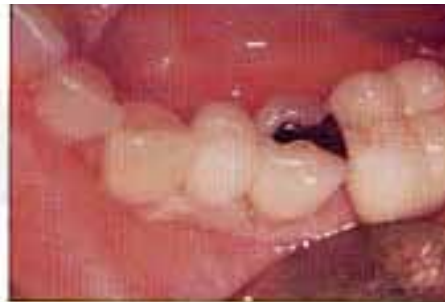**FIGURES 20.** ITI Wide Neck abutment.



**FIGURES 21.** Final restoration showing a more favorable emergence contour achievable with wider implant (Tooth #31 was periodontally compromised).



**FIGURES 22.**



**FIGURES 23.**

**FIGURES 22 AND 23.** Very narrow restorations on the ITI Narrow Neck abutments.

- One should make certain that the centric contacts are as close to the long axis of the implant fixture as possible and are light. One should have the patient firmly clench to register contact with a mylar shim stock.
- If temporary cement is to be used, one should be aware that implant-borne crowns tend to dislodge very abruptly and unpredictably when luted with temporary cement (**FIGURE 18**).
- It is always a good practice to place an impression cap onto the abutment whenever one is working with the final crown away from the chair. This procedure will prevent the soft tissues from collapsing over the implant collar and from blocking complete seating of the final crown.

If the implant collar extends more than 2 mm subgingivally, one may minimize excess cement by displacing it

with an analog prior to final cementing of the crown (**FIGURE 19**). When a large volume of cement is removed extraorally, the clean-up of set cement from the subgingival area is greatly facilitated.

### Other Abutments

There are several abutments available to deal with other restorative situations and locations. For example, when the missing tooth has sufficient bone and mesiodistal dimensions, as in the molar region, a larger diameter implant with a wider platform is indicated (**FIGURE 20**). This increased diameter affords significantly greater implant surface area for osseointegration and a more-ideal emergence profile for the final restoration (**FIGURE 21**). A larger bearing area better distributes the load of posterior occlusion. The components and procedures are identical to those

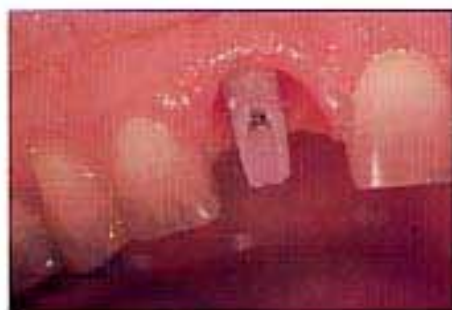used with the standard abutment. Due to the posterior location of most wide-body implants, one would usually temporize with a simple protection cap. Cementation considerations are similar to the standard abutment; however, because these abutments are often shorter than the standard due to reduced interocclusal distance, the additional retention afforded by stronger cement may be needed. Retention may also be enhanced by a lateral set screw.

A narrow implant and abutment can be used for mandibular incisors, maxillary lateral incisors, and some small premolar areas (**Figures 22, 23**).

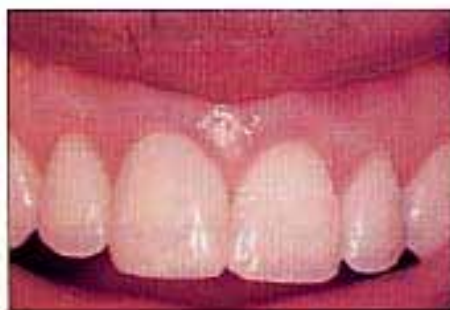### Custom Abutments

There will be situations in which the implant collar (the finish line of the restoration) is intentionally located deeply subgingivally to help the restorative dentist develop the optimum esthetics of the final restoration. This usually occurs in the anterior region and the mesial aspect of the maxillary first premolar. If the final crown margin extends to this deep margin location, a significant complication may occur during cementation. Excess cement can be driven over, around, and under the implant collar during crown placement. This subgingival cement can be very difficult, if not impossible, to remove completely; and these retained cement fragments may cause considerable soft tissue inflammation and infection.

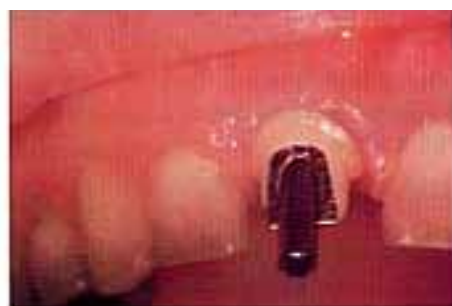The best way to avoid “deep” finish lines affecting implant-borne anterior crowns is to use the custom abutment (**FIGURE 24**). The clinician may then elevate the margin to a more coronal location. With the finish line, and thus the excess cement, made more accessible, the complication of excess cement removal is greatly reduced. There are other advantages of using the custom abutment in the anterior teeth. The long axis of the implant may be in a different inclination than that of the final crown. The custom abutment can correct this discrepancy in both labiolingual and mesiodistal



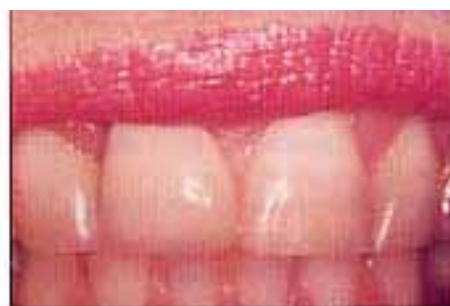**FIGURES 24.** Ceramo-metal custom abutment on tooth #8.



**FIGURES 25.** Final ceramo-metal crown cemented on the custom abutment shown in Figure 24.



**FIGURES 26.** Soft tissue that has been sculpted by a properly contoured provisional crown.



**FIGURES 27.** Provisional restoration veneered with microfill composite resin.

directions. The resulting contour enhances tissue health and architecture for an optimum esthetic result (**FIGURE 25**).

To maximize the esthetic result, one should sculpt the surrounding tissues with a carefully made provisional crown prior to the final impressions (**FIGURE 26**). The technique that uses a plastic coping and stock crown or prefabricated clear shell works well. For the cosmetically demanding patient, one may modify the shade of the provisional crown by removing approximately 1 mm of labial acrylic and directly bonding microfill composite resin to the acrylic surface (**FIGURE 27**).

One may fabricate the custom abutment by casting metal to a stock screw-retained abutment. This custom abutment is secured to the implant with the appropriate screw, and the crown is cemented onto it.

## Conclusion

This article has described a technique that will greatly facilitate the incorporation of osseointegrated dental implant restorative treatment into the general practitioner's routine procedures. This technique is just a beginning. The principle and procedures discussed can be expanded to apply to a wide variety of more-involved restorative situations that may be more complicated. As one's experience and skill increases, the way one thinks about cases with missing teeth will change considerably. The care one provides to patients will progress to a higher level, a level that fully respects the ideals of mentors who encouraged their students to preserve tooth structure with conservative gold restorations.

# A Career in Implantology

STEVEN A. GOLD, DDS

**ABSTRACT** There are few dentists who don't marvel at the ability to replace missing teeth with metal and porcelain. Yes, implant dentistry has arrived in California, rooted in decades of scientific research that has made such technology possible. The art and science that is implant dentistry was forged in the laboratories and clinics of Sweden, advanced and refined throughout Europe, and finally brought to the shores of North America. As the Journal posed the question, "Who were the leaders who helped integrate implant dentistry into everyday practice?" the name Mel Schwarz was among those that came up consistently. A look into his representative career and philosophy is a look into the positive role implants play in the lives of dentists and patients everywhere.

Dr. Schwarz is a periodontist in Torrance, Calif., who has limited his practice to the surgical placement of dental implants since the earliest days of osseointegration in the United States nearly 15 years ago. During this period, he has become part of a well-known international community of distinguished individuals devoted to dental implantology. At the time of this interview, Dr. Schwarz had just completed his term as president of the Academy of Osseointegration, regarded by many throughout the world as the foremost purveyor of scientific information on dental implants. Journal associate editor, Steven A. Gold, DDS, interviewed Dr. Schwarz for this issue.

---

**T**here are few dentists who don't marvel at the ability to replace missing teeth with metal and porcelain. Yes, implant dentistry has arrived in California, rooted in decades of scientific research that has made such technology possible. The art and science that is implant dentistry was forged in

the laboratories and clinics of Sweden, advanced and refined throughout Europe, and finally brought to the shores of North America. As the Journal posed the question, "Who were the leaders who helped integrate implant dentistry into everyday practice?" the name Mel Schwarz was among those that came up consistently. A look into his

representative career and philosophy is a look into the positive role implants play in the lives of dentists and patients everywhere.

Dr. Schwarz is a periodontist in Torrance, Calif., who has limited his practice to the surgical placement of dental implants since the earliest days of osseointegration in the United States nearly 15 years ago. During this period, he has become part of a well-known international community of distinguished individuals devoted to dental implantology. At the time of this interview, Dr. Schwarz had just completed his term as president of the Academy of Osseointegration, regarded by many throughout the world as the foremost purveyor of scientific information on dental implants. Journal associate editor, Steven A. Gold, DDS, interviewed Dr. Schwarz for this issue.

**STEVE GOLD:** *I have heard a colleague describe you as an "archetype for the successful, happy dentist." What advice would you share with a young dentist who seeks success and happiness in his career and personal life?*

**MEL SCHWARZ:** (laughs) I'm not sure I have any of the answers, but there are two things I have learned in my career that I wish I could have learned years ago. First, I've learned that one of the biggest keys to happiness is giving to others. When we're young and we want to build our reputations, and we want to acquire some material possessions, and we're trying to build an empire, the focus can sometimes be about what's in it for me. The time you really get happy in your personal and professional life is when you appreciate that you are making a contribution to others. In dentistry, this means that the dentist must stay focused on doing what's in the best interest of the patient.

The second thing I've learned is that

dentistry is a very lonely field. I would have been burned out a long time ago if I didn't have the relationships I have with the dentists that I work with. What I've done in my career is develop real tight working relationships with other dentists. We work together. We share ideas together. That's what's made it exciting and interesting for me and kept me turned on to dentistry through the years. They challenge me. They tell me what's wrong, and I try to find solutions for them.

**SG:** *Give us a background of your professional training and how you made the transition from student to teacher.*

**MS:** I was mentored by teachers who were world leaders in the field of occlusion and restorative dentistry. Great leaders like Dr. Rex Ingraham were instrumental in my dental school training as they were in guiding the profession to where it is today. While at USC, I was introduced to Dr. Nate Friedman who was a tremendous influence on my decision to pursue advanced training in periodontics. I was fortunate to receive this training at Boston University School of Graduate Dentistry because it gave me a different perspective on dentistry. Under the tutelage of individuals such as Dr. Jerry Kramer, I gained a greater appreciation for the biological foundation of dentistry. When I came back to Southern California to begin practicing, I began to look toward integrating the technical aspects of occlusion and restorative dentistry with the biologic principles I learned in Boston.

I believe that the specialist can be a leader and educator for his or her dental community. Throughout my 36 years of practice, I have constantly provided educational opportunities for the South Bay dental community so that we could explore new ideas and grow together. I know that there are other specialists

that do this as well. I felt it was necessary to provide the dentists with whom I worked this type of orientation -- an approach to dentistry that integrated the restorative aspects with the biologic aspects. I arranged for my restorative dentists to go back east to the University of Pennsylvania to receive this type of training. Meanwhile, I became rather heavily involved in teaching in both the periodontics and occlusion departments at USC for awhile.

**SG:** *How did implants fit into this philosophical approach you were developing?*

**MS:** As a periodontist, my practice was primarily surgically based. Yet I understood the importance of the relationship between restorative dentistry and the periodontium. When implants arrived on the scene, it was only natural to apply this integrated approach to this technology as well. If implant dentistry were to be a successful treatment modality in everyday dentistry, it was clear to me that it must be a restorative-driven procedure. Thus an integrated restorative-surgical approach was mandatory.

**SG:** *For a dentist who is perhaps inexperienced in restoring implants, what skills are necessary to provide successful implant restorations?*

**MS:** Restoring implants today is, in many ways, easier than restoring teeth, if the implants are placed in the correct position. Problems arise, mostly, from implants that are not positioned correctly. When the position is correct, restoring the implant is really simple. You don't have to do any tooth preparation. You don't have to pack cord. Impression copings allow you to capture margins easily. The restorative process really becomes enjoyable.



**SG:** *How did you help restorative dentists begin to master the skills necessary to provide successful implant dentistry?*

**MS:** First of all, I am fortunate that I came to work with a group of dentists who were highly motivated and were interested and driven to achieve excellence. I mentioned before about their willingness to attend continuing education to constantly better themselves and I have always been impressed by their dedication. For the past 15 years, I have brought leaders in the field of implant dentistry to this area so we can learn together. I make it very convenient for the dentists I work with to obtain the continuing education they need to achieve excellence.

Dr. Braden Stauts, a prosthodontist, was instrumental in developing training courses with me in the early days of implant dentistry. We practiced together in this office and set up a training operatory where dentists could bring their own patients and receive certification and training as they provided treatment.

**SG:** *What role did you and your team have in helping dentists communicate better with the surgeons placing implants?*

**MS:** First of all, we developed the DentaScan, which was the first CT scan program designed to aid in the diagnosis and treatment planning of implants. This helps determine where the implants should go and in what direction they should go.

Second, we took the concept of a radiopaque stent and developed it into a real discipline that would facilitate better communication from the restorative dentist to the surgeon. With such a stent, the surgeon could more easily place the implants in the position most suitable for the restorative dentist.

**SG:** *After an implant is placed, what do you as the surgeon do to facilitate the restorative portion of the procedure?*

**MS:** I began to develop lists of all of the restorative components required for the different implant systems. Due to the number of different systems and components, there seemed to be a lot of confusion in dental offices when it came time to order and organize these restorative components. What we do now is place the abutment for the restoring dentist and send all of the necessary components with the patient back to the dentist. We want this to be a user-friendly process.

**SG:** *What is the biggest obstacle to greater acceptance of implants as a viable option for replacing a missing tooth?*

**MS:** It's the fact that implants have not traditionally been taught in dental school to the level where young dentists feel comfortable restoring them. Fixed prosthodontics and endodontics are taught to that level, so for many dentists, those become treatments of choice, even when implants may provide a superior result and one with a greater long-term prognosis.

**SG:** *Where can dentists receive the training they need to provide implant dentistry for their patients or to improve their current skill level?*

**MS:** There are generally three sources I would recommend. One is courses provided by the implant manufacturers. A second is continuing or graduate level training at dental schools. Finally, there are a lot of independent courses and meetings that provide excellent training in implant dentistry. The group I have been involved in, the Academy of Osseointegration, has an annual meeting with intensive three-day programs with tracks in diagnosis and treatment planning, restorative technique, or

surgical technique. AO is unique in that it is 100 percent focused on providing education for implant dentistry and it is completely multidisciplinary.

**SG:** *How did the Academy of Osseointegration originate?*

**MS:** Osseointegration was brought to North America in 1982 by George Zarb, a prosthodontist practicing in Toronto who is now professor and chair of the Department of Prosthodontics at the University of Toronto. He became aware of Brånemark's work in Sweden. He put together a conference in which he invited representatives from all of the dental schools plus representatives from other professional organizations. Out of that meeting, a study club formed in the Northeast to exchange ideas and information about osseointegration; and that group grew into the Academy of Osseointegration in 1986. It now has members in 72 countries.

**SG:** *What's in the future for implant dentistry?*

**MS:** I see two main areas of focus that will probably be developed further. The first is immediate loading of implants so that the waiting period between placement of the implant and placement of the restoration will be drastically reduced. The second is advances in bone grafting and regeneration, which will allow us to better place implants in the proper position for restoration.

Beyond that, I think that implants will someday be replaced by genetically engineered teeth. I don't know how far away that will be, but there is some research being done in that area.

# Medical Treatment That Sucks

Robert E.  
Horseman, DDS

If a couple of German researchers are correct, you may soon be able to go into your local pharmacy and overhear a conversation like this:

"I'd like a couple of leeches, please. The old osteoarthritis is kicking up again."

"Yes, sir. May I ask if this is your first time with the little fellows? If so, you might want to purchase Heinrich Krautzmeyer's illustrated brochure on "The Care and Feeding of Hirudinea -- The Blood-sucking Annelids."

"Thanks anyway. Don't bother with wrapping, I'll just attach 'em right here."

Drs. Gustav Dobos and Andreas Michalsen of the Essen-Mite Clinic in Essen, Germany, declare that leeches have gotten a bum rap. Too many movies such as the "African Queen" have portrayed these annelid worms as voracious predators lurking in every murky freshwater river and stream from here to Zimbabwe. There they lie doggo, waiting for some hapless victim to wade right into their trap, whereupon they glom onto him like a freeloading relative. The ensuing scenes always show the horror-stricken actor trying to pry the disgusting creatures off his extremities with cigarettes, blowtorches or crowbars before they've sucked his blood supply right down to empty.

Conveniently forgotten is the fact that during the 19th century leeches were commonly used by the medical profes-

sion in the treatment of many conditions. The Bayer company is largely responsible for the gradual disuse of this modality. Its advertising pitch of "take two aspirin" seemed to strike a more favorable response from a patient clientele than "affix two slimy, bloodsucking leeches to the afflicted part until the filthy things are full of your vital fluids, then discard in an appropriate manner."

Well, stop the presses! Leeches may be on the verge of a comeback more successful than John Travolta's. Apparently their PR people, working with the German scientists, are putting out the word that the saliva of leeches contains various analgesic, anesthetic and histamine-like compounds. Attach a couple of salivating leeches to an osteoarthritic knee for 80 minutes and bingo! patients receive pain relief within three days. The greatest effect comes 24 hours after treatment, at which time the leech spit seems to dry up and the creatures insist on being given a break, or at least offered a curiously strong Altoid to suck on.

The upside of all this is that there seem to be no side effects other than the sore spot you would expect from a couple of rabid leeches gnawing on your hide. The downside is that the leeches fall into the patient's socks and sometimes right into his shoes. Patients, given the choice, frequently opt for the osteoarthritis in

preference to walking around with squishy leech-laden shoes. German scientists are developing a sort of lederhosen-knick-erbocker costume to corral the leeches where they belong.

The point of all this, in case you were wondering, is that old-time remedies are being resurrected and re-evaluated. Fortunately, dentistry formerly enjoyed a wealth of remedies that were unceremoniously dumped upon the advent of sodium brevit, antibiotics and high-powered analgesics.

Look for a revival of the mandrake plant, the root of which contains a narcotic and was used extensively by the ancient Babylonians and Egyptians to treat toothache. Less effective, but certainly more captivating, according to historian Dr. Malvin Ring, was the notion held by oral surgeons of the Renaissance era that the liquid left after boiling little green frogs would loosen the teeth and make them fall out. Many of the little green frogs, who were under the impression that they were transmogrified princes awaiting the buss of a beautiful princess, were horrified by this idea, vowing never to patronize an oral surgeon who held this belief.

Dentists of the time discovered, as have you and I, that actually working on the offending tooth was frequently awkward, inconvenient or downright impossible. Dr. Ring reports that they sensibly

chose from their vast pharmacopoeia that featured garlic, juice of pellitory, ivy, chicory and rose petals. These were administered through every possible bodily orifice, the ear and nostril on the side of the offending tooth being the favorite routes to relief.

This may come as a surprise to Pfizer, J & J, Merck, et al., but back in the Middle Ages, a universal antidote was theriac, a concoction initially whipped up by Mithridates, king of Pontus (120-63 B.C.) to thwart poisoners. The search for a good, all-around theriac continued into the 18th century. Some formulations had as many as 230 ingredients, including ants, worms and dried vipers. Vipers vigorously resisted the dehydration process, but theriacs using wet vipers proved to be untenable.

We need not to fall into complacency regarding cures and treatments. Indeed, right at this moment on the surface of your fish pond or under a rock in your backyard may be just the thing to put periodontists out of business and give cosmedontists something else to think about. Green frogs, however, may be an endangered species. Check with the EPA before you bring them to a full boil.