CDA

Primary Dentition
Root Resorption
Decoronation

JOURNAL OF THE CALIFORNIA DENTAL ASSOCIATION VOL. 28 NO. 11

November 2000

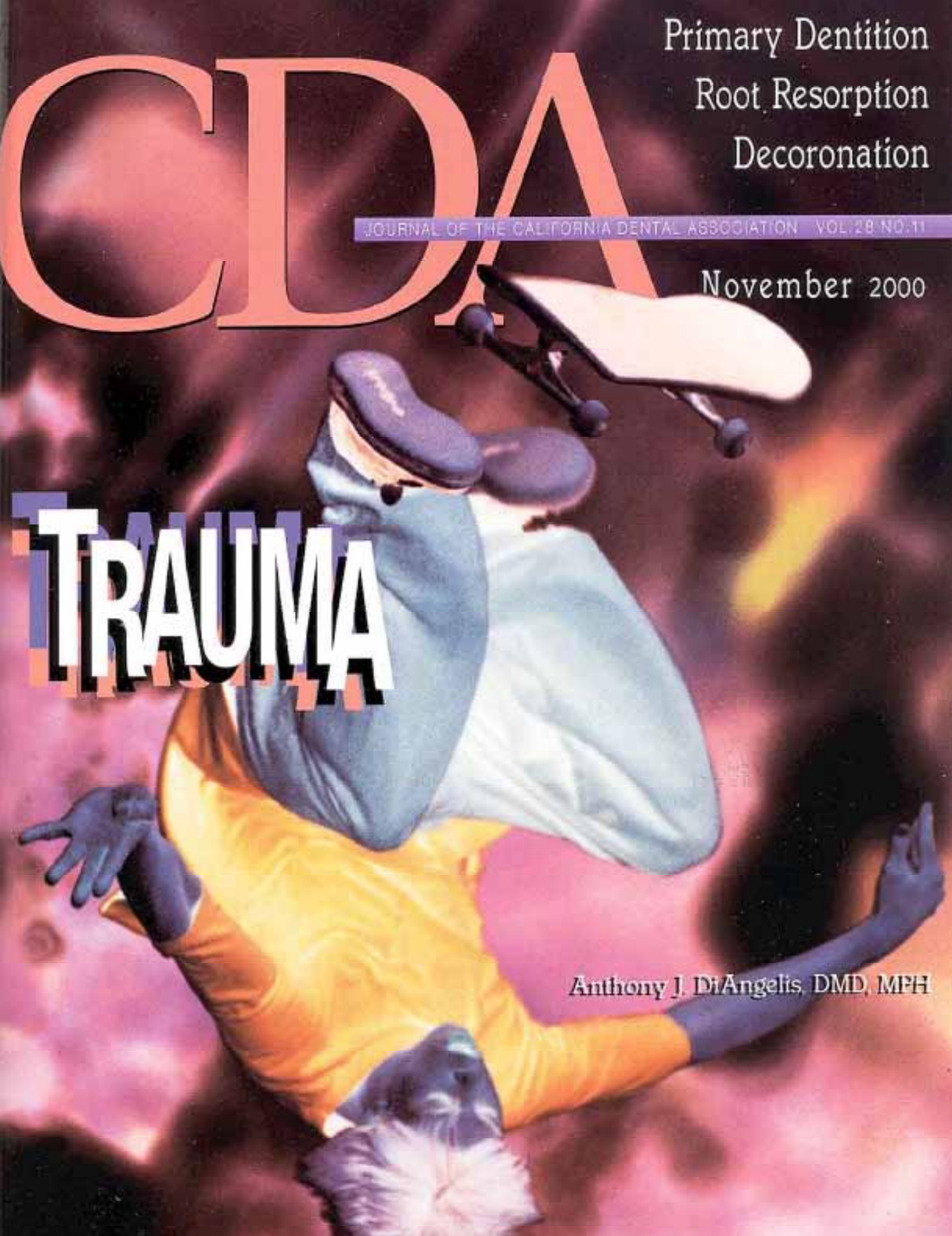

TRAUMA

Anthony J. DiAngelis, DMD, MPH

OF THE CALIFORNIA DENTAL ASSOCIATION
Journal
CDA Journal
Volume 28, Number 11
NOVEMBER 2000

DEPARTMENTS

FEATURES

CDA JOURNAL, VOL 28, Nº11

Achieving Consensus

Jack F. Conley, DDS

The case: The Federal Trade Commission vs. the California Dental Association regarding advertising guidelines. Many of us who had seen the start of this FTC legal action against CDA back in the mid 1980s were beginning to believe that resolution of this matter might be a career, if not a lifetime, in coming.

It is hoped that the recent 25-page ruling by the 9th Circuit Court will stand as the final decision reversing a seemingly endless series of legal proceedings that have hovered over the association since the FTC initially contended that association advertising restrictions violated antitrust laws. The FTC reasoned that CDA restrictions on price and quality claims by members were subjective and limited consumer access.

We well remember the difficult decisions that have periodically faced leadership to continue the fight by authorizing the resources to affirm the association's position and pursue the matter at the next level of appeal. Leadership has always believed that the position of the association was correct and was positive about the potential for success based upon the advice and the analysis provided by legal counsel. However, along the long pathway leading up to and including the review by the U.S. Supreme Court in January 1999, it began to look like CDA was engaged in a costly uphill battle on a principle that might no longer be defensible.

After losing an appeal on the FTC ruling by the 9th Circuit Court in 1997 and losing a petition for a rehearing in January 1998, the future looked pretty bleak for a saga that had pestered the association for more than a decade. The fact alone that the U.S. Supreme Court had accepted and agreed to hear the case in early 1999 was considered somewhat of a victory. Hopes were higher than they had been for a long time as the Court began its review. "Our Day in Court" in this space in March 1999 pointed to "guarded optimism that the Supreme Court could come forward with a ruling on the broad issue that would give nonprofit professional associations some relief from an FTC that has appeared to venture beyond the authority granted it in the original legislation creating the commission."

Unfortunately, that optimism crashed as the Supreme Court upheld the FTC's jurisdiction over associations, which was one of the major issues in the case. However, in what now might be considered a positive note, the court kept the door open on the other issue before it, the appellate ruling supporting the FTC's contention that CDA's advertising restrictions were anticompetitive, by returning that part of the case back to the 9th Circuit Court. Considering that the 9th Circuit had previously denied the appeal, this action clearly did not contribute to a feeling of optimism by CDA leadership at the time. The case had already been very costly to organized dentistry and had a life that seemed excessively long.

With a suspension of some sections of the Code of Ethics since 1995 as a condition of earlier decisions, it seemed to many that the FTC objective had long been accomplished and that life would continue on as is. Many longtime members had been unhappy with "negative" changes in the profession they felt had been imposed by regulations set forth by outside agencies such as the FTC. Nonetheless, because of what had become a long-term imposition of restrictions, there seemed to be an acceptance of the way things were by many dentists.

Thus, a surprise announcement that the 9th Circuit Court of Appeals had instructed the FTC to dismiss its suit contending that CDA advertising guidelines are anticompetitive seemed to take a while to sink in. It is also clear that it took the court a long time (translated, another review) to realize that CDA Code guidelines can serve the consumer in a positive, protective fashion.

This victory could be only temporary if the FTC elects to appeal the decision. Initially, however, that does not seem likely to our legal experts. Closure of this saga has depended upon the expertise and guidance of Peter Sfikas, the American Dental Association's general counsel. We concur with those who have lauded his efforts.

As for the future, CDA's Judicial Council, and ultimately leadership, will need to look carefully at the advertising guidelines that are now required for contemporary practice. An analysis and reworking of the document should be the order of the day without an urgency to restore the restricted guidelines in total.

The recent court decision suggested that the court has respect for guidelines that offer protection for the consumer. If we use that experience as the template, a document for this millennium will substantially benefit from what has been a long and sometimes disquieting journey in support of some of the time-honored standards held by organized dentistry.

CDA JOURNAL, VOL 28, Nº11

Charitable Trust an Option for Practice Transition

By Debra Belt

In the next 20 years, the United States will witness the largest transfer of wealth in its history as baby boomers settle their finances and leave their legacies. Included in this passing on of assets will be thousands of practices from California dentists who are expected to retire.

This anticipated exodus from dentistry unleashes a barrage of considerations about the future of the profession and the individuals retiring from it. One idea that addresses concerns of retiring and future generations is the option of transferring a practice to a charitable remainder trust then selling the practice, thus creating a benefit to a charitable cause and a tax break for the donor. California dental schools and the Dental Board of California have had inquiries about charitable remainder trusts, and an Internet search on the subject turns up a plethora of Web sites, all signaling increasing interest in this area.

In some cases, the idea of donating a practice to a charitable remainder trust has been presented as an easy tax break, but anyone looking into the subject will find it to be legally complex with many professionals issuing caution about the actual feasibility.

A charitable remainder trust is a special tax-exempt irrevocable trust arrangement written to comply with federal tax laws and regulations. In a financial give-and-receive arrangement, a charitable remainder trust does offer a tax benefit, but experts in the field are clear on the fact that establishing such a trust should be viewed as an act of goodwill, and approached only with the assistance of legal and financial counsel familiar with the process.

Berney Neufeld, PhD, director of development for the University of the Pacific School of Dentistry in San Francisco says the idea of donating a practice to a charitable remainder trust is not for everybody.

"This situation would work for approximately 30 to 40 percent of dental practices. Specific requirements about corporation codes and earned income make it a complicated transaction. But for the practices that meet the requirements, this could be something special.

"The way to think about the key structure is that an asset has two parts; the actual practice and the income it generates. With a charitable remainder trust, you divide the two and give away the asset but keep the income."

In the case of a charitable remainder trust, the trust is established and assets (money, stocks or property) are transferred to the trust. The assets are then sold without creating a taxable event, thus increasing the income potential of the assets. The proceeds from the sale are used for investments to generate income for the donor and spouse. The amount of income a beneficiary receives can vary between a minimum of 5 percent and a maximum based on IRS actuarial tables, which take into account the amount invested and the donors' ages. A practice transferred to a charitable remainder trust will generate an income tax deduction for the donor. At the death of the donor or donors, the remaining assets in the trust go to the charity.

"The downside is that assets are given away," Neufeld said. "The upside is that you have more money to invest and generate income than if you had kept and sold the practice. For instance, say you sell your practice for $1 million. After taxes, you may have $600,000 left to invest. With a charitable remainder trust, the full $1 million from the sale of the practice can be reinvested in order to generate income.

"While a charitable remainder trust has a cash net value, at its core it's a way to make a gift," Neufeld stressed. "It's essential that the donor think about it in this way and not just a way to avoid taxes."

"The first consideration of an 'estate gift' is to benefit the cause," said Michael Haggin, a assistant dean for development with the University of California at Los Angeles School of Dentistry. For instance, a donation to the school could be used as an endowment for a professorship in a specialized area such as endodontics or for student financial aid. "We are especially interested in assisting those students who have hearts for public service. We want them to be able to leave UCLA with low enough debt loads to be able to practice dentistry in underserved areas," Haggin said.

"In addition to helping the cause, an often overlooked benefit of a charitable remainder trust is that the donor doesn't have the burden of managing assets," Haggin said. "The university is prepared to act as the

More Internet Users Seeking Health Info

Nearly 100 million people have gone online in search of health care information, according to the results of a recent Harris Poll.

At 98 million people, the number of Internet users looking for health information is up 81 percent from two years ago. Researchers attribute the increase to the continued growth in the online population, which they estimate at about 56 percent of American adults, or 114 million people.

An increased proportion of those online who have used the Internet to look for health care information also accounts for the growth during the past two years. According to the latest poll, 86 percent of all users sought such information, as compared with 71 percent of all users in 1998.

The Harris Poll on online health care information was conducted by telephone in May and June among a cross section of 1,001 adults in the United States. The results do not include people under 18 who have looked for health information online.

trustee, if the donor wishes. It's comforting to some people to have the burden of asset management on the university."

"There is also the tax advantage," Haggin added. "It's almost as if the IRS is offering to share the net cost of the donation."

"A drawback to an estate gift is that it limits the flexibility of how assets are used," Haggin said. The type of person for whom an estate donation would work well is someone who cares about a cause and enjoys giving. "This type of person usually has established a record of giving throughout his or her life. It is also best for someone who has a settled pattern of life and doesn't expect drastic changes."

"Charitable remainder trusts are universally accepted, and the area of charitable giving is expected to explode in the next 20 years" said Thomas Harding, registered securities principal with Raymond James Financial Services and author of Charitable-Remainder-Trust.com, who says he has seen medical offices, law firms, and veterinary practices transferred to such trusts.

"However, charitable remainder trusts are a very specialized area, and anyone considering this option must be absolutely certain they are working with professionals who are well-versed," Harding warned. "There are catches with charitable remainder trusts, and they have to be overcome in certain ways. Anyone thinking about establishing such a trust should consult their attorney and accountant and be sure they are familiar with the different kinds."

Harding does not recommend self-administration of a trust. "The trustee is responsible for filing tax returns, distributing income checks and proper record keeping. A third-party administrator, such as an accountant, is best for proper financial management of a charitable remainder trust."

"It's an interesting idea, and I have heard it discussed," said Mark Kenny, senior vice president of the Keller Group, Investment Management, Inc. "But from our standpoint, a dentist considering donating a practice to a charitable remainder trust should be cautious. There are legal issues, such as the restrictions of a professional corporation, which must be clearly defined. It's common for assets such as stocks and appreciated securities to be transferred into a trust, but the idea of donating a practice is not common. This isn't to say it can't be done, or that it isn't an appealing concept, but it appears to be somewhat unproven and untested."

Orthodontic Needs Increasing Among Special Needs Patients

During the past 30 years, more than three-fourths of people with mental retardation/developmental disabilities have been deinstitutionalized, and there has been a corresponding need to increase awareness among orthodontists about the growing necessity for treatment of these individuals within their communities, according to the an article in the July 2000 issue of the American Journal of Orthodontics and Dentofacial Orthopedics.

The authors -- H. Barry Waldman, DDS, PhD; Steven P. Perlman, DDS; and Mark Swerdloff, DDS -- noted that changing social policies, favorable legislation for people with disabilities, and class-action legal decisions have led to the establishment of community-oriented group residences, and enhanced personal family residential settings, accompanied by the closure of many large, state-run facilities. However, the success of community-based programs depends on the availability of support services, the authors stated -- particularly private practitioners who are convenient and accessible to deinstitutionalized individuals and trained and willing to deliver care.

To provide some insight into the need for orthodontic services for these youngsters and adults, the authors asked: "Do we believe that persons with disabilities need functional and esthetic considerations comparable to those of 'normal' persons?"

The reality is that youngsters with mental retardation/developmental disabilities grow older and that periodontal disease is an increased possibility with a maloccluded dentition, they answered. Severe esthetic malocclusions can compromise already difficult social relationships and potential employment opportunities, the authors added.

Children and adolescents with special needs exhibit a higher percentage of malocclusions than the normal population. Children with mental retardation/developmental disabilities may have dentition difficulties resulting from habits such as mouth breathing and tongue thrusting, diets lacking enough rough and coarse foods that require thorough chewing, increased levels of caries, and the loss of teeth and space maintenance, the authors explain. Individuals with mental retardation may not comprehend the need for oral hygiene, the authors note, and those with physical disabilities may lack the dexterity to accomplish the needed oral hygiene.

Physicians Easing Use of Antibiotics

The use of antibiotics to treat children with respiratory diseases has declined steadily in recent years, according to results of a survey conducted by the Centers for Disease Control and Prevention presented at the 38th Annual Meeting of the Infectious Diseases Society of America.

"The decreased use of antibiotics coincides with increased awareness that many bacteria and other disease-causing organisms are developing resistance to antibiotics. Our survey suggests that physicians are getting the message that the overuse of antibiotics can be harmful," said Linda F. McCaig, MPH, survey statistician with the National Centers for Health Statistics of the CDC.

According to the survey, the annual rate at which office-based physicians prescribed antibiotics for infectious respiratory diseases (otitis media, upper respiratory infection, bronchitis, sinusitis, and pharyngitis) in children younger than 15 decreased by 34 percent

Decline in Medical School Applications Continues

Applications to the 125 U.S. medical schools declined by 6 percent in 1999, the third consecutive year that the number of applicants has decreased, according to an article in the Sept. 6 issue of the Journal of the American Medical Association.

Barbara Barzansky, PhD, and colleagues from the American Medical Association used data from the 1999-2000 Liaison Committee on Medical Education Annual Medical School Questionnaire, which had a 100 percent response rate, and other sources to describe the status of medical education programs in the United States.

The authors found that there were 38,529 medical school applicants in 1999. The total number of male applicants decreased by 9.1 percent, from 23,216 to 21,096 and women applicants decreased by 2.0 percent, from 17,787 to 17,433.

The researchers also found that new subject areas are entering into the medical curriculum. For example, in 1999-2000, 82 schools (66 percent) reported including content related to alternative/complementary medicine as part of a required course. According to the authors, the need for physicians to possess skills related to cultural competence has been recognized by medical schools. There was one medical school that had a separate required course covering cultural diversity, and 109 schools (87 percent) included content on this topic as part of a required course or clerkship.

between 1989-1990 when approximately 669 antibiotic prescriptions were written for every 1,000 children and 1997-1998, when the rate was 439 per 1,000 children. In 1989-1990, 737 antibiotic prescriptions were written for every 1,000 office visits among children with respiratory diseases (some children visited their physicians' offices more than once) compared with 647 per 1,000 office visits in 1997-1998, a 12 percent decrease, according to McCaig.

"We are extremely encouraged by the reductions in antibiotic prescribing for pediatric respiratory infections. Activities are taking place around the country, reflecting partnerships between the public health community, medical societies, industry, and others to promote appropriate antibiotic prescribing. It appears that prescribing behavior is changing," said Richard E. Besser, MD, medical epidemiologist with the National Center for Infectious Diseases and director of the campaign to promote appropriate antibiotic use for outpatient respiratory diseases.

Tongue Piercing Can Pose Infection Hazard

Tongue piercing can not only chip a tooth, but can also lead to life-threatening infections, according to a report given at the Infectious Diseases Society of America annual meeting in September.

Dr. James D. Richardson, from Indiana University School of Medicine in Indianapolis, described two cases of serious complications that have arisen in people who had tongue studs and did not remove them when there were signs of local infection.

In each case, the patient developed life-threatening secondary infections. The first case involved a 29-year-old waitress who reported pain in her tongue and chest a week after having her tongue pierced. When doctors examined her, they detected abnormal fluid around her heart that was infected with a bacteria that can cause meningitis.

In the second case, a 22-year-old woman presented to the doctor a year after having her nipple and tongue pierced. This patient developed a chest abscess that needed to be drained and treated with antibiotics.

After treatment, she took out the nipple ring, but kept in the tongue stud, Richardson said. Three months later, she was back with a recurrence of her chest abscess.

"With tongue piercing, initially, if infections develop, there can be swelling and pain and tenderness of the tongue, and then there can be pain and tenderness in the neck," Richardson said. "If the infection remains locally, the tongue stud should be removed. If the tongue stud is left in place, it remains a foreign body and can become a jumping point for other infections," he said.

Nicotine Addiction Can Hit Within Days

In contradiction to earlier reports, addiction to nicotine may start within a few days of starting to smoke and after just a few cigarettes, according to an article in the journal Tobacco Control.

"The first symptoms of nicotine dependence can appear within days to weeks of the onset of occasional use, often before the onset of daily smoking," the researchers wrote.

The study by researchers from the University of Massachusetts and Harvard

Medical School of about 700 teenagers aged between 12 and 13 from seven schools in central Massachusetts in 1998 showed that 95 students smoked at least one cigarette a month.

Of these 95 monthly smokers, one in five reported nicotine dependency symptoms within four weeks of starting to smoke and 16 developed symptoms within two weeks.

In total 60 out of 95 monthly smokers said they had experienced one or more symptoms of nicotine dependence.

The researchers said experiments on mice showed the number of nicotine receptors in the brain increased rapidly after just the second dose of nicotine, providing a mechanism for the quick development of dependence.

Comfort Book on Dentistry

The popular Chicken Soup for the Soul series of books has added dentistry to its list of topics.

Chicken Soup for the Dental Soul is a collection of 61 heartfelt stories that portray dentistry as a warm and caring profession. The contributors include dentists, hygienists, assistants and lay people. Among the Californians are Luz Abrera-Crum, DDS, of Westlake Village; Julie Karnazes, DDS, JD, of San Francisco; Michael Kowalski, DDS, of Castro Valley; and Armand A. Lugassy, DDS, PhD; of Novato.

The Chicken Soup series encompasses titles for many groups -- including mothers, teens and Christian families. Several of the titles have spent time on bestsellers lists.

Chicken Soup for the Dental Soul costs $12.95 plus shipping and handling and can be ordered by phone at (800) 247-6553 or by mail from DMD House, 1250 Oakmead Parkway, Suite 210, Sunnyvale, CA 94085.

New NIDCR Director Named

Lawrence A. Tabak, DDS, PhD, has taken the reins as director of the National Institute of Dental and Craniofacial Research.

Tabak is the former director of the Center for Oral Biology, Aab Institute of Biomedical Sciences, at the University of Rochester. He replaces Harold C. Slavkin, DDS, who left the position to become dean of the University of Southern California School of Dentistry.

As NIDCR's seventh director, Tabak will lead an institute of more than 400 scientists and administrators on the National Institutes of Health campus and hundreds of grantees around the world. NIDCR scientists conduct research on the full spectrum of topics related to craniofacial, oral, and dental health and disease. Oral cancer, chronic pain conditions, salivary function and dysfunction, the genetics of craniofacial development, and biomimetics and tissue engineering are among the many issues addressed by NIDCR researchers.

Web Watch

The National Institutes of Health is one of the world's foremost medical research centers, and the Federal focal point for medical research in the United States. Its mission is to uncover new knowledge that will lead to better health for everyone. NIH works toward that mission by conducting research in its own laboratories; supporting the research of non-Federal scientists in universities, medical schools, hospitals, and research institutions throughout the country and abroad; helping in the training of research investigators; and fostering communication of medical information.

NIH has a comprehensive Web site. Among the topics and subtopics addressed are:

Health Information -- including consumer health publications, a clinical trials database, a list of toll-free information lines, and health literature references such as PubMed.

Grants & Funding Opportunities -- Including information about grant and fellowship programs and research training opportunities.

News & Events -- Including the NIH budget; press releases, which are released almost daily; and special reports.

Institutes, Centers & Offices -- including links to various related office, such as the National Cancer Institute, National Institute of Dental and Craniofacial Research, National Center for Complementary and Alternative Medicine, and the Center for Scientific Review.

NIH can be accessed at www.nih.gov.

Honors

Eugene Sekiguchi, DDS, has been named the new associate dean for professional and legislative affairs at the University of Southern California School of Dentistry. Sekiguchi is the 13th District Trustee of the American Dental Association, representing California.

George Davis, Jr., DDS, was named Dentist of the Year by the Southern California Academy of General Dentistry.

CDA JOURNAL, VOL 28, Nº11

Dental Trauma: Improving Treatment Outcomes

Anthony J. DiAngelis, DMD, MPH

Contributing Editor

Anthony J. DiAngelis, DMD, MPH, is the chief of dentistry at Hennepin County Medical Center and a professor at the University of Minnesota.

I am not certain if the following story is true or purely apocryphal, but it serves to introduce the theme of this month's *Journal of the California Dental Association*. A reporter was in the Chicago Bulls' locker room at the conclusion of another Chicago win during the brilliant Michael Jordan days. Michael was his usual commanding self, scoring 60 points. A rookie teammate played his first game that night, scoring but one point. The reporter, looking for a new angle for his column, asked the rookie "How will you remember your first game with the Bulls?" After a thoughtful pause, he responded, "I'll remember this as the night Michael and I combined for 61 points."

Given that most oral and dental injuries are sports-related and that it often requires the combined efforts of the entire dental team to restore patients to optimum pre-injury status, I am pleased to introduce a series of articles by the "pros" in dental trauma. Four years ago, contributing editor Dr. Donald Devlin, realizing the breadth and depth of this topic, solicited eight manuscripts on dental trauma for two consecutive issues of the Journal.

In revisiting this topic four years later, it is clear that there is much yet to be discussed. While general dentists and pediatric dentists are usually the frontline providers in the initial management of dentoalveolar injuries, complex cases require the expertise of endodontists, oral and maxillofacial surgeons, orthodontists, periodontists, and prosthodontists.

In the current issue, Dr. Clifton Dummett reminds us of the high frequency of falls and subsequent dentoalveolar injuries in the pediatric dental population. He reminds us that although deciduous teeth may be dispensable, we must communicate to parents that problems and sequelae of deciduous tooth injuries may not become evident until eruption of the permanent teeth.

Dr. Barbro Malmgren presents a

conservative technique for managing tooth submergence or infraposition resulting from ankylosis, a frequent complication in tooth replantation. Decoronation is a technique that preserves alveolar bone height and width and has been used successfully for years in Europe. While it has been well-documented in the European dental literature, it is a technique little known in the United States.

One of the newest and most efficacious materials in the field of endodontics is mineral trioxide aggregate. Due to its high biocompatibility, compressive strength, and superior sealing characteristics, MTA has found utility in the management of perforations, apexification, and root-end filling. In his manuscript, Dr. Leif Bakland describes the use and advantages of MTA as a pulp-capping agent. This promises to add to the clinician's armamentarium in preserving the pulp of traumatically injured immature permanent teeth.

External root resorption represents a significant complication in luxation and avulsion injuries. Dr. Martin Trope provides an insightful look into preventing, minimizing, and reversing resorption. He thoughtfully explores the etiology of external root resorption, presents current therapeutic approaches, and offers a look into promising potential techniques based on his extensive research in this area.

In summary, this issue of the Journal offers the practitioner up-to-date scientific information and clinical approaches to managing the unexpected but often encountered traumatic dental injury.

CDA JOURNAL, VOL 28, Nº11

Dental Management of Traumatic Injuries to the Primary Dentition

Clifton O. Dummett, Jr., DDS, MSD, MEd

ABSTRACT There is considerable information on traumatic injury management of permanent teeth. However, there are no conclusive guidelines for treating traumatized primary teeth. This article will summarize a number of issues relative to primary dentition trauma and provide a system for treatment.

AUTHOR

Clifton O. Dummett, Jr., DDS, MSD, MEd, is a professor in and head of the Department of Pediatric Dentistry at Louisiana State University School of Dentistry in New Orleans.

There is considerable information on traumatic injury management of permanent teeth along with specialty-generated treatment guidelines and protocols. In spite of numerous epidemiological studies and excellent review articles on primary tooth trauma,[1,2] there are no conclusive guidelines for treating traumatized primary teeth. The purpose of this article is to summarize a number of issues relative to primary dentition trauma and provide a system for treatment.

Epidemiologic Trends

Frequencies of primary tooth trauma range from 4 percent to 36 percent depending on the nature of the study and the country in which it was conducted.[3,4] Falls account for the majority of such injuries.[2] Soporowski and colleagues reported that 70 percent of lateral luxations in their sample were caused by falls.[5] Peak indices for primary tooth trauma have been reported to occur between 1 and 2 years of age.[6,7] Developmentally, children at this age are learning to walk and lack the coordination to minimize falls and avoid stumbling into furniture and other hard objects.

Boys are more likely to sustain primary tooth trauma than are girls, with frequency ratios ranging from 1.8-to-1 to 1.3-to-1.7,[8] Maxillary primary incisors have the highest predisposition for traumatic injury. Soporowski and colleagues determined that the existence of class II primary molar occlusion did not increase the risk of luxation injury to the primary dentition. However, mean overjet values of greater than 4 mm increased the risk of primary tooth intrusion.[5]

Studies consistently demonstrate that most primary tooth trauma results in displacement injury.[5,8,9] Borssen and colleagues, in their primary tooth sample, found that 74 percent demonstrated luxation injury in contrast to only 6.5 percent with coronal fracture and 1.5 percent with root fracture.[8] The frequency of the types of luxation injuries in primary teeth differ somewhat

among investigators with the combined categories of lateral luxation and subluxation being the most frequent (Table 1).

The major concern with primary tooth trauma is the potential for damage to the underlying permanent successor.[11] This may occur directly from the injury or from the residual infection associated with the traumatized primary tooth.[12] Andreasen and Ravn found that the child's age at the time of injury was the most significant factor influencing the development of defects in succedaneous permanent teeth.[13] They found that 60 percent children younger than 4 with traumatized permanent incisors demonstrated clinical and radiographic anomalies in their permanent successors.[13] Intrusion and lateral luxation of primary teeth had the highest likelihood of damage to the underlying permanent teeth. Andreasen has listed a number of possible permanent tooth sequela from primary tooth trauma with localized enamel hypoplasia having the highest frequency:[12]

- Enamel hypoplasia (Figures 1 and 2);
- Crown dilaceration;
- Odontoma-like malformation;
- Bifid root;
- Vestibular root angulation;
- Lateral tooth angulation or dilaceration (Figure 3);
- Partial or complete arrest of root formation;
- Sequestration of permanent tooth germ; and
- Disturbance in eruption.

Comprehensive Assessment Issues

Assessment for the child who has sustained either primary or permanent tooth injury should be comprehensive and systematic so that a diagnosis can be made and treatment provided as efficiently as possible. A detailed history and the time elapsed since injury are important components in evaluating the involved tissues and degree of luxation. The parents are critical resources in this history-taking process because they are more reliable providers of information than are the children themselves.

The past medical history is imperative to determining the existence of chronic diseases or medical complications that could affect dental treatment. Central nervous system involvement must be ruled out by means of a simplified neurologic assessment as advocated by Croll and Schneider.[14,15] Abnormal symptoms include loss of consciousness, nausea, vertigo, alteration in motor activity, rhinorrhea, headache, change in pupil size, change in reflexes, and alteration in sensory function. Completion of the tetanus inoculation series should be confirmed with the parents. If it is unclear whether the child is up to date with this series, he or she should be referred to a pediatrician for the administration of the appropriate tetanus booster.

The possibility of child abuse should also be ruled out. Mouden found that orofacial trauma was present in 65 percent of documented child abuse cases.[16] Oral manifestations typically associated with child abuse include lacerated maxillary frenums, fractured teeth, luxated teeth, and avulsed teeth. The dentist may be one of the first in a series of health professionals to detect evidence of child abuse, particularly in dental trauma incidents. He or she is legally obligated to report such suspicions to social and legal authorities.

The dental examination should be comprehensive and its focus should extend beyond the dental injury. The possibility of facial fractures should be ruled out. Lacerated soft tissues should be cleaned of debris and blood to facilitate determining the extent of involvement. Deep lacerations may require suturing if wound tissue cannot be adequately approximated. Resistant behavior during assessment and treatment may require restraint by the parent in a knee-to-knee arrangement with the dentist or through the use of a restraining device such as a papoose board. Documentation of the status of all hard and soft tissues affected by the injury as well as tooth involvement is critical to the evaluation process. Wilson provided a systematic list of resources to be included in the evaluation and documentation process:[2]

- Parental information and consent regarding the possible need for restraint;
- Clinical evaluation;
- Radiographic evaluation;
- Photographic injury documentation;
- History with emphasis on elapsed time of injury occurrence;
- The ruling out of child abuse and neurologic involvement;
- Determination of the degree of behavioral cooperation;
- Notation of caries experience, history of previous trauma, and presence of habits; and
- Assessment of parental compliance indicators.

Pulp testing in the clinical evaluation process is of little value due to its poor correlation with histologic status and the difficulty of the young child to provide reliable responses. Radiographic examination tends to be the best source of information in diagnosing the extent of the traumatized hard tissues as well as a good means of documenting the post-treatment outcomes of traumatic injury management. Maxillary and mandibular periapical radiographs are important in identifying the presence of post-traumatic dystrophic changes in afflicted teeth such

Figure 1. Opaque hypoplastic defect in enamel of maxillary central incisors as a result of primary tooth trauma.

Figure 2. Severe hypoplastic defect extending into dentin of the maxillary left central incisor as a result of primary tooth trauma.

Figure 3. Root dilaceration of the maxillary left central incisor as a result of primary tooth trauma.

Figure 4. Pulp canal calcification (calcific metamorphosis) of the maxillary primary central incisors as a result of trauma.

Figure 5. Lateral anterior radiograph demonstrating proximity of intruded maxillary primary central incisors to the developing underlying permanent successors.

Figure 6. Grey discoloration of the maxillary right primary central incisor as a result of traumatic injury.

Figure 7. Periapical radiograph demonstrating complicated coronal fractures of the maxillary primary central and left lateral incisors. Also note crown root fracture of the maxillary right lateral incisor.

Figure 8. Crown root fractures extending below cementoenamel junction of maxillary primary central incisors.

Figure 9. Periapical X-ray of primary right central incisor with root fracture in the apical one-third area.

Figure 10. Extrusion of maxillary primary central incisors. These teeth should be extracted.

Figure 11. Intruded maxillary left primary central incisor. This tooth should be closely monitored for re-eruption within one to six months.

Figure 12. Lateral luxation of the left maxillary primary central incisor with root apex protruding through the labial alveolar bone. This tooth should be extracted.

Figure 13. Avulsed maxillary primary central incisors. These teeth should not be implanted.

Table 1.

Frequency of Luxation Injury Categories in Primary Teeth

	Soporowski et al.[5]	Borssen et al.[8]	Borum et al.[9]	Schatz et al.[10]
Lateral luxation	57%	4.5%	34.1	10.3%
Subluxation	(Total sample)	45%	25.7%	18.3%
Intrusion	15.3%	8%	16.7%	23.0%
Avulsion	19.2%	7%	12.3%	6.4%

as pathologic root resorption and calcific metamorphosis (**Figure 4**). Parental and/or physical restraints can be effective adjuncts with the precommunicative or behaviorally difficult child. A lateral anterior X-ray film oriented parallel to the sagittal plane and perpendicular to the central ray is an excellent resource for determining the anterior-posterior relationship of an intruded or laterally luxated primary incisor relative to its underlying permanent successor (**Figure 5**).

Tooth Fractures

Enamel fractures in primary teeth are managed by either smoothing the sharpened margins of the fractured areas or restoring the missing tooth portion with composite resin. These teeth should be monitored for clinical and radiographic signs of pathology. Discoloration is a significant clinical entity associated with traumatized primary teeth. Borum and colleagues noted that 51.4 percent of 395 primary teeth discolored after being traumatized.[9] Yellow discoloration was the most frequently seen in this group and was commonly associated with pulp canal calcification (**Figure 4**). Permanent gray discoloration had the highest correlation with pulp necrosis[9] (**Figure 6**). Soxman and colleagues histologically evaluated discolored primary anterior teeth that were traumatized and found no correlation between coronal shade and histologic pulp status. Furthermore, they found that 78 percent of the discolored teeth had pulps with irreversible dystrophic changes.[17] Traumatized primary teeth with discoloration should therefore be closely monitored for increased potential for development of pulpal pathology.

Enamel-dentin fractures in primary teeth are managed by sealing the exposed dentin tubules with either a glass ionomer or dentin-bonding agent in conjunction with composite resin restoration. With instances of extensive crown loss, the afflicted tooth can be restored with a full-coverage restoration such as a composite resin "strip" crown. Another alternative is a stainless steel crown with esthetic modifications such as open-faced composite resin window or esthetic veneer to the labial metal surface. As previously mentioned, postoperative monitoring for clinical and radiographic pathology is also indicated.

Complicated coronal fracture management depends on the extent of pulpal and hard tissue involvement. Coronally fractured primary teeth that have sustained pulp exposures with roots that have been resorbed to a greater extent than one half the total root dimension should be extracted. Conservation of radicular pulp tissue with varying degrees of coronal pulp tissue removal followed by sealing against microleakage is the ultimate treatment goal in primary teeth that are not eminent of exfoliation. In spite of strong opinions against direct pulp capping in primary teeth, Jeppsen, Kopel, and the

American Academy of Pediatric Dentistry Guidelines on Pulp Therapy have supported treatment of clean pinpoint exposures with this technique in selected cases.[18-20] Ram and Holan reported short-term success with a partial pulpotomy technique for a primary central incisor that sustained a complicated coronal fracture in a 14-month-old child.[21] The procedure consisted of removing 1 to 2 mm of pulp tissue at the exposure site, followed by placing calcium hydroxide and restoring the tooth. Cvek has shown this technique to have the highest success rate of all vital pulp therapy techniques in permanent teeth.[22] Similar outcomes for primary teeth based on controlled studies, however, have yet to be demonstrated.

Coronal pulpotomy is the most widely advocated treatment for exposed primary pulps because of its consistently reported higher success rates when compared with direct pulp capping.[23] In instances when the exposed pulp has been contaminated from extensive crown loss or treatment time intervals greater than 24 hours, complete pulpectomy or extraction may provide the best insurance against residual infection (**Figure 7**). The complete pulpectomy in primary teeth differs from conventional permanent tooth endodontics in that the canals must be obturated with a resorbable material such as zinc-oxide-eugenol, calcium hydroxide, or iodoform-containing pastes to facilitate the normal exfoliation process.

Crown-root fractures in primary teeth are best treated by extraction unless pulp therapy procedures can be implemented, protection against bacterial leakage achieved, and the tooth adequately restored. Traumas of a great enough magnitude to cause crown-root fractures usually produce luxation injuries as well, which further compromise vital and nonvital pulp therapy success (**Figure 8**).

Root fractures in primary teeth, particularly those occurring in the apical third of the root, can be monitored if there is no mobility. If there is mobility or if the fracture occurs in the coronal third of the root, extraction is the treatment of choice. When extracting teeth with apical root fracture, the clinician must evaluate the difficulty in gaining access to the apical fragment. Iatragenic trauma to the underlying permanent tooth must be avoided. In those instances where access is difficult, apical fragment removal should not be attempted[12] (**Figure 9**). These root portions can be expected to resorb as part of the normal exfoliation process.

Periodontal Trauma/Displacement Injury

The predominant treatment goal for luxated primary teeth focuses on protecting the periodontal ligament and pulp from bacterial infection. Avoidance of developmental damage to the underlying permanent tooth is the ultimate desired outcome. Because of the questionable ability to achieve this goal in most instances, extraction is the appropriate treatment

Subluxation in primary teeth has been found by Fried and Erickson to occur at a frequency of 66.2 percent with central incisors and 33.3 percent with lateral incisors.[4] They noted that 80.2 percent of the subluxated teeth in their sample did not require treatment.[4] This finding supports the monitoring of afflicted teeth on a regulated basis for the first year as opposed to immediately instituting invasive treatment. In instances of excessive mobility, short-term splinting of seven to 10 days using acid-etched resin attachment of a light orthodontic wire should be considered if the child's behavior is not a deterrent. If behavior is a major deterrent to accomplishing splinting techniques, and the clinician judges the tooth's mobility excessive enough to place it at risk for being lost with potential aspiration, the tooth should be extracted. Equilibrating opposing teeth to reduce repeated hyperocclusion trauma to the afflicted teeth can also enhance stabilization.

Extruded primary teeth can be repositioned in instances of minimal coronal displacement. Teeth with incisal displacement of greater than 2 mm should be extracted to avoid the elevated potential of persistent periradicular infection and subsequent adverse effects on the underlying permanent teeth (**Figure 10**).

Intruded primary teeth were found by Soporowski and colleagues to have the highest correlation with hypoplastic defects in underlying permanent tooth successors (17.4 percent) when compared with lateral luxation (7.1 percent) and avulsion (5.7 percent).[5] Repositioning intruded primary teeth resulted in less pulp necrosis than repositioning laterally luxated teeth.[5] The most prevalent treatment recommendation is to allow the intruded tooth to re-erupt, provided it is positioned facially away from the developing permanent tooth bud[12] (**Figure 11**). Re-eruption should occur within one to six months with incisal movement being evident in four weeks.[12] If incisal movement is not evident within this time or if the intruded primary tooth is displaced in a palatal direction toward the underlying permanent tooth, it should be extracted.[12] Intruded primary teeth that re-erupt should be monitored closely for signs of pulp degeneration that necessitate either a pulpectomy procedure or extraction.

Lateral luxation of primary teeth can be treated by repositioning and short-term splinting in cases of minimal horizontal displacement. For excessive tooth displacement accompanied by alveolar fracture, gingival laceration, and resistant behavior, extraction is the preferred treatment. Soporowski and colleagues noted that repositioning laterally luxated primary teeth was associated with an increased prevalence of pulp necrosis, which supports the extraction option5 (**Figure 12**).

Avulsion of primary teeth has been somewhat confounding with respect to treatment recommendations (**Figure 13**). There are specific guidelines for avulsed permanent teeth, which involve

Table 2.

Treatment of Primary Tooth Injuries

Fractures — Primary Teeth	
Injury	**Treatment**
Enamel fracture	Smooth or restore, and monitor
Enamel/dentin fracture	Seal, restore, and monitor
Complicated crown fracture	Pulpotomy (direct pulp cap?), restore and monitor
Crown/root fracture	Pulpotomy/pulpectomy and restore, or extract
Root fracture	Stabilize and monitor, or extract
Periodontal/Displacement Injury — Primary Teeth	
Injury	**Treatment**
Subluxation	Monitor or splint
Extrusion	Reposition and splint or extract
Intrusion	Allow re-eruption or extract
Lateral luxation	Reposition and splint or extract
Avulsion/exarticulation	Do not replant

elaborate protocols for replantation techniques.[24] The predominant opinion, however, is that primary teeth should not be replanted because of the elevated potential for chronic infection and subsequent dystrophic changes that could occur with the developing teeth.[2,12] The pragmatic issue of behavioral cooperation with splinting and subsequent nonvital pulp therapy is also a potential deterrent to a favorable outcome.

A number of case reports identify success in replanting avulsed primary teeth as long as principles of case selection criteria include teeth with an extraoral dry time of less than 30 minutes and periodontal ligament cell maintenance through an appropriate tooth storage medium. They describe primary tooth replantation success with short-term splinting, followed by pulp canal obturation with zinc-oxide-eugenol and calcium hydroxide medicaments.[25-27] However, until more controlled studies become available to confirm successful outcomes with replanting avulsed primary teeth, this technique is not recommended.

Summary

This article has reviewed the various primary tooth injuries associated with dental trauma. Protection of the pulp and the periodontal ligament from bacterial infection along with efforts to avoid any residual damage to underlying permanent tooth successors is the desired treatment objective. The types of primary tooth injuries along with recommended treatment are summarized in **Table 2**.

References

1. Fried I, Erickson P, Anterior tooth trauma in the primary dentition: Incidence, classification, treatment methods, and sequalae: A review of the literature. *J Dent* Child 62:256-61, 1995.
2. Wilson CFG, Management of trauma to primary and developing teeth. Dent Clin N Am 39:133-67, 1995.
3. Hargreaves JA, Sleaton-Jones PE, et al, Trauma to primary teeth of South African preschool children. Endod Dent Traumatol 15:73-6, 1999.
4. Fried I, Erickson P, et al, Subluxation injuries of maxillary primary anterior teeth: epidemiology and prognosis of 207 traumatized teeth. *Pediatr Dent* 18:145-51, 1996.
5. Soporowski NJ, Allred MS, Needleman HL, Luxation injuries of primary anterior teeth -- prognosis and related correlates. *Pediatr Dent* 16:96-101, 1994.
6. Galea H, An investigation of dental injuries treated in an acute care general hospital. *J Am Dent Assoc* 109:434-9, 1984.
7. Garcia-Godoy F, Garcia-Godoy F, Garcia-Godoy FM, Primary teeth traumatic injuries at a private pediatric dental center. Endod Dent Traumatol 3:126-9, 1987.
8. Borssen E, Holon A-K, Traumatic dental injuries in a cohort of 16-year-olds in northern Sweden. Endod Dent Traumatol 13:276-80, 1997.
9. Borum MK, Andreasen JO, Sequelae of trauma to primary maxillary incisors. I. Complications in the primary dentition. Endod Dent Traumatol 14:31-44, 1998.
10. Schatz JP, Joho JP. A retrospective study of dentoalveolar injuries. Endod Dent Traumatol 10:11-4, 1994.
11. von Arx T, Developmental disturbances of permanent teeth following trauma to the primary dentition. Aust Dent J 38:1-10, 1993.
12. Andreasen JO, Andreasen FM, Textbook and color atlas of traumatic injuries to the teeth, 3rd ed. Munksgaard, Copenhagen, 1994, pp 457-94.
13. Andreasen JO, Ravn JJ, The effect of traumatic injuries to primary teeth on their permanent successors. II. A clinical and radiographic follow-up study of 213 teeth. Scand *J Dent* Res 79:284-94, 1971.
14. Croll TP, Brooks EB, et al, Rapid neurologic assessment and initial management for the patient with traumatic dental injuries. *J Am Dent Assoc* 100:530-4,1980.
15. Schneider PE, Dental trauma and central nervous system injury. Quintessence Int 17:749-53, 1986.
16. Mouden LD, Bross DC, Legal issues affecting dentistry's role in preventing child abuse and neglect. *J Am Dent Assoc* 126:1173-80, 1995.
17. Soxman JA, Nazif MM, Bouquot J, Pulpal pathology in relation to discoloration of primary anterior teeth. *J Dent* Child 51:282-4, 1984.
18. Jeppsen K, Direct pulp capping on primary teeth -- a long-term investigation. J Int Assoc Dent Child 2:10, 1971.
19. Kopel HM, Considerations for the direct pulp capping procedure for primary teeth. *J Dent* Child 59:141-9, 1992.
20. AAPD Reference Manual, Guidelines for pulp therapy in primary and young permanent teeth. *Pediatr Dent* 21:62, 1999-00.
21. Ram D, Holan G, Partial pulpotomy in a traumatized primary incisor with pulp exposure: case report. *Pediatr Dent* 16:46, 1994.
22. Cvek M, A clinical report on partial pulpotomy and capping with calcium hydroxide in permanent incisors with complicated crown fracture. J Endod 4:232-7, 1978.
23. Matthewson RJ, Primosch RE, Fundamentals of pediatric dentistry, 3rd ed. Quintessence Publishing, Chicago, 1995, p 255.
24. Treatment of the Avulsed Permanent Tooth: Recommended Guidelines of the American Association of Endodontists. American Association of Endodontists, Chicago, 1995.
25. Kawashima Z, Pineda LFR, Replanting avulsed primary teeth. *J Am Dent Assoc* 123:90-1, 1992.
26. Filippi A, Pohl Y, Kirschner H, Replantation of avulsed primary anterior teeth: Treatment and limitations. *J Dent* Child 64:272-5, 1997.
27. Weiger R, Heuchert T, Management of an avulsed primary incisor. Endod Dent Traumatol 15:138-43, 1999.

To request a printed copy of this article, please contact/ Clifton O. Dummett, Jr., DDS, MSD, MEd, LSU Health Sciences Center, School of Dentistry, 1100 Florida Ave., New Orleans, LA 70119-2799 or at CDumme@lsusd.lsumc.edu.

CDA JOURNAL, VOL 28, Nº11

Decoronation: How, Why and When?

Barbro Malmgren

ABSTRACT Decoronation is a surgical method for treating ankylosed incisors in children and adolescents. The crown and the root filling are removed, leaving the root in situ to be resorbed and covered with a mucoperiosteal flap.[1] Early loss of a permanent tooth leads to loss of alveolar bone, especially in buccopalatal width:[2] Decoronation preserves not only the width of the ridge but also the vertical height.

AUTHOR

Barbro Malmgren is a senior consultant with responsibility for postgraduate training in pediatric dentistry at Eastmaninstitutet, Stockholm, Sweden.

Dental trauma is most common in children between 8 and 10 years old, during the early mixed dentition, a period of incomplete root development and dynamic jaw development. The most serious injuries are intrusion and avulsion, which damage both the pulp and the periodontal ligaments (**Figures 1a through c**).[3,4] In cases with complete root formation, extirpation of the pulp should be performed about two weeks after replantation and the root canal dressed with calcium hydroxide before permanent root filling. In cases of incomplete root formation, pulpal revascularization is possible and endodontic treatment should be postponed until signs of inflammatory root resorption are seen.

Replacement resorption or ankylosis is due to damage to the periodontal ligament and fusion of the alveolar bone and root substance, which is continuously resorbed and replaced by bone. The condition is progressive, eventually resorbing the entire root (**Figures 2a and b**). To date there is no means of arresting or reversing the condition.[5,6]

Providing no other changes supervene, the ankylosed tooth can be retained until the crown falls off or removed by forceps when most of the root substance has been replaced by bone. The rate of resorption seems to vary with age and skeletal growth rate of the patient.[7,8]

In children and adolescents, the ankylosis is accompanied by increasing relative infraposition of the tooth (**Figures 3a and b**).[9-10] A slight increase in infraposition has been observed even in young adults.11 In patients in their late teens with limited infraposition, the incisal edge can be built up in composite. Orthodontic extrusion is not a treatment

Figure 1a. Intrusion and avulsion cause damage to both the pulp and the periodontal ligaments. This figure shows intrusion of the maxillary right central incisor in the mixed dentition in a 10-year-old girl.

Figure 1b. Avulsion of the maxillary right central incisor in an 8-year-old boy.

Figure 1c. The avulsed tooth from 1B with an open apex.

option, as it results in intrusion of the adjacent teeth (**Figures 4a through e**).

If an ankylosed tooth is left in situ, infraposition will increase. Conditions may be further complicated by tilting of the adjacent teeth with subsequent space loss. A satisfactory outcome may be very difficult to achieve, even with prolonged orthodontic treatment (**Figure 5**). The ankylosed tooth should be removed in time to prevent these adverse effects on the outcome of orthodontic and/or prosthetic therapy.

The Decoronation Technique

Clinical experience shows that extraction of an ankylosed tooth may involve loss of attached bone, particularly the thin buccal plate of the maxilla (**Figures 6a and b**). The decoronation technique was developed to prevent such bone loss. The crown of ankylosed, infrapositioned incisors is removed, leaving the root in the alveolus, to be replaced by bone. In most cases an ankylosed tooth is endodontically treated. An existing root filling should be removed before the root is covered with a mucoperiosteal flap since endodontic sealers may cause irritation, and gutta percha filling would be an obstacle to complete bone healing.

A mucoperiosteal flap is raised and the crown is removed with a diamond bur under continuous saline irrigation. The root filling is removed with an endodontic file. The coronal part of the root surface

Figure 2a. Ankylosis due to damage to the periodontal ligament in both central incisors after avulsion and replantation in a young girl. Immediately after replantation at 12 years of age.

Figure 2b. After two years. Almost total resorption of the roots with replacement by bone.

Figure 3a. Progressive infraposition of an ankylosed incisor. A 12-year-old boy with his maxillary left central incisor in slight infraposition one year after diagnosis of ankylosis.

Figure 3c. Three years later, there is considerable increase in infraposition.

is reduced to 2 mm below the marginal bone. The empty root canal is thoroughly rinsed with saline and thereafter allowed to fill with blood. This is very important, as the blood clot is organized from the surrounding tissues. The mucoperiosteal flap is drawn over the alveolus and sutured with single sutures. A blood clot forms in the gap between the labial and palatal mucosa (**Figures 7a through k**).

Indications for Decoronation

When ankylosis is diagnosed, the following clinical guidelines may be applied:

- In the early mixed dentition (age 7 to 10 years): Decoronation within two years,
- In the late mixed dentition (age 10 to 12 years): Individual monitoring. If patients have reached the pubertal growth spurt, a rapid increase in infraposition can be expected. Decoronation is indicated at the time of infraocclusion
- In the early permanent dentition: The increase in infraposition is sometimes slow. Decoronation might not be necessary, but annual follow-up is important.[10]

Replacement of the Lost Crown After Decoronation in Growing Patients

Replacement of a lost crown in young patients in the mixed dentition may be complicated. During eruption of the canines there is an increase in transverse intercanine width, and the lateral incisors often change position due to apical pressure. Fixation of the replacement tooth to the adjacent teeth should therefore be postponed until the canines are fully erupted (**Figures 8a through d**).

The most common option for replacing the missing incisor is a removable acrylic partial denture, retained by Adam's or ball clasps. Poor retention during the mixed dentition is a disadvantage. It is also important to avoid interfering with eruption of teeth in the lateral segments.

An alternative therapy during the mixed dentition is a lingual arch wire soldered to bands on the second primary molars, with a denture tooth fixed to the arch wire. To avoid a midline shift, stops should be placed on both sides of the space. Occlusal stops are also necessary to avoid pressure by the prosthetic tooth on the alveolar ridge. It is preferable to use bands on the second primary molars to avoid interference with permanent molar eruption (**Figures 9a and b**). Thereafter, a similar appliance fixed to molar bands can be used.[9]

When the canines are fully erupted or when there is no risk of interference between the lateral incisor and the canine, a pontic can be bonded to the adjacent teeth. The crown removed from the ankylosed tooth may serve as a pontic, shaped with composite material and splinted to the adjacent teeth by the acid-etch technique (**Figures 10a through c**). As downgrowth of the mucosa over the alveolus and formation of new marginal bone over the retained root can be expected,1 it is important to leave a space between the pontic and the gingiva, rather than cover all the lost tissue (**Figures 11a through d**).

Development of the Alveolar Ridge

At the Department of Paediatric Dentistry of the Eastmaninstitutet in Stockholm, 77 teeth were decoronated during the period following publication of the first study in 19841 up to 1997. The age of the patients at the time of trauma varied between 6 and 18 years and the age at decoronation between 10 and 22 years. Radiographs were taken immediately before and after decoronation, after six months and then annually up to 14 years. In most cases, the radiographs showed normal alveolar bone. In a few cases, remnants of the root were still present at the end of the follow-up period but did not impede subsequent insertion of implants. In patients treated with decoronation before the age of 13 years, i.e., before or during pubertal growth periods, there was an increase in vertical bone level (**Figures 12a through d**). The buccopalatal width of the alveolar ridge was maintained into adulthood in all patients (**Figures 13a and b and 14a through d**).

Summary

Extraction of an ankylosed tooth may involve loss of attached bone. In young patients, an uncomplicated extraction also has unfavorable sequelae. Early loss of a permanent tooth leads to loss of alveolar bone, especially the buccopalatal width. These adverse effects are circumvented by the decoronation technique, which preserves not only the width but also the vertical height of the alveolar ridge. Above all, maintaining the width of the alveolar ridge allows optimal positioning of an implant and ideal esthetic shaping of the crown.

References

1. Malmgren B, Cvek M, et al, Surgical treatment of ankylosed and infrapositioned reimplanted incisors in adolescents. Scand *J Dent* Res 92(5):391-9, 1984.
2. Lam RV, Contour changes of the alveolar processes following extractions. J Prosthet Dent 10(1):25-32, 1960.
3. Andreasen JO, Hjörting-Hansen E, Replantation of teeth. I. Radiographic and clinical study of 110 human teeth replanted after accidental loss. Acta Odontol Scand 24(3):263-86, 1966.
4. Andreasen JO, Andreasen F, Textbook and Color Atlas of Traumatic Injuries to the Teeth. Munksgaard, Copenhagen, 1994, pp 366-70 .
5. Hammarström L, Blomlof L, Lindskog S, Dynamics of dentoalveolar ankylosis and associated root resorption. Endod Dent Traumatol 5(4):163-75, 1989.
6. Andreasen JO, Borum MK, et al, Replantation of 400 avulsed permanent incisors, 4. Factors related to periodontal ligament healing. Endod Dent Traumatol 11(2):76-89, 1995.
7. Andersson L, Bodin I, Sörensen S, Progression of root resorption following replantation of human teeth after

Figure 4a. An unsuccessful attempt to extrude an ankylosed tooth with a fixed orthodontic appliance. Fixed appliance with an extrusion force applied to the maxillary left central incisor. The tooth is in infraposition due to ankylosis.

Figure 4b. Six months later, there is intrusion of all adjacent teeth.

Figure 4c. Relapse after treatment. Despite a composite build-up, the outcome is a failure.

Figure 4d. Radiographs at the start of extrusion.

Figure 4e. Three years later. Note obliteration of the pulp of the lateral incisor due to the trauma. The resorption at the distal root surface was caused by ectopic eruption of the canine and subsequently healed.

Figure 5. Neglect of an ankylosed incisor, showing inhibited vertical growth of the alveolar ridge in the region of the ankylosed maxillary left central incisor and tilting of the adjacent teeth.

extended extra-oral storage. Endod Dent Traumatol 5(1):38-47, 1989.
8. Ebeleseder KA, Friehs S, et al, A study of replanted permanent teeth in different age groups. Endod Dent Traumatol 14(6):274-8, 1998.
9. Malmgren O, Malmgren B, Goldson L, Orthodontic management of the traumatized dentition. In, Andreasen JO, Andreasen FM, eds, Textbook and Color Atlas of Traumatic Injuries to the Teeth. Munksgaard, Copenhagen, 1994, pp 587-633.
10. Malmgren B, Malmgren O, Infraposition of reimplanted ankylosed incisors related to age and growth in children and adolescents. Endod Dent Traumatol in preparation, 2000.
11. Kawanami M, Andreasen JO, et al, Infraposition of ankylosed permanent maxillary incisors after replantation related to age and sex. Endod Dent Traumatol 15(2):50-6, 1999.
12. Andreasen JO, Andreasen F, Textbook and Color Atlas of Traumatic Injuries to the Teeth. Munksgaard, Copenhagen,1994, pp 383-425.

To request a printed copy of this article, please contact/ Barbro Malmgren, Department of Paediatric Dentistry, Eastmaninstitutet, Dalagatan 11, SE-113 24 Stockholm, SWEDEN, or at barbro.malmgren@telia.com.

Figure 6a. Extraction of an ankylosed tooth may cause severe bone loss. Ankylosis of the maxillary left central incisor.

Figure 6b. The extracted tooth, with attached bone.

Figure 7a. The decoronation technique. The ankylosed maxillary right central incisor.

Figure 7b. A mucoperiosteal flap is raised.

Figure 7c. The crown is removed with a diamond bur under continuous saline irrigation.

Figure 7d. The crown has been removed.

Figure 7e. The root filling is removed with an endodontic file.

Figure 7f. The coronal part of the root surface is reduced to 2 mm below the marginal bone.

Figure 7g. The empty root canal is thoroughly rinsed with saline and thereafter allowed to fill with blood.

Figure 7h. The mucoperiosteal flap is drawn over the alveolus and sutured with single sutures. A blood clot forms in the gap between the labial and palatal mucosa.

Figure 7i. The removed crown is shaped as a pontic with composite material and splinted to adjacent teeth.

Figure 7j. Before decoronation.

Figure 7k. Immediately after decoronation. (Figures 7A through K from Malmgren O, Malmgren B, Goldson L 19939).

Figure 8a. Change of position of lateral incisors during eruption of the canines. A 10-year-old boy. The lateral incisors are tipped slightly mesially.

Figure 8b. Two years later, the lateral incisors have changed position and are tipped distally due to eruption of the canines.

Figure 8c. Radiograph showing eruption of the right canine during the observation period.

Figure 8d. Another such radiograph.

Figure 9a. Fixed space maintainer in the early mixed dentition.

Figure 9b. Lingual archwire is soldered to bands on the primary second molars. Note the mesial and distal stops on the prosthetic tooth and also the occlusal stop (Figures 9A and B from Malmgren O, Malmgren B, Goldson L 19939).

Figure 10a. A removed crown shaped as a pontic and bonded to the adjacent teeth. Preparation of the pontic, lingual aspect.

Figure 10b. Pontic filled with composite, lingual aspect.

Figure 10c. Bonding to adjacent teeth. Rubber dam isolation of the field is essential.

Figure 11a. Clinical follow-up after decoronation. Downgrowth of the gingiva and formation of new marginal bone over the alveolus made it necessary to shorten the pontic one year after decoronation. At the time of decoronation.

Figure 11b. After one year, the pontic has been shortened.

Figure 11c. Radiographs immediately before and after decoronation.

Figure 11d. Radiographs six months and one year later.

Figure 12a. Development of the alveolar ridge over 13 years, after decoronation in a young girl. One year after trauma, at 9 years of age. Maxillary left central incisor ankylosed and in infraposition. Note build-up of the incisal edge.

Figure 12b. Three years later, immediately before decoronation.

Figure 12c. Immediately after decoronation. The adjacent teeth have been proclined during orthodontic treatment to prepare space for a temporary prosthesis.

Figure 12d. At the age of 21, there is an increase in vertical dimension of the marginal bone.

Figure 13a. Difference in buccopalatal width of alveolar ridge after normal extraction and decoronation. An 18-year-old patient with a concave alveolar ridge following uncomplicated conventional extraction at age 12.

Figure 13b. Patient from Figures 7 and 17, 10 years after decoronation. The alveolar ridge has a favorable width for an implant.

Figure 14a. Insertion of implant as a final solution in the same patient as in Figure 7. Insertion of implant 10 years after decoronation. A few root remnants were no impediment.

Figure 14b. Final solution.

Figure 14c. Radiograph at the time of insertion of implant.

Figure 14d. Five-year follow-up.

CDA JOURNAL, VOL 28, Nº11

Management of Traumatically Injured Pulps in Immature Teeth Using MTA

Leif K. Bakland, DDS

ABSTRACT Maintaining pulpal health during tooth development is an important goal in managing traumatic injuries in the immature dentition. The introduction of mineral trioxide aggregate has offered an improved method for pulp protection in such cases. This article describes a technique using MTA for vital pulp therapy on teeth with crown fractures that have resulted in pulp exposure.

AUTHOR

Leif K. Bakland, DDS, is a professor in and chair of the Department of Endodontics at Loma Linda University School of Dentistry. He is also the school's associate dean of advanced education..

Traumatic injuries to immature permanent teeth can have adverse effects on the entire dentition as well as on the individual teeth themselves. If pulp necrosis occurs in a tooth prior to complete root formation, the tooth may be lost due to subsequent fracture of the weak, underdeveloped root, resulting in a potential for orthodontic complications. Replacement of missing teeth in the developing dentition often presents complex treatment problems. The special concern for maintaining pulpal health during tooth development becomes an important goal in managing traumatic injuries in the immature dentition.[1]

Efforts to manage pulpal injuries have until recently primarily involved the use of calcium hydroxide.[2] Successful results have been predictable as long as the pulp could be protected from bacterial invasion, mostly resulting from microleakage associated with the temporary or definitive restorations used. Calcium hydroxide is an effective antibacterial agent,[3] but the effectiveness is limited because the material is neutralized by exposure to tissue fluids. After its pH value is reduced, it is no longer effective and bacteria can again grow in its presence. The use, however, of properly managed calcium hydroxide can provide an excellent service for an immature tooth with crown fracture. The technique has been described in many publications, including this journal.[4]

The introduction of a new dental material, mineral trioxide aggregate (Pro Root MTA, Tulsa Dental Products, Tulsa, Okla.), which has been investigated extensively for its ability to seal pathways of communication between the root canal system and the external tooth surface,[5,6] has offered an improved method for pulp protection.[7] MTA's advantages are

Figure 1A. Shallow pulpotomy using MTA. Pre-operative radiograph of maxillary right central incisor with traumatic pulp exposure, open apex, and no clinical symptoms.

Figure 1B. Shallow pulpotomy and capping the pulp with MTA.

Figure 1C. Twenty-eight-month postoperative radiograph showing closure of the apex of the tooth in Figure 1A and the left central incisor, which had a similar procedure 18 months prior to the taking of this radiograph (With permission, from Apaydin E, Handysides R, Odabashian N, MTA: A new endodontic material. LLU Dentistry, 11:16-9, 2000).

Figure 2A. Shallow pulpotomy followed by bonding of the fractured coronal crown segment in an 11-year-old boy. Pre-operative photo showing maxillary right central incisor with a horizontal fracture line in the cervical area (arrow). The palatal fracture line was subgingival making this case a crown-root fracture with pulp exposure. The coronal fragment was held in place by the palatal gingival attachment.

Figure 2B. Radiograph showing fracture line; note the large radicular pulp space indicating a less than fully formed root.

Figure 2C. Photo showing the tooth isolated with rubber dam, the coronal segment has been removed, and the MTA pulpotomy has been completed.

Figure 2D. Radiograph showing the tooth after the MTA pulptomy. After curing for six hours by exposure to saliva, the coronal fragment was bonded into place.

Figure 2E. Photograph after bonding the coronal segment to the remaining tooth.

Figure 2F. Radiograph showing the final result (Coronal bonding courtesy of Dr. Todd Milledge).

related to its ability to effectively seal the material-tooth interface to prevent bacterial penetration and to its high level of biocompatibility.[5] In contrast to calcium hydroxide, which deteriorates over time and gradually disintegrates, thereby leaving space for potential microleakage, MTA does not appear to change over time. Therefore, it preserves the protective cover over, for instance, developing reparative dentin,[7] preventing bacterial invasion of the pulp.

The technique for managing a traumatic pulp exposure using MTA is in many ways similar to that used with calcium hydroxide,[4] with some minor modifications as will be described for a tooth with crown fractures and pulpal exposure:

The tooth must be anesthetized and should be isolated with a rubber dam.

The tooth, fractured surface and wound area should be disinfected using a solution such as sodium hypochlorite.

A shallow pulpotomy is done to provide space for the MTA. A round diamond stone is used in a high speed handpiece with water irrigation to remove exposed pulp tissue to a depth of at least 2 mm into the pulp proper. Bleeding is allowed to stop (which usually takes two to three minutes) before MTA is placed directly onto the pulp wound. The presence of a small amount of blood in the wound area is not a contraindication to placing MTA; in fact, some moisture is required for the proper curing of the material.

Since access is not a problem when performing a shallow pulpotomy, the placement of MTA is not as difficult as it often can be when used for other purposes, such as repair of perforations. The mixture of MTA powder and liquid should be of a consistency that it can be carried from the mixing pad to the pulp wound using a dental instrument such as a spoon excavator. A small amount of MTA should be placed on the wound surface and gently tapped with a moist cotton pellet so that it covers the exposed pulp. Next, the entire access into the pulp should be filled in a similar manner using small amounts of MTA. Any excess moisture should be removed from the surface of the MTA using a dry cotton pellet.

The rubber dam can then be removed and the patient can be dismissed. Leaving the MTA exposed to saliva will allow it to cure. A minimum of six hours should be allowed for the material to adequately cure, but clinical experience indicates that waiting at least 24 hours is better. The tooth can then be restored with a definitive restoration.

Previous research[7,8] has shown that the pulp responds favorably to the protection provided by an MTA layer. The reparative dentin is consistently more uniform and thicker under MTA compared with calcium hydroxide. As has been convincingly demonstrated,[9] the pulp can tolerate almost any dental material and produce new dentin as long as it can be protected against microleakage, a function that MTA appears to perform better than any material with which it has been compared.

The differences in the vital pulp therapy technique when MTA is used in place of calcium hydroxide are important to consider.

First, it is not important that the pulp wound bleeding be completely stopped prior to placing the MTA; in fact, the presence of a small amount of blood provides necessary moisture for curing of the material and has been shown to work as well as any other fluid.[10]

Second, since the MTA needs to cure prior to placement of a definitive restoration, it is necessary to schedule two appointments for this procedure: the first to perform the shallow pulpotomy and place the MTA on the pulp wound, and the second to complete the restoration after the material has cured. Future material development may be expected to result in a faster-curing MTA.

Third, it is not necessary to re-enter the pulpotomy site later to remove the pulp capping material, as has been recommended for calcium hydroxide pulpotomies.[11] MTA does not appear to deteriorate and disintegrate with time, thus space for microleakage does not develop as it does with calcium hydroxide.

In sumary, a technique using mineral trioxide aggregate for vital pulp therapy has been described for teeth that have been subjected to traumatic crown fractures resulting in pulp exposure (**Figures 1 and 2**). The technique is similar to that used with calcium hydroxide[4] with some modifications. The recommended procedure is supported by evidence from animal research,[7,8] clinical experience[5] and extensive application in similar clinical situations in which pathways between a tooth's pulp and external surface need to be sealed.[6]

References

1. Andreasen FM, Andreasen JO, Crown fractures. In, Andreasen JO, Andreasen FM, Textbook and Color Atlas of Traumatic Injuries to the Teeth, 3rd ed. Munksgaard, Copenhagen, 1993, p 219-56.
2. Cvek M, A clinical report on partial pulpotomy and capping with calcium hydroxide in permanent incisors with complicated crown fractures. J Endodon 4:232-7, 1978.
3. Sjögren U, Figdor D, et al, The antimicrobial effect of calcium hydroxide as a short-term intracanal dressing. Int Endodon J 24:119-25, 1991.
4. Bakland LK, Milledge T, Nation W, Treatment of crown fractures. J Cal Dent Assoc 24(2):45-50, 1996.
5. Torabinejad M, Chivian N, Clinical application of mineral trioxide aggregate. J Endodon 2:197-205, 1999.
6. Abedi HR, Ingle JI, Mineral trioxide aggregate: a review of a new cement. J Cal Dent Assoc 23(12):36-9, 1995.
7. Pitt Ford TR, Torabinejad M, et al, Mineral trioxide aggregate as a pulp capping material. *J Am Dent Assoc* 127:1491-4, 1996.
8. Junn D, Assessment of dentin bridge formation following pulp capping with mineral trioxide aggregate. Master's thesis, Loma Linda University School of Dentistry, 2000.
9. Cox CF, Keall CL, et al, Biocompatibility of surface-sealed dental materials against exposed pulps. J Prosthet Dent 57:1-8, 1987.
10. Torabinejad M, Hong CU, Pitt Ford TR, Physical properties of a new root end filling material. J Endodon 21:349-53, 1995.
11. Cvek M, Endodontic management of traumatized teeth. In, Andreasen JO, Andreasen FM, Textbook and Color Atlas of Traumatic Injuries to the Teeth, 3rd ed. Munksgaard, Copenhagen, 1993, pp 517-86.

To request a printed copy of this article, please contact Leif K. Bakland, DDS, LLU School of Dentistry, Department of Endodontics, Loma Linda, CA 92350.

CDA JOURNAL, VOL 28, Nº11

Luxation Injuries and External Root Resorption – Etiology, Treatment, and Prognosis

Martin Trope, DMD

ABSTRACT When a tooth sustains a luxation injury, attachment damage of varying degrees will occur. In addition, necrosis of the pulp might result, thereby making the pulp space susceptible to infection. These circumstances can lead to root resorption. Treatment for root resorption includes preventing it by avoiding causes of root surface injury, minimizing initial inflammation, and reversing resorption.

AUTHOR

Martin Trope, DMD, is the chair and J.B. Freedland Professor of Endodontics at the University of North Carolina at Chapel Hill School of Dentistry.

When a tooth sustains a luxation injury, attachment damage of varying degrees will occur. In addition, necrosis of the pulp might result, thereby making the pulp space susceptible to infection.

Unlike root resorption in primary teeth, which occurs predictably when the permanent tooth erupts, resorption in permanent teeth will occur only under pathologic conditions. This fact appears to be due to the anti-resorptive properties of the precementum covering of the root that protects it in the presence of inflammation (**Figure 1**). However, if a luxation injury removes or alters the precementum, the inflammatory response will include root resorption with multinucleated clastic cells in addition to the "usual" bone resorption.

Thus, for root resorption to occur, two circumstances must exist: a change must have occurred to the protective attachment layer (precementum externally) of the root and an inflammatory process must be present adjacent to the damaged root surface.

Treatment strategies for root resorption include preventing it by recognizing the causes of the root surface injury and avoiding them; minimizing initial inflammation and thus the resorptive consequences by manipulating the inflammatory response; and reversing resorption by eliminating the inflammatory stimulator.

External Root Resorption Due to the Injury Alone

The luxation injury is the cause of the attachment damage. The byproducts of this mechanical damage stimulate the inflammatory response. The type of tissue that will cover the damaged root surface

depends upon the extent of the initial damage.

Localized Injury -- Cemental Healing

When the injury is localized (e.g., after concussion or subluxation), mechanical damage to the cementum occurs, which results in a local inflammatory response and a localized area of root resorption. If no further inflammatory stimulus is present, periodontal healing and root surface repair will occur within 14 days[1] (**Figure 2**). The resorption is localized to the area of mechanical damage, and treatment is not required since it is free of symptoms and not even visible radiographically in most cases. However, in a minority of cases, small radiolucencies can be seen on the root surface if the radiograph is taken at a specific angle. It is important not to misinterpret these cases as progressive in nature. Failure to isolate an inflammatory stimulus (e.g., a necrotic infected pulp space) is a clue that no treatment should be performed. A "wait and see" attitude should be taken to allow spontaneous healing to take place.

Diffuse Injury – Osseous Replacement

When the traumatic injury is severe (e.g., intrusive luxation or avulsion with extended dry time), involving diffuse damage on more than 20 percent of the root surface, an abnormal attachment can occur after healing.[2] The initial reaction as always is inflammation in response to the severe mechanical damage of the traumatic and concomitant injuries to the root surface. After the initial inflammatory response, the result is a diffuse area of root surface devoid of cementum. Cells in the vicinity of the denuded root compete to repopulate it, and often cells that are precursors of bone – rather than slower-moving periodontal ligament cells – will move across from the socket wall and populate the damaged root. Bone comes into contact with the root without an intermediate attachment apparatus. This phenomenon is termed dentoalveolar ankylosis.[3] Bone resorbs and forms physiologically throughout life. Thus, root is resorbed by osteoclasts; but, in the reforming stage, bone is laid down instead of dentin, thus the root is slowly replaced with bone. This process is termed osseous replacement (**Figure 3**). The initial inflammation to remove the mechanical debris of the traumatic injury is a pathologic response that in the author's opinion may be reversed. However, the ankylosis and osseous replacement that follows cannot be reversed and can be considered a physiologic process since bone resorbs and reforms throughout life. In these traumatic cases, however, the resorptive phase includes the root.

Treatment

Because osseous replacement is not localized to a particular area and occurs peri-radicularly, local treatment is impossible.

Treatment strategies are directed at avoiding or minimizing the initial inflammatory response. More specifically, these strategies comprise preventing the initial injury; minimizing additional damage after the initial injury; minimizing the initial inflammatory response; possibly stimulating cemental (rather than bone) healing; and slowing down the osseous replacement when inevitable.

Preventing the Initial Injury

Nothing can be done about the initial damage due to the primary traumatic injury. However, there is evidence that preventive measures can limit these injuries. In athletics, the mouthguard is a proven protective device against traumatic damage to the teeth.[4] Education should be used to increase mouthguard use by athletes of all levels.

Minimizing Additional Damage After Injury

Steps must be taken to minimize additional avoidable damage to the periodontal ligament after the initial injury has taken place.

The tooth should be repositioned into its original location as soon as possible and as atraumatically as possible.[5] If splinting is necessary, it should be performed with a functional (nonrigid) splint for seven to 10 days[6] (**Figure 4**).

In the case of avulsion, replanting the tooth as soon as possible is the preferable treatment. If the tooth cannot be replanted immediately, the extraoral dry time must be minimized by placing the tooth in an appropriate storage medium.[7] Milk is a practical storage medium.[8] It is found near most accident sites, is relatively free of bacteria, and has an osmolarity that is not excessively harmful to the periodontal ligament cells. Sterile saline or saliva (vestibule of the mouth) are practical alternatives.[8,9] Water is not an acceptable medium to store avulsed teeth.[8] Newer specialized media such as Hank's Balanced Salt Solution, which is a common culture medium, or ViaSpan, a liver transplant medium, might be able to sustain the viability of periodontal ligament cells for considerably longer periods than milk. Therefore, they might become practical for severe injuries where life-threatening situations do not allow immediate replantation.[9]

Limiting Initial Inflammatory Response

An additional approach to be considered is to pharmacologically manipulate the inflammatory response

to minimize destruction and facilitate repair of the damaged root surface by new cementum and periodontal ligament.

Tetracycline has been widely used in the treatment of periodontal disease because of its sustained antimicrobial effects. Tetracycline has been shown to possess anti-resorptive as well as its antimicrobial properties.[10] Specifically, it has a direct inhibitory effect resorbing osteoclast cells and collagenase.[10] Thus, if these drugs were found to be as effective as the penicillin drugs in limiting bacterial contamination after a traumatic injury and they possessed an anti-resorptive property in addition, they might replace penicillin as the systemic antibiotic of choice after these injuries.

The effectiveness of systemic tetracycline in an "infection" model in dogs has been tested, and the results were similar to those of penicillin.[10] In addition, when used in an osseous remodeling model, tetracycline was found to result in significantly more healing than penicillin, which in fact was not different from the control group.[11] The authors therefore recommend replacing systemic penicillin with tetracycline after a traumatic injury.

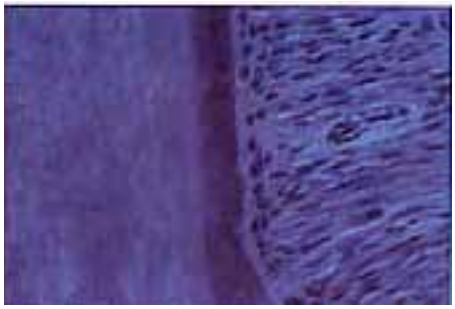

Figure 1a. The histologic appearance of periodontal ligament and adjacent dentin. The precementum has anti-resorptive properties.

Figure 2. The histologic appearance of a localized area of root resorption that has healed with new cementum and periodontal ligament. The initial damage was caused by a mild localized luxation injury.

Figure 3a. The histologic appearance of active osseous replacement. Bone attaches directly to the root without an intermediate periodontal ligament. Areas of active root resorption are seen in the bone and root.

Figure 3b. Radiographically, a mottled appearance of bone replacing root is seen.

Figure 4a. Physiologic splints can be made in a variety of ways. In this example, nylon fish line is bonded to multiple teeth with resin.

Figure 4b. A physiologic splint made of dead soft wire bonded with resin between permanent and primary teeth.

Figure 4c. A physiologic splint of resin between two teeth.

While tetracycline affects osteoclasts at the site of resorption, drugs are available that affect the recruitment of osteoclasts to the site of injury.[12] Thus the combination of the two types of drugs might have a synergistic effect on the inhibition of root resorption. Glucocorticoids have been widely used to reduce the deleterious effects of inflammatory responses. More specifically, they have been shown to reduce osteoclastic bone resorption by affecting cell recruitment by a plethora of mechanisms. Therefore, they could also potentially be useful in manipulating the initial inflammatory response after attachment damage. Thus, repair by cementoblasts rather than bone-derived cells would be encouraged. The effect of local and systemic dexamethasone in a dog model that has been shown to produce a peak of inflammatory root resorption has been tested. Topical dexamethasone was found to be useful, while systemic usage was not.[12] Other drugs such as bisphosphonates that appear to work locally and systemic NSAIDs are being tested and might offer beneficial results.

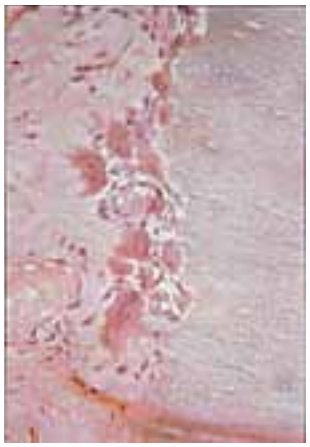

Figure 5a. External inflammatory root resorption of pulpal origin. The histologic appearance shows multinucleated giant cells resorbing the root surface.

Figure 5b. The radiographic appearance shows radiolucencies in the root and adjacent bone.

Figure 6a. Immature maxillary central incisors that have revascularized after replantation. A radiograph made at the time of replantation and splinting (courtesy Dr. Joe Camp).

Figure 6b. A radiograph made at 18 months showing continued development of the teeth (courtesy Dr. Joe Camp).

Figure 7a. A creamy mix of calcium hydroxide on a lentulo spiral. Calcium hydroxide powder mixed with sterile water to this consistency and placed into the canal with a lentulo spiral is the most effective way to use this medicament for its antibacterial action.

Figure 8a. A powdery mix of calcium hydroxide placed into the canal orifice with an amalgam carrier.

Figure 8b. Calcium hydroxide packed incrementally to fill the canal in an apical-coronal direction.

Figure 9a. A "Pink spot" of external inflammatory root resorption. The granulomatous tissue has spread coronally and undermined the enamel resulting in the pink color in the crown (courtesy Dr. Hank Rankow).

Figure 9b. Careful removal of the granulomatous tissue shows the canal to be almost entirely encircled by the resorptive defect but not penetrated (courtesy Dr. Hank Rankow).

Figure 10a. Variable radiographic appearance of subepithelial inflammatory root resorption. The resorptive defect on the mesial of the first molar shows a small opening into the root, expansion apically and coronally reaching but not penetrating the pulp canal. Note the adjacent bone resorption.

Figure 10b. The resorption is buccal or lingual on both mandibular premolar teeth. The appearance of the resorption extends coronally and apically. Note that the outline of the canal can be distinguished through the resorptive defect.

Stimulating Cemental Healing

If it were possible to stimulate periodontal cell growth, it might be possible to limit the number of osseous cells able to attach to the denuded root surface and thus decrease osseous replacement and slow down the loss of the tooth. Fibroblast-like cells in culture secrete factors that have been shown to have significant activity in tissue repair processes. It was hypothesized that the supernatant of cultured gingival fibroblasts, if used as a storage medium, might contain a number of biologically active factors that might promote periodontal ligament regeneration and repair. This "conditioned medium" was tested as a storage medium in dogs' teeth for extended periods. The results were extremely promising, as the "conditioned medium" appeared superior to Hanks' Balanced Salt Solution and Viaspan after 96-hour storage.[13] However, when tested as a periodontal-ligament-stimulating medium on roots with various extended dry periods, the results were disappointing in that Viaspan was the only medium with a beneficial result.[14] Therefore, work needs to continue to promote periodontal ligament stimulation after a traumatic injury. Specialized media such as Emdogain might prove beneficial in the future.

Slowing Down Osseous Replacement

When osseous replacement is thought to be unavoidable, such as in avulsion with extensive extraoral dry times or in a serious intrusive luxation injury, the root should be prepared to be as resistant to resorption as possible in an attempt to slow the process. Teeth should be soaked in citric acid for five minutes to remove all remaining periodontal ligament cells, soaked in 2 percent stannous fluoride for five minutes, and replanted.[15] If the tooth has been dry for more than 60 minutes and no consideration is given to preserving the periodontal ligament, the endodontics could be performed extraorally. In the case of a tooth with a closed apex, there is no advantage to performing this additional step at the emergency visit. However, in a tooth with an open apex, the endodontic treatment, if performed after replantation, involves a long-term apexification procedure. In these cases, completing the root canal treatment extraorally, where a seal in the blunderbus apex is easier to achieve, may be advantageous. When endodontic treatment is performed extraorally, it must be performed aseptically with the utmost care to achieve a root canal system that is free of bacteria.

External Root Resorption With Luxation Injury and Inflammatory Response

Pulp Space Infection

This usually occurs after a fairly serious injury resulting in areas of cemental covering of the root being damaged and its protective quality lost. If the pulp is necrotic and infected (usually from the same injury), the bacterial toxins can pass through the dentinal tubules and stimulate an inflammatory response in the corresponding periodontal ligament.[16] The result is resorption of the root and bone. The periodontal infiltrate consists of granulation tissue with lymphocytes, plasma cells, and polymorphonuclear leukocytes. Multinucleated giant cells

resorb the denuded root surface and this continues until the stimulus (pulp-space bacteria) is removed[17] (**Figure 5a**). Radiographically, the resorption is observed as progressive radiolucent areas of the root and adjacent bone (**Figure 5b**). Root canal disinfection removes the stimulus to the periradicular inflammation so the resorption will stop.[1] In most cases, a new attachment will form; but if a large area of root is affected, osseous replacement can result by the mechanism already described.

Treatment

The practitioner's attention to pulp space infection should ideally be seven to 10 days after the injury.[19,20] Again, treatment principles include prevention of pulp space infection or elimination of bacteria if they are present in the pulp space.

Prevention of Pulp Space Infection

- Maintain the vitality of the pulp – If the pulp stays vital, the canal will be free of bacteria. In severe injuries where vitality has been lost, it is possible under some circumstances to promote revascularization of the pulp. Revascularization is possible in young teeth with incompletely formed apices if replaced in their original position within 60 minutes[18] (**Figure 6**). If the tooth has been avulsed, soaking it in doxycycline for five minutes before replantation has been shown to double the revascularization rate.[18]
- Prevent root canal infection by root canal treatment at seven to 10 days – In teeth with closed apices, revascularization cannot occur. These teeth should be endodontically treated within seven to 10 days of the injury before the ischemically necrosed pulp becomes infected.[19,20] In this early stage, chemomechanical preparation and a short-term (at least seven days) intracanal dressing with a creamy mix of calcium hydroxide can sufficiently disinfect the root canal system[19] (**Figure 7**). Notwithstanding, in a compliant patient, the calcium hydroxide can be applied for a long term (up to six months) to ensure periodontal health prior to root canal filling with gutta-percha[20] (**Figure 8**).

Eliminate Pulp Space Infection

When root canal treatment is initiated later than 10 days after the accident or if active resorption is observed, the preferred antibacterial protocol consists of chemomechanical preparation followed by long-term dressing with densely packed calcium hydroxide.[20] Calcium hydroxide can affect an alkaline pH in the surrounding dentinal tubules, kill bacteria, and neutralize endotoxin, a potent inflammatory stimulator. Long-term application of calcium hydroxide is particularly beneficial in serious dental injuries with extensive areas of cemental damage that allow intracanal bacteria to interact with the attachment apparatus.

Sulcular Infection

This progressive root resorption of inflammatory origin occurs immediately below the epithelial attachment of the tooth, usually but not exclusively at the cervical area of the tooth. Its exact pathogenesis is not fully understood.[17] However, since its histological appearance and progressive nature is identical to other forms of progressive inflammatory root resorption, it appears logical that the pathogenesis would be the same (i.e., an unprotected or altered root surface attracting resorbing cells and an inflammatory response maintained by infection). Causes of the root damage immediately below the epithelial attachment of the root include orthodontic tooth movement, trauma, nonvital bleaching, and other less definable causes. The pulp plays no role in cervical root resorption and is mostly normal in these cases.[17] Because the source of stimulation (infection) is not the pulp, it has been postulated that it is the bacteria in the sulcus of the tooth that stimulate and sustain an inflammatory response in the periodontium at the attachment level of the root.[17]

Resorption of this type is asymptomatic and usually detected only through routine radiographs. Occasionally symptoms of pulpitis will develop if the resorption is extensive. When the resorption is long-standing, the granulation tissue can be seen undermining the enamel of the crown, resulting in a pinkish appearance. This "pink spot" has traditionally been used to describe the pathognomonic clinical picture of internal root resorption, resulting in many cervical root resorption cases being misdiagnosed and treated as internal root resorption (**Figure 9**).

The radiographic appearance of subepithelial inflammatory root resorption can be quite variable. If the resorptive process occurs mesially or distally on the root surface, it is common to see a small radiolucent opening into the root. The radiolucency expands coronally and apically in the dentin and reaches, but usually does not perforate, the root canal (**Figure 10a**). If the resorptive process is buccal or palatal-lingual, the radiographic picture depends upon the extent to which the resorptive process has spread in the dentin. It can be seen as a radiolucency at the attachment level or have spread a considerable way coronally or apically with a mottled appearance (**Figure 10b**). Because the pulp is not involved, its outline can usually be distinguished through the resorptive defect (**Figure 10b**).

Treatment

Unlike the treatment of external root resorption where the focus is on eliminating the cause of the inflammatory stimulus, i.e., pulpal bacteria, the long-term removal of sulcular bacteria is not possible. The treatment strategy for this type of resorption is to remove the resorptive tissue from the root (and surrounding bone) and change the root surface to be less susceptible to further resorption. Treatment is much more difficult than in pulp space root resorption, and therefore the results are less predictable. For a review of treatment strategies see Trope M, Subattachment inflammatory root resorption: Treatment strategies. J Pract Periodont Aesthet Dent 10(8): 1005-10, 1998.

References

1. Hammarstrom L, Lindskog S, General morphologic aspects of resorption of teeth and alveolar bone. Int Endod J 18:93-108, 1985.
2. Lindskog A, Pierce AM, et al, The role of the necrotic periodontal membrane in cementum resorption and ankylosis. Endod Dent Traumatol 1:96-101, 1985.
3. Hammarstrom L, et al, Tooth avulsion and replantation: A review. Endod Dent Traumatol 2:1-8, 1986
4. Sigurdsson A, LaBella C, Dental trauma in college basketball players as assessed with an interactive Internet web site. XI World Congress on Dental Trauma, Oslo, Norway, Abstract # 33.
5. Andreasen JO, The effect of extra-alveolar period and storage media upon periodontal and pulpal healing after replantation of mature permanent incisors in monkeys. Int J Oral Surg 10:43-53, 1981.
6. Andersson L, Friskopp J, and Blomlof L, Fiber-glass splinting of traumatized teeth. ASDC *J Dent* Child 1:21-4, 1983.
7. Hiltz J, Trope M, Vitality of human lip fibroblasts in milk, Hanks Balanced Salt Solution and Viaspan storage media. Endod Dent Traumatol 7:69-72, 1991.
8. Blomlof L, Milk and saliva as possible storage media for traumatically exarticulated teeth prior to replantation. Swed Dent J Suppl 8:1-26, 1981.
9. Trope M, Friedman S, Periodontal healing of replanted dog teeth stored in Viaspan, milk and Hanks Balanced Salt Solution. Endod Dent Traumatol 8:183-8, 1992.
10. Sae-Lim V, Wang C-Y, Trope M, Effect of systemic tetracycline and amoxicillin on inflammatory root resorption of replanted dogs' teeth. Endod Dent Traumatol 14:216-20,1998.
11. Sae- Lim V, Wang C-Y, et al, The effect of systemic tetracycline on resorption of dried replanted dogs' teeth. Endod Dent Traumatol 14:127-32, 1998.
12. Sae-Lim V, Metzger Z, Trope M, Local dexamethasone improves periodontal healing of replanted dogs' teeth. Endod Dent Traumatol 14: 232-6, 1998.
13. Hupp JG, Trope M, et al, Tritiated thymidine uptake in periodontal ligament cells of dogs' teeth stored in various media for extended time periods. Endod Dent Traumatol 13:223-7,1997.
14. Pettiette M, Hupp J, et al, Periodontal healing of extracted dog teeth air dried for extended periods and soaked in various media. Endod Dent Traumatol 13:113-8,1997.
15. Bjorvatn K, Selvig KA, and Klinge B, Effect of tetracycline and SnF2 on root resorption in replanted incisors in dogs. Scand *J Dent* Res 97:477-82, 1989.
16. Andreasen JO, Periodontal healing after replantation of traumatically avulsed human teeth: Assessment by mobility testing and radiography. Acta Odontol Scand 33:325, 1975.
17. Tronstad L, Root resorption -- etiology, terminology and clinical manifestations, Endod Dent Traumatol 4:241-52, 1988.
18. Cvek M, Cleaton-Jones P, et al, Effect of topical application of doxycycline on pulp revascularization and periodontal healing in reimplanted monkey incisors. Endod Dent Traumatol 6:170-6,1990.
19. Trope M, et al: Effect of different endodontic treatment protocols on periodontal repair and root resorption of replanted dog teeth, J Endod 18:492-6, 1992.
20. Trope M, Moshonov J, et al: Short versus long term Ca(OH)2 treatment of established inflammatory root resorption in replanted dog teeth. Endodon Dent Traumatol 11:124-8, 1995.

To request a printed copy of this article, please contact: Martin Trope, DMD, Department of Endodontics, School of Dentistry, UNC Chapel Hill, Chapel Hill, NC 27599-7450 or at Martin_Trope@dentistry.unc.edu.

CDA JOURNAL, VOL 28, Nº11

The Best Health News You've Heard All Year

Robert E. Horseman, DDS

The news coming out of Japan is not always good. For example, the entire Pokemon phenomenon was something any thinking adult could have well done without. Then there was that time when Datsun became Nissan overnight. What was that all about? Although the confusion wasn't quite the equal of General Motors one day renaming itself R.J. Reynolds & Co., it left a lingering suspicion that the country was up to no good and that we, as a nation, should be on the alert for any sign of pachinko parlors infiltrating our neighborhoods.

It comes as a pleasant surprise then, to learn that Japanese researchers have discovered that the husk of the cocoa bean can fight tooth decay. Yes! We recall that these same researchers told us something similar once about sushi being good for cardiovascular problems. The problem with that announcement was that nobody in his right mind wanted to actually eat raw fish in order to find out, when -- for less money -- he could have a cheeseburger with grilled onions.

Customer: "Waiter! What is this stuff?"

Waiter: "It's sushi, sir."

Customer: "Well, it looks like raw fish!"

Waiter: "Sushi is a Japanese word meaning literally, 'a formerly alive fish that we hope has not yet undergone degenerative necrosis.' There is, of course, an extra charge for not cooking it."

Customer: "Can I have another look at the menu?"

Upon close examination, the cocoa bean turns out to be the source of chocolate and that is something we can get our teeth into. It is a seed of such essential nobility that if the cacao tree were to disappear, civilization as we know it would cease to be.

The exact mechanism by which cocoa bean husks can help prevent tooth decay is not quite clear, but the American Chemical Society informs us that chocolate contains about 600 identifiable chemicals. At least one of those chemicals could very well have a salutary effect on teeth, so we are allying ourselves with Nippon until other researchers point out the fallacy of believing that anything that tastes good can be good for you.

Based on our current consumption of chemically altered foods that FDA watchdogs assure us are nutritionally sound, the liberation of chocolate from the list of no-no confections can come as the beginning of a great new trend. What scientific breakthroughs can we expect in the near future?

- Smoking Protects Your Teeth! – A protective layer of tar inhibits the action of lactic acid on teeth. Even small children who chew on chunks of roofing tar whenever they can find them instinctively know this. First-hand smoke effectively discourages French kissing, a practice that can lead to a host of other problems. True, smoking is bad for your heart and lungs, but it does give you beige or brown teeth that fashion forecasters claim is the coming backlash against too much whitening hype.
- Sitting Immobile on a Couch Benefits Your Knees! – There is no denying that knee injuries are so common as a result of the fitness craze that has seized this country, that the word "arthroscopy" appears in crossword puzzles 37 percent more this year than at any time previously. In addition, scientists have determined that at birth each of us is allotted a finite number of heartbeats. Exercising vigorously is the same as voluntarily spending yourself into bankruptcy.
- Popcorn Reverses the Aging Process! – Popcorn husks, those annoying golden bits that defy eradication from oral crevices, contain minute amounts of Oil of Olay. Absorbed internally, the results are the same as applying the substance directly to crow's feet; it just takes longer.
- Fried Foods Boost Intelligence! – Colonel Sanders is a prime example. Not only does he make more money than the rest of us, he can wear a white suit all winter and nobody says anything. The only exception is fried zucchini. Studies show that if you have so much zucchini left over from your gardening efforts that you have to resort to frying it, you weren't too smart to begin with.
- Cell Phones Cure Inner Ear Infections! – The radiation emanating from cell phones is similar to that coming from computer and TV screens. It is a well-known fact that the invisible rays from these sources have a calming effect on the central nervous system exactly like that of single malt whiskies. The beneficial effects of cell phone radiation accrue best to the ears of those drivers who have nothing between them to hinder ray transmission.
- Sleep Is a Complete Waste of Time! – The brain requires no rest, otherwise there would be no such thing as dreams. The bodies of modern humans require little, if any, rest because of lifestyles that consist primarily of sitting. Sleep is the result of boredom, and boredom is the result of not having enough to worry about. People who do not worry are in denial and should seek professional help. They should worry about that, and the need for sleep will be obviated.
- Obesity Is Normal! – Studies indicate that 65 percent of Americans are overweight. This is nature's way of preparing us for what lies ahead. Famine, pestilence and the very real chance of being chosen to participate in a "Survivor"-type TV show are good reasons for the morbidly slender 35 percent of the population to start immediately shoveling in the groceries. These provisions should include ample supplies of chocolate, because Japanese research confirms the fact that the 600 chemicals therein are better for you than rat-on-a-stick.

The point is, with chocolate now joining eggs (once a major health threat) and saccharin (the same) on the list of foods that are now OK, consumers seem to be justified in watching health news carefully. "They" (the mysterious entities that dictate these turnarounds) are bound to declare that whatever it is that's on the no-no roster today, could be the best thing since sliced bread tomorrow.