

# JOURNAL


OF THE CALIFORNIA DENTAL ASSOCIATION

OCTOBER 2013

Supernumerary Teeth

Gingival Leukoplakia

Coronoid Hyperplasia



INTERIM  
THERAPEUTIC  
RESTORATIONS  
IN THE VIRTUAL  
DENTAL HOME



**You are not a policy number.**



And at The Dentists Insurance Company, we won't treat you like one because we are not like other insurance companies. We were started by, and only protect, dentists. A singular focus that leads to an unparalleled knowledge of your profession and how to best protect you. It also means that TDIC is in your corner, because with us, you're never a policy number. You are a dentist.

**Protecting dentists. It's all we do.®**

800.733.0633 | [tdicsolutions.com](http://tdicsolutions.com) | CA Insurance Lic. #0652783

## DEPARTMENTS

- 729** The Editor/ *Color TVs and Prepaid Dental Benefit Plans*
- 731** Letters
- 735** Impressions
- 743** CDA Presents
- 771** Tech Trends
- 775** Classifieds
- 788** Advertiser Index
- 790** Dr. Bob/*United We Debate*



**735**

## FEATURES

### **744** MANAGING CARIES IN VIRTUAL DENTAL HOMES USING INTERIM THERAPEUTIC RESTORATIONS

*This paper reviews the scientific basis for the ITR, as used in the VDH system, in managing caries lesions and delivering oral health care to underserved and vulnerable populations.*

Paul Glassman, DDS, MA, MBA; Paul Subar, DDS, EdD; and Alan W. Budenz, MS, DDS, MBA

### **753** BILATERAL IMPACTED INVERTED MESIODENS ASSOCIATED WITH DENTIGEROUS CYST

*This article presents a case of a dentigerous cyst associated with a nonsyndromic bilateral impacted inverted supernumerary tooth in a 13-year-old boy.*

Aditi Amit Byatnal, BDS; Amit Byatnal, MDS; Ankur Singh, MDS; Venkadasalapathi Narayanaswamy, MDS; and Raghu Radhakrishnan, MDS, PhD

### **759** LESION CHARACTERISTICS AND RESPONSES AFTER CO<sub>2</sub> LASER VAPORIZATION IN FIVE PATIENTS WITH GINGIVAL LEUKOPLAKIA

*This paper presents a series of five patients with gingival leukoplakia who were treated with carbon dioxide laser vaporization.*

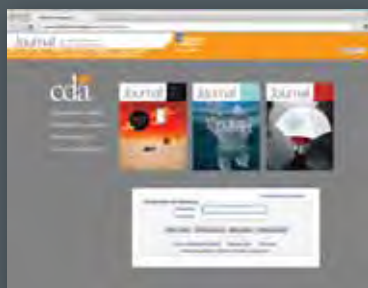Nita Chainani-Wu, DMD, MS, PhD, and Sol Silverman Jr., MA, DDS

### **766** CORONOID HYPERPLASIA IN A PEDIATRIC PATIENT: CASE REPORT AND REVIEW OF THE LITERATURE

*A case of coronoid hyperplasia in a pediatric patient with restriction in mandibular movements and an absence of painful symptoms initially misdiagnosed as a functional temporomandibular joint abnormality is presented.*

Robert A. Utsman, DDS; Gary D. Klasser, DMD; and Mariella Padilla, DDS, MS

# Submitting a manuscript to the Journal? There's a site for that.



In fact, from letters to the editor to reviews, the new site is now the only way to submit anything to the *Journal of the California Dental Association*. Upload your content, receive automatic status updates, even track progress anytime day or night. See for yourself at [editorialmanager.com/jcaldentassoc](http://editorialmanager.com/jcaldentassoc)



## Journal of the California Dental Association

published by the  
California Dental  
Association  
1201 K St., 14th Floor  
Sacramento, CA 95814  
800.232.7645  
[cda.org](http://cda.org)

**Management/Editorial**  
Kerry K. Carney, DDS, CDE  
EDITOR-IN-CHIEF  
[Kerry.Carney@cda.org](mailto:Kerry.Carney@cda.org)

Ruchi K. Sahota, DDS, CDE  
ASSOCIATE EDITOR

Brian K. Shue, DDS, CDE  
ASSOCIATE EDITOR

Peter A. DuBois  
EXECUTIVE DIRECTOR

Jennifer George  
CHIEF MARKETING OFFICER

Cathy Mudge  
VICE PRESIDENT,  
COMMUNITY AFFAIRS

Alicia Malaby  
COMMUNICATIONS  
DIRECTOR

Andrea LaMattina  
PUBLICATIONS SPECIALIST

Robert E. Horseman, DDS  
CONTRIBUTING EDITOR

Blake Ellington  
STAFF WRITER

Courtney Grant  
COMMUNICATIONS  
SPECIALIST

Jack F. Conley, DDS  
EDITOR EMERITUS

# Journal

OF THE CALIFORNIA DENTAL ASSOCIATION

Stay Connected  
Visit [cda.org](http://cda.org)



CDA Journal  
Volume 41, Number 10  
[cda.org/journal](http://cda.org/journal)  
OCTOBER 2013

## Reader Guide:

### Upcoming Topics

NOVEMBER: *Student Issue*  
DECEMBER: *Future of Dental  
Delivery Financing*  
JANUARY: *Dental/Medical  
Collaboration*

**Classified Advertising**  
[cda.org/classifieds](http://cda.org/classifieds)

### Display Advertising

Corey Gerhard  
ADVERTISING MANAGER  
[Corey.Gerhard@cda.org](mailto:Corey.Gerhard@cda.org)  
916.554.5304

### Letters to the Editor

[www.editorialmanager.com/  
jcaldentassoc](http://www.editorialmanager.com/jcaldentassoc)

### Permission and Reprints

Andrea LaMattina  
PUBLICATIONS SPECIALIST  
[Andrea.LaMattina@cda.org](mailto:Andrea.LaMattina@cda.org)  
916.554.5950

### Manuscript Submissions

[www.editorialmanager.com/  
jcaldentassoc](http://www.editorialmanager.com/jcaldentassoc)

### Subscriptions

Subscriptions are available only to active members of the Association. The subscription rate is \$18 and is included in membership dues. Nonmembers can view the publication online at [cda.org/journal](http://cda.org/journal).

### Change of Address

Manage your subscription online: go to [cda.org](http://cda.org), log in and update any changes to your mailing information. Email questions or other changes to membership@[cda.org](mailto:cda.org).

### Advertising

Corey Gerhard  
ADVERTISING MANAGER

Jenaé Gruchow  
PROJECT/TRAFFIC  
ADMINISTRATOR

Erin Jernigan  
ASSISTANT COORDINATOR

### Production

Val B. Mina  
SENIOR GRAPHIC  
DESIGNER

Randi Taylor  
SENIOR GRAPHIC  
DESIGNER

Ann Davis  
GRAPHIC DESIGNER/  
PRODUCTION ARTIST

### California Dental Association

Lindsey A. Robinson, DDS  
PRESIDENT  
[president@cda.org](mailto:president@cda.org)

James D. Stephens, DDS  
PRESIDENT-ELECT  
[presidentelect@cda.org](mailto:presidentelect@cda.org)

Walter G. Weber, DDS  
VICE PRESIDENT  
[vicepresident@cda.org](mailto:vicepresident@cda.org)

Kenneth G. Wallis, DDS  
SECRETARY  
[secretary@cda.org](mailto:secretary@cda.org)

Clelan G. Ehrler, DDS  
TREASURER  
[treasurer@cda.org](mailto:treasurer@cda.org)

Alan L. Felsenfeld, DDS  
SPEAKER OF THE HOUSE  
[speaker@cda.org](mailto:speaker@cda.org)

Daniel G. Davidson, DMD  
IMMEDIATE PAST  
PRESIDENT  
[pastpresident@cda.org](mailto:pastpresident@cda.org)

*Journal of the California Dental Association* (ISSN 1043-2256) is published monthly by the California Dental Association, 1201 K St., 16th Floor, Sacramento, CA 95814, 916-554-5950. Periodicals postage paid at Sacramento, Calif. Postmaster: Send address changes to *Journal of the California Dental Association*, P.O. Box 13749, Sacramento, CA 95853.

*The Journal of the California Dental Association* is published under the supervision of CDA's editorial staff. Neither the editorial staff, the editor, nor the association are responsible for any expression of opinion or statement of fact, all of which are published solely on the authority of the author whose name is indicated. The association reserves the right to illustrate, reduce, revise or reject any manuscript submitted. Articles are considered for publication on condition that they are contributed solely to the *Journal*.

Copyright 2013 by the California Dental Association.



## Color TVs and Prepaid Dental Benefit Plans

KERRY K. CARNEY, DDS, CDE

**W**hat do color televisions and prepaid dental benefit plans have in common? The FCC authorized RCA's color transmission system in 1953. Westinghouse produced the first color TV available to the public in 1954. The price tag was more than \$1,200. Its introduction revolutionized the industry and sparked a perception change: there would be a new normal. Consumers would come to expect a different kind of television experience.

In 1953, the International Longshoremen's and Warehousemen's Union and the Pacific Maritime Association (ILWU-PMA) Welfare Fund found it had accumulated a surplus of more than \$750,000.<sup>1</sup>

The ILWU-PMA Welfare Fund manager, Goldie Krantz, was determined that the ILWU-PMA use those funds to provide dental care for the members' children. On Feb. 8, 1954, she successfully lobbied the ILWU-PMA delegates to dedicate that sum to procuring dental benefits for the members' children.

This was an unprecedented undertaking. There were no prepaid dental benefit companies in the nation at the time. The idea that dentistry could have any kind of benefit plan seemed impossible to most everyone. Expensive restorative care and pre-existing conditions did not fit the medical insurance models of the time. The closed panel clinic was the prevalent model for providing dental care as an employment benefit and it was not acceptable to most dentists in private practice.



**The idea that dentistry could have any kind of benefit plan seemed impossible to most everyone.**

Goldie Krantz and her colleagues went to the leadership of organized dentistry in the states of California, Oregon and Washington to make their offer. By some accounts, it was a shotgun wedding. The encounter was somewhat confrontational: "Either you make it work or we will build clinics and hire our own dentists."

It did not take long for the state organizations to realize the importance of their role in establishing prepaid dental plans. Closed panel clinics threatened the future of private practice dentistry. If organized dentistry did not design and facilitate operation of the benefit programs, someone else surely would, and that someone might not care about the continued sustainability of private practice dentistry.

In 1955, two separate dental associations represented the dentists in Northern and Southern California. The California State Dental Association (CSDA) represented the dentists in Northern California. (The name was changed in 1961 to the California Dental Association.) The Southern California State Dental Association represented dentists in Southern California until the two organizations unified in 1973.

Though California was the first state dental association approached by the

union representatives, Washington state was the first to respond by setting up a nonprofit health care service corporation. Oregon and California followed with their service corporations shortly thereafter.

The California State Dental Association House of Delegates passed actions in April 1954 and April 1955 empowering the board to engage in the dental benefits arena and establish a service corporation. The association's attorneys drew up the Articles of Incorporation for the California Dental Association Service (CDAS) in May 1955. The CDAS would undergo several name changes including shortening to California Dental Service (CDS). In the 1980s, CDS changed its name to Delta Dental of California.

So began prepaid dental plans in the United States.

1953 was 60 years ago. It was a different world then, but some things remain the same today. There was tremendous discord within organized dentistry around what role it should play in setting up and administering dental benefit programs. The Southern California State Dental Association (SCSDA) did not support participation in the California Dental Service until 1961.

Dental association leaders were initially responsible for trying to get the



plan going under the aegis of the service corporation. The Dental Care Committee, formed by the California State Dental Association in 1954, continued to work with CDS to address the growing demand for dental benefit programs.

In 1956, F. Gene Dixon, DDS, was asked to take over the ILWU program. He became the first executive director (at the time, the title was vice president and managing director).

Dixon was a CDA member with a private practice in San Mateo, Calif. He had experience consulting for Blue Shield and had set up the San Mateo dental care program. He began by working one and a half days a week with one staff person at the California Dental Association headquarters in San Francisco. He continued to work in his private practice for many years.

Dixon envisioned the dental association as the policy-setting body and the service corporation as the instrument to realize that policy. He warned that, "... in all cases, even though the responsibility of the two are different, the purposes must remain the same, and we warn against the association and the corporation drifting too far apart, for if they do, then the corporation becomes just another insurance company."<sup>2</sup>

At the outset, there was a lot of experimentation. Enrollment fees, dedicated hourly assessments for union members, fee schedules for dentists, UCRs, hold backs, administration fees — they were trying everything. A large part of the initial efforts involved improving oral health literacy.

Goldie Krantz made it clear that she wanted the union members to understand the importance of oral health and how integral it is to overall health. There would be a new normal: consumers would expect to be able to access dental health care.

## Designing a new dental benefit corporation now would not only be coming late to the party, but the admission ticket would be very pricey.

In the beginning, the service corporation was in the enviable position of having a customer (the union) before it had a product. Starting a dental benefit plan today would be an entirely different enterprise.

Today, there are more and more players in the dental benefits marketplace. The Affordable Care Act (ACA) and how it will be realized in California is still a work in progress. Market forces are continuing to leverage down reimbursement rates. Designing a new dental benefit corporation now would not only be coming late to the party, but the admission ticket would be very pricey.

In a recent survey of Californians, only 5.2 percent were unsatisfied with their dental insurance plan. Slightly more than 75 percent of the respondents were satisfied with their dental insurance. Though a survey of dentists' satisfaction would probably show that ratio reversed, it seems clear that consumers do not seem to share our dissatisfaction with the third-party payer experience. A new dental insurance company would have to face an uphill battle to win over those satisfied consumers.

So here we stand, 60 years after the beginning of prepaid dental benefits, facing a tectonic shift in dental benefits financing. Wondering what will be left when the shaking stops and what

the new normal will look like. The CDA Dental Benefits Research Task Force is identifying strategies and recommendations to enhance the position of providers and patients in the dental benefits marketplace.

Heraclitus may have been correct when he said the only constant is change, but knowing that truth does not give one much solace. Where is that Greek philosopher's perfect quote about stand-alone dental benefit plans or the future of private practice dentistry when you need it? ■■■■

### REFERENCES

1. [historylink.org/index.cfm?DisplayPage=output.cfm&file\\_id=5699](http://historylink.org/index.cfm?DisplayPage=output.cfm&file_id=5699).
2. Dixon, personal papers, 1962.

### The Journal of the California Dental Association welcomes letters.

*We reserve the right to edit all communications and require that all letters be signed. Letters should discuss an item published in the Journal within the past two months or matters of general interest to our readership. Letters must be no more than 500 words and cite no more than five references. No illustrations will be accepted. Letters may be submitted at [editorialmanager.com/jcaldentassoc](http://editorialmanager.com/jcaldentassoc). By sending the letter to the Journal, the author certifies that neither the letter nor one with substantially similar content under the writer's authorship has been published or is being considered for publication elsewhere, and the author acknowledges and agrees that the letter and all rights of the author with regard to the letter become the property of the California Dental Association.*

## Are the Students Our Guinea Pigs: What's Happening to Dental Education?

There is some anxiety in the dental profession these days. Students are incurring phenomenal debt as they head toward graduation and the profession of dentistry. Schools that have \$100,000 tuitions are getting thousands of applications for hundreds of seats. Large numbers of college graduates are willing to mortgage their future for a dental education. New schools are opening in a variety of locations to meet this demand. Some of these schools are crafting teaching models that send the students far from the campus to learn at outlying clinics. Calibration of faculty and consistency of facilities becomes a huge challenge. In addition, the attitude among many faculty is that it isn't their job to help students be successful dentists — it's the vagaries of the marketplace and the responsibility of the students to choose wisely and prepare properly for the future. The faculty's job is to teach students to be dentists.

What to do? There are many discussions going on informally. And as usual, there are frustrating checks and balances that keep those with the most information from acting directly for the benefit of the profession. One solution would be to force the Commission on Dental Accreditation (CODA) to strengthen its requirements for the proper education of a dentist. Some faculties and dentists are urging the profession to connect more tightly with medicine — move dentistry toward a specialty of medicine in the minds of the patients, with its specialties seen more as subspecialties, similar to orthopedic specialists with subspecialties of the hand, back, etc. If not that far-reaching, at least strengthen graduation requirements so that students must receive close, calibrated faculty supervision and

complete a stated volume of procedures to ensure competency as stated in the state dental practice acts. New campuses should be required to prove the comparable quality of their educational models before getting permission to influence the lives and livelihoods of future dental students. Finding out after the fact that students aren't being taught to the same level of competence seems comparable to drug companies offering minimal studies to prove efficacy for a new medication only to discover later that the drug side effects are much more serious than first portrayed in their small samples. CODA should be pushing existing schools to continue to improve. The standards should continue to rise as the dental products, techniques and services continue to expand and become more complex.

Finally, the profession as a whole should put pressure on their institutions to better educate new dentists. They should express their voices to their elected representatives who meet at the ADA House of Delegates yearly to chart the direction of the association. Along with an effort to force the profession to constantly improve, each dentist should support his/her institution to help keep tuition reasonable. Giving back doesn't just mean showing up at alumni meetings, it also means sharing some of the benefits of this great profession with the dentists of tomorrow.

WILLIAM VAN DYK, DDS  
*San Francisco*



### Morals, Ethics, Integrity

What is the meaning behind these words? How do they affect our behavior and interaction with others? How do they affect our character?

Dr. Dugoni's excellent article, "Road Signs on the Road of Life," in the July 2013 *Journal* brings to mind these age-old questions.

We are all aware that morality deals with the distinction between right and wrong, good and evil, truth and falsehood. Integrity is the scale that measures the level to which we adhere to those moral principles, either high or low on that scale. Ethics is the fabric pouch containing the rules that differentiate between right and wrong. Ethics instills the concept of the moral being in a structured format that becomes an integral part of our character. Character is what we do and who we are when no one is looking. Character is how our values affect our behavior.

We know that in some, the pouch of ethics is structurally weak, even nonexistent. The fabric was either inadequately woven from the onset



## If your practice could use additional support, you could use a loan from US.

Whether you're expanding or starting your practice, U.S. Bank can help with equipment, buy-outs, refinancing or more. With the help of a trusted U.S. Bank Practice Finance Specialist, our Specialists will prescribe solutions that may help your practice.

**Acquisition Financing | Practice Debt Refinancing**  
**New Practice Start-Ups | Buy-Ins**  
**Expansions | Relocations | Buy-Outs**

**Call Jeramie Eimers**  
 Practice Finance Specialist  
 800.313.8820 ext. 2

All of **us** serving you®

EST. 1863 | **usbank**

Subject to normal credit approval. Some restrictions may apply. Deposit products offered by U.S. Bank National Association. Member FDIC ©2013 U.S. Bank

or was of an inferior grade. For these individuals, right and wrong blend into a murky primordial soup. Empathy and conscience may be weak or absent. We might say, "The devil got into him," or, "He lacks integrity and character," or, "He's a psychopath." The existence of this dichotomy — good versus evil, right versus wrong — is an inseparable part of the human condition and is one reason why religion and codified law exist. It's why we require prison and armies. Somewhere on the journey between infancy and adulthood, the path was lost. Perhaps science one day will have an explanation, but until then, we can all do mental gymnastics to strengthen and repair our ethical fabric. Disciplining ourselves to do the right thing rather than being expedient. Treating others as we would want to be treated. Putting ourselves into the shoes of others. Empathy. Understanding. Old-time values. Only by maintaining a strong ethical pouch can we preserve our morals.

A strong moral fiber ensures that our profession continues to maintain the high level of trust and respect our forebearers worked so hard to establish. Without it, we sink into a depression in which trust and respect suffer.

As an exercise, ask yourself the following questions:

*Have I helped make this world and its inhabitants better because I was here?*

*Is someone, somewhere, happier because I have walked this Earth?*

And finally, *What do I want them to say at my funeral?*

The answers could act as a guide on your journey.

We all have a choice. Let's strive to leave our profession better than we found it. It's the right thing to do.

**TED URBANSKI, DDS**  
*Tustin, Calif.*





## **This is why you do what you do.**

Whether you're easing their fears or helping them smile with more confidence, caring for people and making a difference in their lives is why you became a dentist. And behind you all the way is the California Dental Association. Twenty-five thousand of your peers working to protect the profession, champion new ideas and provide helpful resources so that you can continue to do what you love—care for your patients.

**CDA Membership**  
[cda.org](http://cda.org)



# A Legacy of Innovation



## Legacy™4 Implant



All-in-1 Packaging includes implant, fixture-mount, abutment, transfer, cover screw & healing collar — **\$225 SBM, \$250 HA surface**

**Torque- safety**  
feature prevents damage  
to implant interface

Square top detaches  
with impression for  
**metal to metal**  
transfer accuracy

Two-Piece fixture-mount  
(patent pending) with  
**preparable abutment**

**Concave transgingival profile**  
matched with healing collar to shape  
soft tissue for improved esthetics

Quadruple-lead  
micro-threads

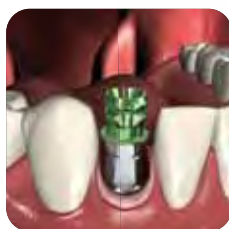
Progressively deeper  
buttress threads

Three long  
cutting grooves

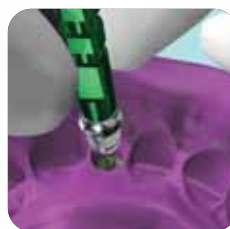
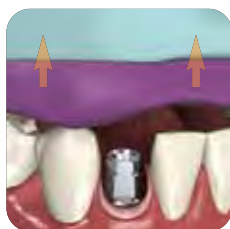### A Legacy of Innovation from Dr. Gerald Niznick

#### Legacy 4 – the culmination of 30 years of evolution


Introducing a revolutionary 2-piece fixture-mount/abutment that provides the accuracy of an open-tray transfer with the simplicity of a closed-tray transfer.



Square top detaches with the impression, providing a snap attachment for abutment/analog.

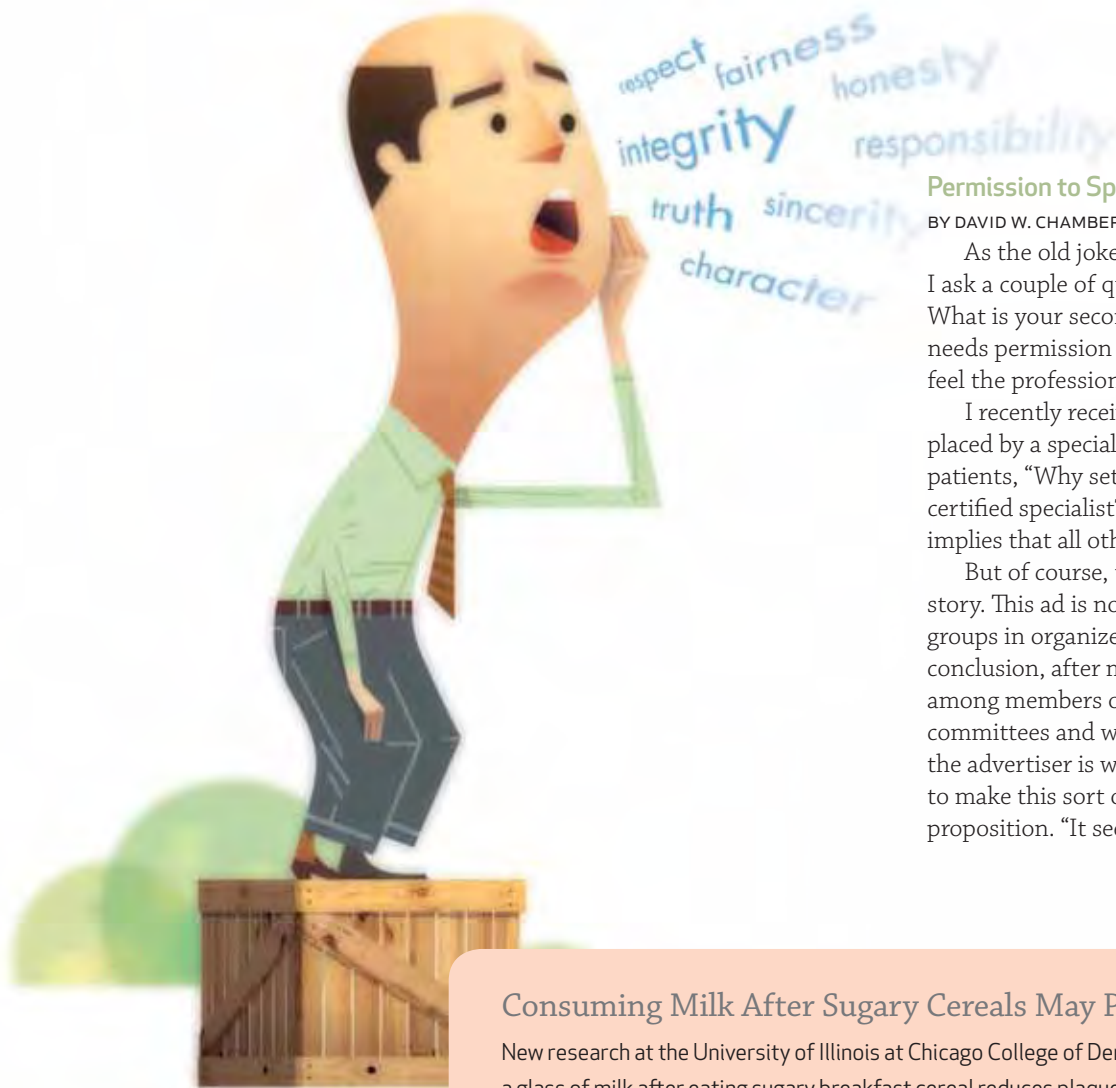

The abutment portion of the fixture-mount snaps onto the transferred top for the accuracy of a metal-to-metal connection



	Laboratory Abutment	Straight Snap-On	Straight Contoured	15° Angled Contoured	Gold/Plastic	Zirconia/Ti Abutment	Plastic Temporary Abutment	Ball Attachment	GPS™ Attachment	Angled GPS™ Attachment	Multiple-Unit w/Cap & Transfer Straight	Angled
Our price	\$85	\$100	\$100	\$100	\$120	\$120	\$40	\$112	\$100	\$120	\$100	\$120
Zimmer Dental®	\$162	\$220	\$175	\$190	\$216	\$260	\$67	\$179	\$166	N/A	\$217	\$297

[www.implantdirect.com](http://www.implantdirect.com) | 888-649-6425



## Permission to Speak

BY DAVID W. CHAMBERS, PHD

As the old joke goes, "Do you mind if I ask a couple of questions?" "Not at all. What is your second question?" No one needs permission to tell others when they feel the profession is being damaged.

I recently received a copy of an ad placed by a specialist. It asked potential patients, "Why settle for less than a board-certified specialist?" I find that offensive. It implies that all others are less qualified.

But of course, there is more to the story. This ad is now notorious in various groups in organized dentistry. The conclusion, after months of consultation among members of state and national committees and with legal counsel, is that the advertiser is within his legal rights to make this sort of claim as a business proposition. "It seems," said one California

CONTINUES ON 737

## Consuming Milk After Sugary Cereals May Prevent Cavities

New research at the University of Illinois at Chicago College of Dentistry has found that a glass of milk after eating sugary breakfast cereal reduces plaque acid levels and may prevent damage to tooth enamel that leads to cavities.

The study, published in the *Journal of the American Dental Association*, evaluated whether whole milk, 100 percent apple juice or tap water affected dental plaque acidity in people after a sugary challenge. Researchers measured plaque pH, or acidity, between the premolar teeth before eating; at two and five minutes after eating; and then two to 30 minutes after drinking a liquid.

Participants who drank milk after eating sugary cereal showed the highest pH rise, from 5.75 to 6.48 at 30 minutes. Those who drank apple juice remained at pH 5.84 at 30 minutes, while water raised the pH to 6.02, according to a news release from the university.

"If understood and implemented properly, food sequencing can be used as a public health educational tool to maintain and preserve good oral health," said Shilpa Naval, BDS, MPH, MS, one of the study authors, in the news release.

For more information, see the study in the *Journal of the American Dental Association*, July 1, 2013, vol. 144, no. 7, pp. 815-822.







### FDA Approves Marketing of Faster Steam Sterilizer Test

The U.S. Food and Drug Administration has approved the marketing of a new test that has the ability to more quickly determine whether steam sterilization of reusable medical devices is effective, according to a news release from the FDA.

Described by the FDA as “the first biological indicator test that gives results in two hours,” the Verify Cronos Self Contained Biological Indicator (SCBI) is used in reprocessing, a multistep process to clean and disinfect or sterilize reusable medical devices.

“This is a novel and innovative use of recombinant DNA technology in biological indicator tests,” said Christy Foreman, director of the Office of Device Evaluation in FDA’s Center for Devices and Radiological Health, in the news release. “By providing faster confirmation of sterilization, this innovation may help health care facilities provide their medical staff with a faster turnaround of their sterilized reusable devices.”

Like other biological indicator tests, the Verify Cronos SCBI consists of a

vial containing dried spores from the heat-resistant bacteria *Geobacillus stearothermophilus*. Prior to the start of a sterilization cycle, the vial is placed inside the sterilization chamber with the sterilization load. After the cycle is complete, the spores are placed in a liquid that provides an ideal environment for the growth of any surviving bacteria, and monitored for spore growth. Growth of bacteria indicates that a sterilization load failed.

The new test uses a genetically engineered strain *Geobacillus stearothermophilus* that produces an enzyme that fluoresces in reaction with the “recovery medium” if test microorganisms are present after the sterilization process. Genetically engineered *Geobacillus stearothermophilus* that survive a sterilization cycle will start growing and producing the enzyme within two hours, giving results much more quickly than the 24 hours typically needed with a natural bacterial strain.

For more information, visit [www.fda.gov/newsevents/newsroom/pressannouncements/ucm360703.htm](http://www.fda.gov/newsevents/newsroom/pressannouncements/ucm360703.htm).

### Pharmacist Group Reports Doxycycline Shortage

The American Society of Health-System Pharmacists has reported a raw material shortage causing doxycycline, a broad-spectrum bacteriostatic antibiotic, to be in short supply.

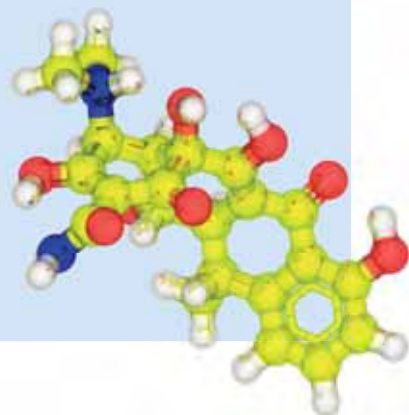
Edmond Truelove, DDS, vice chair of the ADA Council on Scientific Affairs, said in an ADA news story that the shortfall affects all of dentistry, though perhaps has a more pronounced impact on certain areas, such as periodontology.

“We manage patients who have compromised oral conditions and in those patients we use doxycycline in some cases to keep the gingiva stable and less inflamed,” he said in the article. “So the more shortage there is, the more difficulty we see with patients. There are limited alternatives.”

Minocycline has similar antimicrobial broad-spectrum activity to doxycycline, according to the ASHP website, which also notes that if doxycycline is unavailable, an alternative antibiotic from a different medication class may be preferred over minocycline depending on the indication.

Doxycycline manufacturers attribute the drug shortage to a raw material shortage and to supply and demand, although not all manufacturers could provide reasons for the shortage, the ASHP Drug Shortages Resource Center stated.

For more information about the availability of doxycycline, visit the FDA Drug Shortage website at [www.fda.gov/Drugs/DrugSafety/DrugShortages/default.htm](http://www.fda.gov/Drugs/DrugSafety/DrugShortages/default.htm) or see the ADA news story at [ada.org/news/8845.aspx](http://ada.org/news/8845.aspx).





## Pregnancy Dental Care Policy Adopted by Physicians Group

The American College of Obstetricians and Gynecologists (ACOG) has adopted new guidelines stating that teeth cleanings and dental X-rays are safe for pregnant women. Ob-gyns are now being advised to perform routine oral health assessments at the first prenatal visit and encourage their patients to see a dentist during pregnancy.

"These new recommendations address the questions and concerns that many ob-gyns, dentists and our patients have about whether it is safe to have dental work during pregnancy," said Diana Cheng, MD, vice chair of The College's Committee on Health Care for Underserved Women, in a news release from the ACOG.

The recently released ACOG Committee Opinion underscores the importance of maintaining good oral health during pregnancy and throughout a woman's life. Approximately 40 percent of pregnant women in the U.S. have some form of periodontal disease — including gingivitis, cavities and periodontitis — and physical changes caused by pregnancy can cause changes in teeth and gums, according to the ACOG Committee Opinion.



Ob-gyns are encouraged to reinforce practical advice for their patients: limit sugary foods and drinks, brush teeth twice daily with fluoride toothpaste, floss once daily and visit a dentist twice a year.

The ACOG recommendations reinforce guidelines previously published in the 2010 June issue of the *Journal of the California Dental Association*.

For more information on "Oral Health During Pregnancy and Early Childhood: Evidence-Based Guidelines for Health Professionals," visit [acog.org/About\\_ACOG/News\\_Room/News\\_Releases/2013/Dental\\_X-Rays\\_Teeth\\_Cleanings\\_Safe\\_During\\_Pregnancy](http://acog.org/About_ACOG/News_Room/News_Releases/2013/Dental_X-Rays_Teeth_Cleanings_Safe_During_Pregnancy).

### PERMISSION TO SPEAK, CONTINUED FROM 735

dentist, "that the government has tied our hands and there is nothing we can do."

That is right and wrong at the same time. What is right and good about dentistry is not limited to the financial or legal dimensions. The advertiser is counting on winning the commercial battle, but he can only win the ethical battle if no one speaks up.

The offensive dentist's behavior cannot be controlled in this context, but he is morally constrained to recognize the obloquy of his colleagues.

Of course, one cannot libel others, but private expressions of honest professional opinions are protected speech. A message about how colleagues see the matter switches the focus away from legalisms to ethics. The Department of Consumer Affairs and the state boards do not limit what can be said about good dentistry.

How does one go about crafting an ethical protest? Here is an example.

*Dear Dr. X,*

*I have seen your ad in such-and-such and am troubled by the claim that patients who choose your colleagues are "settling for less." You are certainly within your rights to make this statement as a commercial enterprise regulated by the Department of Consumer Affairs. My concern is ethical. It is possible to read your advertisement as implying that other dentists who are completely qualified to perform the procedures patients seek your services for are inferior to you and must be "settled for." Perhaps you were not aware that patients and your colleagues could interpret your message in this light. I am certain you will want to maintain*

*the high regard patients hold the entire profession in and the ethical respect of your colleagues.*

That is all. No exaggerations, no demands, no threats. A few letters from prominent dentists in the area should send the right message.

The nub:

① There is both a commercial aspect to dentistry and a professional one. Dentists should care about both.

② It is never necessary to request permission to express a position on ethics.

③ The payoff for speaking out ethically is to help define the profession. Controlling others is not part of the procedure.

*David W. Chambers, PhD, is professor of dental education, Arthur A. Dugoni School of Dentistry, San Francisco, and editor of the Journal of the American College of Dentists.*



Practice Support

Dental Benefit Plans

*I've submitted this claim three times, why haven't I received payment?*

Ah the joys of dealing with dental benefit plans, a frustration point for many a dental office. Thankfully, relief is at hand with practice support from CDA. Analysts who specialize in dental benefits are at the ready with advice, information and solutions. Plus, there are valuable resources to help you evaluate plans, learn how to dispute a claim and ultimately, get paid. CDA Practice Support, whether on the phone **866.232.6362** or online **[cda.org/compass](https://cda.org/compass)** it's where smart dentists get smarter.





### Stem Cells Found in Gum Tissue Can Fight Inflammatory Disease

According to new research from the Ostrow School of Dentistry of USC, stem cells found in mouth tissue can not only become other types of cells but can also relieve inflammatory disease.

Published in the *Journal of Dental Research*, the study examined gingival mesenchymal stem cells (GMSC), which are found in the gingiva, or gum tissue, within the mouth.

The cells featured in the study are gingival mesenchymal stem cells (GMSC), which are found in the gingiva. GMSC, like other stem cells, have the ability to develop into different types of cells as well as affect the immune system. While the developmental origins and abilities of GMSC hadn't previously been fully illustrated, this study shows that there are two types of GMSC: those that arise from the mesoderm layer of cells during embryonic development (M-GMSC) and

those that come from cranial neural crest cells (N-GMSC), according to a news release from USC.

N-GMSC develop into many important structures of the head and face, and about 90 percent of the gingival stem cells were found to be derived from cranial neural crest cells, the study noted.

"When transplanted into mice with dextran sulfate sodium (DSS)-induced colitis, N-GMSCs showed superior effects in ameliorating inflammatory-related disease phenotype in comparison with the M-GMSC treatment group," authors wrote.

"In summary, our study indicates that the gingivae contain both neural-crest- and mesoderm-derived MSCs with distinctive stem cell properties," the study concluded.

For more information, see the study in the *Journal of Dental Research* published online before print July 18, 2013, and printed in the September 2013 issue, vol. 92, no. 9, pp. 825-832.



### Research Links Oral Bacteria and Colorectal Cancer

New research from Case Western Reserve University (CWRU) School of Dental Medicine has identified how a common oral bacterium can contribute to colorectal cancer, according to the study published in the journal *Cell Host & Microbe*.

"We found this cancer is linked to an infection from [the bacterium]," said lead study investigator Yiping Han, PhD, in a CWRU news story. "This discovery creates the potential for new diagnostic tools and therapies to treat and prevent the cancer."

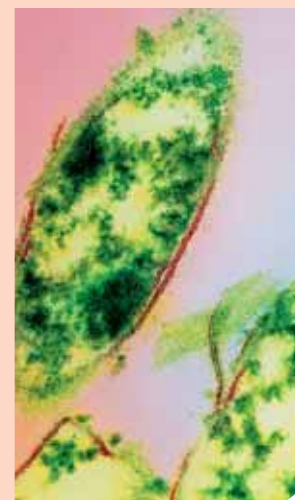
Authors of the study also found "how to prevent the microorganism, called *Fusobacterium nucleatum* (Fn), from attaching to colon cells and potentially triggering a cascade of changes that can lead to cancer," the news story noted.

The authors explain in the study that "*Fusobacterium* spp. [species] are enriched in human colonic adenomas relative to surrounding tissues and in stool samples from colorectal adenoma and carcinoma patients compared to healthy subjects."

They also found that the FadA gene levels are 10 to 100 times higher than normal in precancerous and malignant colon polyps.

These findings suggest that it will be important to consider the contribution of members of the tumor microbiota, such as Fn, and the intersection between microbial gene function and the host response in order to understand colorectal cancer risk, development and progression, the authors concluded.

For more information, see the study in the journal *Cell Host & Microbe*, vol. 14, no. 2, pp. 207-215.



Dr. Karl Lounatmaa / Science Source



## Complete Denture Fabrication: Simplified Methods Effective as Conventional

A recent study has determined that using a simplified method for complete denture fabrication had no adverse effect on patient satisfaction or quality of life.

Although complete denture fabrication involves a series of complex technical procedures, “simplified methods may be as effective as conventional ones albeit the lesser use of time and resources, without disadvantage for the patient,” authors wrote in the study, which was published in the *Journal of Oral Rehabilitation*.

The study compared a simplified method for complete denture fabrication to a conventional protocol in terms of oral health-related quality of life (OHRQoL), patient satisfaction and denture quality, authors noted. They used 42 patients who had been edentulous for at least a year and who were requesting treatment with complete dentures. The patients were randomly divided into two study groups — one that received dentures fabricated by a simplified method and the other that received conventionally fabricated dentures.

OHRQoL and patient satisfaction were analyzed before interventions and again after three and six months following insertion. Denture quality was assessed three months following and the authors reported finding no difference between the two groups for OHRQoL, denture quality and general satisfaction.

The authors concluded that “the simplified method is able to produce dentures of a quality comparable to those produced by the conventional method, influencing OHRQoL and patient satisfaction similarly.”

For more information, see the study in the *Journal of Oral Rehabilitation*, July 2013; 40(7):535-45.



## Poor Oral Health and Cancer-causing Oral HPV Infection

Poor oral health, including gum disease and dental problems, was found to be associated with oral HPV infection, which causes about 40 percent to 80 percent of oropharyngeal cancers, according to a new study in the journal *Cancer Prevention Research*.

“Poor oral health is a new independent risk factor for oral HPV infection and, to our knowledge, this is the first study to examine this association,” said Thanh Cong Bui, doctor of public health, in a news release from the American Association for Cancer Research. “The good news is, this risk factor is modifiable — by maintaining good oral hygiene and good oral health, one can prevent HPV infection and subsequent HPV-related cancers.”

Study authors noted that among the 3,439 study participants, those

who reported poor oral health had a 56 percent higher prevalence of oral HPV infection, and those who had gum disease and dental problems had a 51 percent and 28 percent higher prevalence of oral HPV infection, respectively.

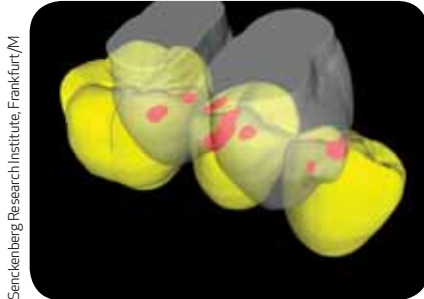
Researchers found that being male, smoking cigarettes, using marijuana and oral sex habits increased the likelihood of oral HPV infection.

Because HPV needs wounds in the mouth to enter and infect the oral cavity, poor oral health, which may include ulcers, mucosal disruption or chronic inflammation, may create an entry portal for HPV, said Bui, adding that there is, however, currently not enough evidence to support this, and further research is needed to understand this relationship.

For more information, see the study in the journal *American Cancer Research*, published online first, Aug. 21, 2013.

**“Poor oral health is a new independent risk factor for oral HPV infection and, to our knowledge, this is the first study to examine this association.”**

**THANH CONG BUI, DRPH**



Senckenberg Research Institute, Frankfurt/M

### Researchers Examine Lifetime Occlusal Surface Changes

Researchers from the Max Planck Institute for Evolutionary Anthropology in Germany and the Senckenberg Research Institute recently conducted stress analyses on gorilla teeth of differing wear stages and found that different features of the occlusal surface antagonize tensile stresses in the tooth-to-tooth contact during the chewing process.

According to the news release, the findings show that tooth wear with its loss of dental tissue and the reduction of the occlusal relief decreases tensile stresses in the tooth, making food processing less effective. Thus, as the occlusal surface changes during an individual's lifetime due to tooth wear, the biomechanical requirements on the existing dental material change as well — an evolutionary compromise for longer tooth preservation.

The researcher team's results show that “in unworn and slightly worn molars (with a well-formed occlusal relief that is most

effective for processing food) tensile stresses concentrate in the grooves of the occlusal surface. In such a condition, the different crests of a molar carry out important biomechanical functions, for example, by reinforcing the crown against stresses that occur during the chewing process. Due to a loss of tooth tissue and a reduction of the occlusal relief the functionality of these crests diminishes during an individual's lifetime. However, this reduced functionality of the crests in worn teeth is counterbalanced by an increase in contact areas during tooth to tooth contacts, which ultimately contributes to a dispersion of the forces that affect the occlusal surface,” according to the news release.

“It seems that we observe an evolutionary compromise for long tooth preservation. Even though worn teeth are not as efficient they still fulfill their task,” Stefano Benazzi, of the Max Planck Institute for Evolutionary Anthropology, said.

For more information, see the full study published July 23, 2013, in the journal *PLoS ONE*, 8(7): e69990.

#### UPCOMING MEETINGS

##### 2013

Oct. 18–21	The American Institute of Oral Biology 70th Annual Meeting, Palm Springs, <a href="http://theaiob.org">theaiob.org</a>
Oct. 31–Nov. 5	154th ADA Annual Session, New Orleans, <a href="http://ada.org/session">ada.org/session</a>
Nov. 3–9	U.S. Dental Tennis Association, Big Island, Hawaii, 800-445-2524 or <a href="http://dentaltennis.org">dentaltennis.org</a>
Nov. 10–13	National Primary Oral Health Conference, Denver, <a href="http://nnoha.org/conference/npohc.html">nnoha.org/conference/npohc.html</a>

##### 2014

May 15–17	CDA Presents <i>The Art and Science of Dentistry</i> , Anaheim, 800-CDA-SMILE (232-7645) or <a href="http://cdapresents.com">cdapresents.com</a>
Sept. 4–6	CDA Presents <i>The Art and Science of Dentistry</i> , San Francisco, 800-CDA-SMILE (232-7645) or <a href="http://cdapresents.com">cdapresents.com</a>

To have an event included on this list of nonprofit association continuing education meetings, please email Courtney Grant at [courtney.grant@cda.org](mailto:courtney.grant@cda.org).



## The Art and Science of Dentistry

### Save the dates

*CDA Presents.* The premier dental convention in the U.S.

- Nearly 600 exhibiting companies
- More than 100 new product introductions
- Dynamic speakers
- Exciting attractions in Anaheim and San Francisco

► [cdapresents.com](http://cdapresents.com)



Like us  
[facebook.com/cdafan](https://facebook.com/cdafan)



#cdaANA  
#cdaSF

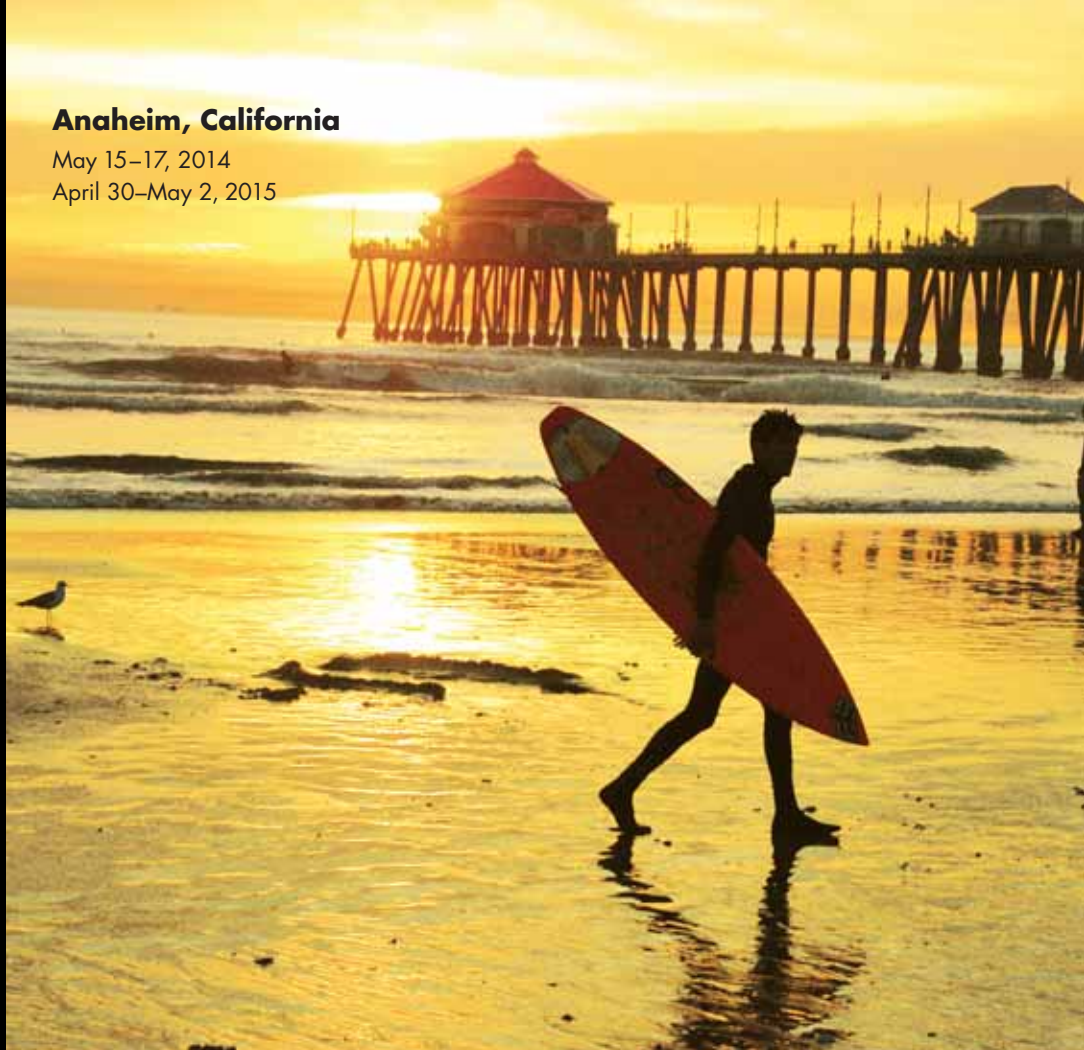


Download the  
show app!

### Anaheim, California

May 15–17, 2014

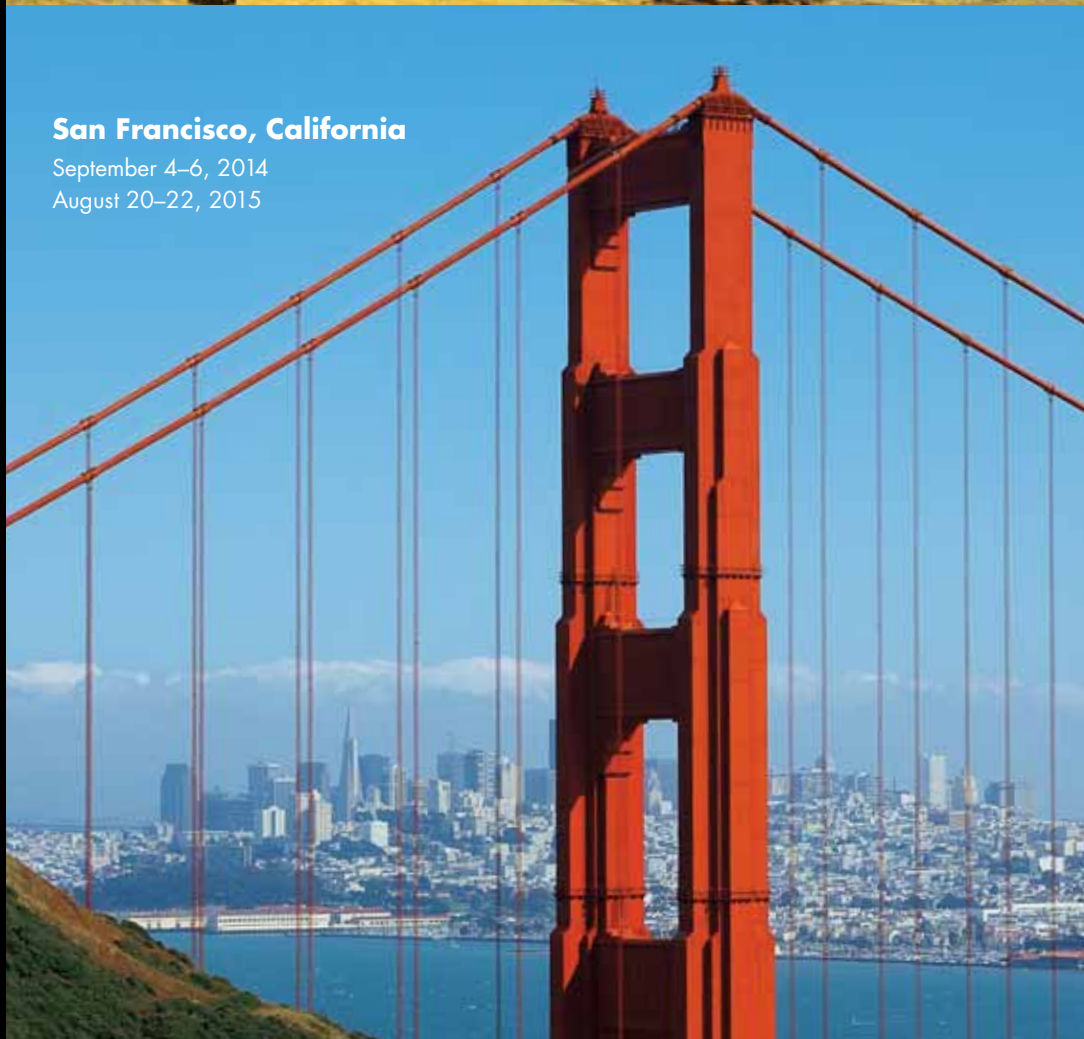April 30–May 2, 2015




### San Francisco, California

September 4–6, 2014


August 20–22, 2015











# Managing Caries in Virtual Dental Homes Using Interim Therapeutic Restorations

PAUL GLASSMAN, DDS, MA, MBA; PAUL SUBAR, DDS, EDD; AND  
ALAN W. BUDENZ, MS, DDS, MBA

**ABSTRACT** The Pacific Center for Special Care at the University of the Pacific, Arthur A. Dugoni School of Dentistry has developed the virtual dental home (VDH) system, which uses allied dental professionals trained to place interim therapeutic restorations (ITR) under the general supervision of dentists. This paper reviews the scientific basis for the ITR, as used in the VDH system, in managing caries lesions and delivering oral health care to underserved and vulnerable populations.

## AUTHORS

**Paul Glassman, DDS, MA, MBA**, is professor of Dental Practice and director of Community Oral Health at the University of the Pacific, Arthur A. Dugoni School of Dentistry in San Francisco. He is also the director of the Pacific Center for Special Care.  
*Conflict of Interest*  
*Disclosure: None reported.*

**Paul Subar, DDS, EdD**, is assistant professor and director of the Special Care Clinic/Hospital Dentistry Program at the University of the Pacific, Arthur A. Dugoni School of Dentistry in San Francisco.  
*Conflict of Interest*  
*Disclosure: None reported.*

**Alan W. Budenz, MS, DDS, MBA**, is a professor in the Department of Biomedical Sciences and Department of Dental Practice and the vice chair of Diagnostic Sciences and Services at the University of the Pacific, Arthur A. Dugoni School of Dentistry in San Francisco.  
*Conflict of Interest*  
*Disclosure: None reported.*

**T**he purpose of this paper is to review the scientific basis for the role of interim therapeutic restorations (ITR), as used in the virtual dental home system (VDH), in managing caries lesions and delivering oral health care to underserved and vulnerable populations. Earlier papers described the structure of the VDH system and community-based prevention and early intervention strategies described some of the scientific literature in these areas.<sup>1,2</sup> This paper focuses on the ITR and incorporates additional and newer evidence.

### The Virtual Dental Home

The VDH is a system for delivering oral health services to underserved and vulnerable populations using geographically distributed, telehealth-

enabled teams working in community locations outside of the traditional dental care delivery system.<sup>1</sup> Developed by the Pacific Center for Special Care at the University of the Pacific, Arthur A. Dugoni School of Dentistry (Pacific), this system is being demonstrated in communities across California. The VDH system was designed to address the significant access challenges and health disparities faced by large and increasing segments of the population. These disparities were described in the 2000 report of the U.S. Surgeon General and affirmed by the 2011 reports of the Institute of Medicine and the National Research Council of the National Academies of Science, *Advancing Oral Health in America and Improving Access to Oral Health Care for Vulnerable and Underserved Populations*.<sup>3,4,5</sup>

By creating a VDH in sites throughout California, Pacific is delivering oral health services in locations where traditionally underserved people live, work, play, go to school and receive social services. This system promotes collaboration between dentists in dental offices and clinics and community-based allied dental professionals. This system redefines the use of the term “dental home” to include the entire geographically distributed, collaborative, telehealth-facilitated system of care. The VDH provides all the ingredients of the health home, including health education and promotion activities, tracking of patient needs and experiences, help with navigation of the health system, referral for advanced work when needed and integration of oral health issues into the educational, social and general health environment where it is being used. The system also puts dentists at the head of the distributed team, and most importantly, it brings much-needed services to individuals who might otherwise receive no care. Equipped with portable imaging equipment and an Internet-based dental record system, the allied dental professionals working in the VDH system collect electronic dental records including radiographs, photographs, charts of dental findings and dental and medical histories, and upload the information to a secure website where the records are reviewed by a collaborating dentist. The dentist reviews the patient’s information and creates a dental treatment plan.

### ITRs in the VDH System

In addition to collecting diagnostic information, delivering health promotion and prevention education, performing preventive procedures and providing case management services, allied professionals

in the VDH system are trained to place ITRs. It should be noted that “interim therapeutic restoration” as used in the VDH system is the term developed by the American Academy of Pediatric Dentistry (AAPD) in its *Policy on Interim Therapeutic Restorations (ITR)*.<sup>6</sup> As described in that document, and discussed later in this paper, this term is used to describe the technique referred to more broadly in the literature as atraumatic restorative treatment (ART). The new term, ITR, is used by the AAPD to emphasize the

## THIS SYSTEM PROMOTES collaboration between dentists in dental offices and clinics and community-based allied dental professionals.

provisional nature of the restoration. Allied dental professionals in the VDH demonstration project are placing ITRs under general supervision of dentists in the Health Workforce Pilot Project (HWPP) authorized by the California Office of Statewide Health Planning and Development (OSHPD).<sup>7,8</sup>

The VDH system has trained allied dental professionals to place ITRs under the general supervision of dentists. In this system, the dentist determines that a particular tooth should have a specific ITR (i.e., which tooth and surfaces are to be treated) and provides instructions to the allied dental professional to place the restoration. The allied dental professional then places the interim restoration without the dentist being present in the treatment location. These steps conform

to the definition of general supervision in California law where general supervision means supervision of dental procedures based on instructions given by a licensed dentist but not requiring the physical presence of the supervising dentist during the performance of those procedures.<sup>9,10</sup>

In the VDH system, dentists use a specific set of criteria to determine which teeth should have an ITR placed. The criteria are based on both patient factors and tooth factors as listed below.

### Patient Factors

- The patient’s American Society of Anesthesiologists Physical Status Classification (ASA status) is Class III or less.
- The patient is cooperative enough to have the restoration placed without the need for special protocols (i.e., sedation or physical support).
- The patient or responsible party has provided consent for the procedure.
- The patient reports that the tooth is asymptomatic, or if there is mild sensitivity to sweet, hot or cold, that the sensation stops within seconds of the stimulus being removed.

### Tooth Factors

- The cavity must be accessible without the need for creating access using a dental handpiece.
- The margins of the cavity must be accessible so that clean noncarious margins can be obtained around the entire periphery of the cavity with the use of hand instruments.
- The depth of the lesion must be more than 2 mm from the pulp on radiographic examination or must be judged by the dentist to be a shallow lesion.
- The tooth must be restorable and not have other significant pathology.

Once a dentist determines the need and instructs the allied dental professional to place an ITR in a specific tooth, an appointment is scheduled for that procedure to be completed. The specific technique being used in the VDH system involves removing soft material from the cavity with hand instruments only while avoiding removal of any material from the pulpal floor in all but superficial lesions. Care is taken to obtain clean, noncarious margins. The tooth is then cleaned, conditioned and a high-viscosity, glass-ionomer restorative material is placed in the cavity.

### Diffusion of Innovation

While there is extensive literature on the history and effectiveness of the ART and ITR techniques, many dentists are not aware of this literature and were trained at a time when principles of caries disease management differed from the current scientific understanding. It is well known that “diffusion of innovation” takes a long time and practice patterns are not easily changed, even in the face of knowledge about new scientific understanding.<sup>11,12</sup> In fact, a recent publication about dentists’ use of evidence-based guidelines concluded that “ingrained practice behavior based on personal clinical experience that differed substantially from evidence-based recommendations resulted in a rejection of these recommendations.”<sup>13</sup> However, the legal environment for defining standards of care is changing and it is becoming increasingly important for oral health professionals to understand and practice according to the current scientific basis for the procedures they perform.<sup>14,15</sup>

Equally important to the diffusion of innovation is the adoption of new scientific findings and recommendations into dental education. Much of dental

education is still based on the one-directional flow of information from the faculty to the students, versus a problem-based learning system. Professionals educated in the one-directional flow manner have greater difficulty in accepting and adopting new techniques and recommendations. However, the knowledge and acceptance of the ART and ITR techniques by dental school faculty, with subsequent incorporation into the dental student curriculum, has fortunately been slowly growing. In a

### EQUALLY IMPORTANT TO the diffusion of innovation is the adoption of new scientific findings and recommendations into dental education.

survey of U.S. general dental practitioners conducted in 2003, 55 percent reported having received some form of dental school education in the ART technique in lectures, laboratory exercises and/or hands-on clinical experiences.<sup>16</sup> Additionally, 67 percent of the survey respondents reported performing ART procedures at least sometimes (44 percent often to very often) and 40 percent desired further training on ART techniques. In a similar survey conducted in the United Kingdom in 2005, 42 percent of respondents reported awareness of ART techniques and most used true or modified ART techniques in their practices.<sup>17</sup> The greatest adoption of ART and ITR techniques has been in Latin American countries. In 2009, more than 95 percent of Brazilian dental schools

reported teaching the ART technique and it is widely and routinely used throughout most Central and South American countries, from Mexico to Chile.<sup>18,19</sup> Currently, the vast majority of dental schools in the U.S. are participating in CAMBRA coalitions, which are expanding education in risk assessment, medical management and minimally invasive dentistry and where teaching students about the principles described in this paper is included.

### History of ART, ITR and Sealing Cavities

The ART technique for treatment of carious lesions has been used in many countries around the world since its introduction in Tanzania in the mid-1980s. Similar techniques are referred to as ITRs and as “sealing cavities.” The world literature on ART has been extensively reviewed.<sup>20</sup> In fact, the World Health Organization has produced a training manual for public health workers titled *How to Carry Out Atraumatic Restorative Treatment (ART) on Decayed Teeth*.<sup>21</sup> The WHO manual describes a simple technique that “can be implemented by properly trained personnel with even nondental backgrounds,” even “under field conditions where there is a lack of electricity and modern dental facilities.” The technique described involves the use of “hand instruments only (no electric drills used) for widening cavity openings and for excavating soft, decayed tissue from within the cavity, followed by the application of an adhesive dental material, usually a high-viscosity glass ionomer filling material, into the cavity and over the adjacent pits and fissures.”

The AAPD has adopted the term interim therapeutic restoration. As described in the AAPD *Policy on Interim Therapeutic Restorations*, ITR techniques are almost identical to ART techniques,

CONTINUES ON 750

# Where **smart** dentists get

Find the practice support resources you need easier and faster than ever on the redesigned CDA Compass. It's mobile friendly. It's reorganized. And it's making life easier for thousands of California dentists. Check it out.

## Ask an Expert



Robyn Thomason  
Director, Practice  
Support Center  
Employment  
Practices



Teresa Pichay  
Regulatory  
Compliance

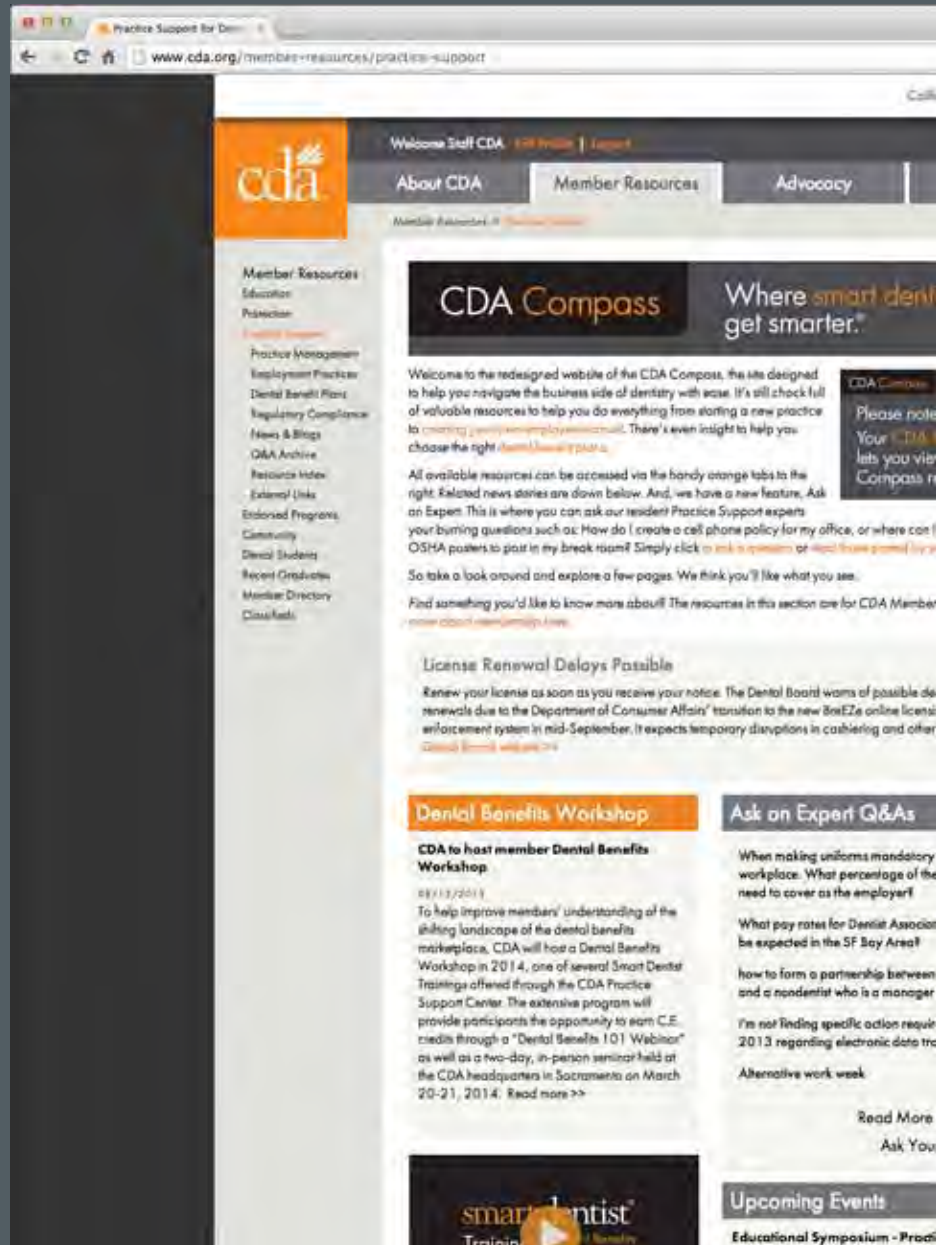


Katie Fornelli  
Practice  
Management



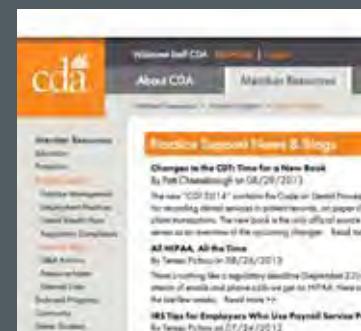Ann Milar  
Dental Benefit  
Plans

There are four practice support analysts at the ready to give you personalized advice on Practice Management, Employment Practices, Dental Benefit Plans and Regulatory Compliance. They're available to give you the perspective and information you need to make smart decisions. Visit [cda.org/compass](http://cda.org/compass) to ask your question or give them a call at 866.232.6362.



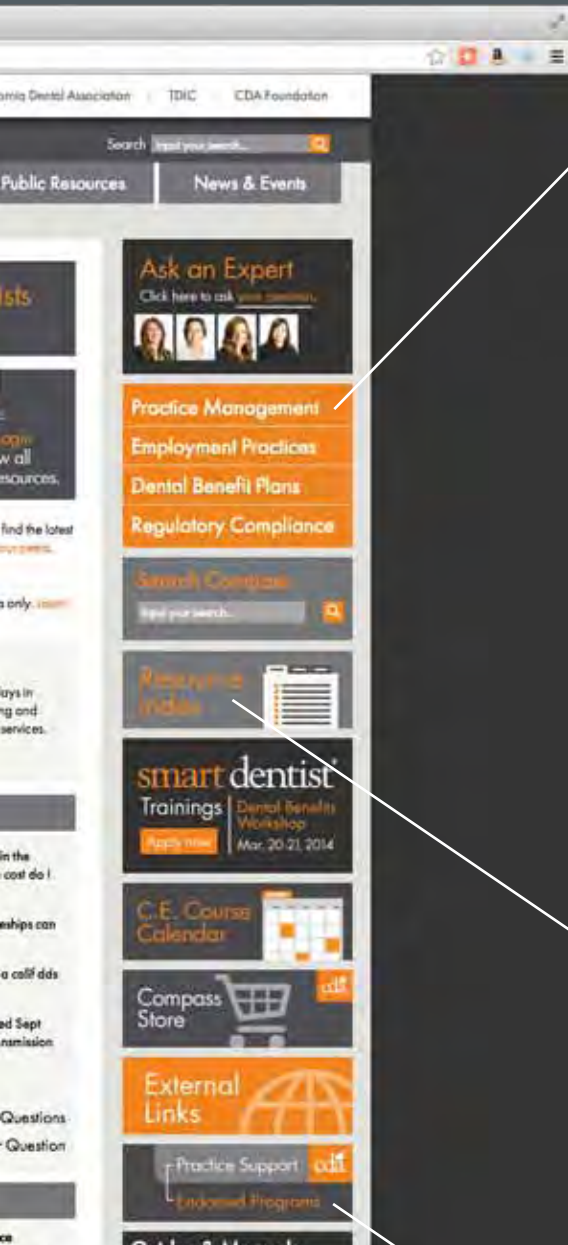## News and Blogs

This section is where you'll find timely news analysis as well as insightful coverage of issues that affect your practice.





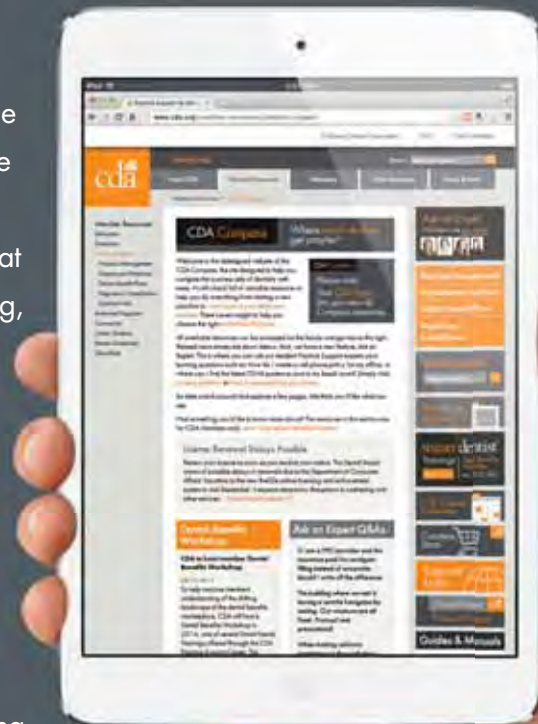
# smarter. [cda.org/compass](http://cda.org/compass)



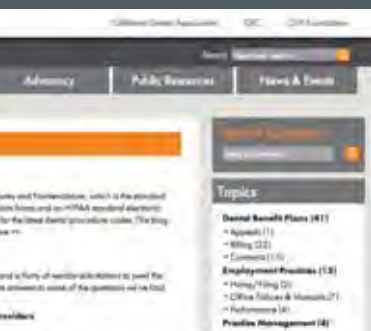## Practice Support

See these buttons? They link you to the four main content areas as well as the practice support analyst who specializes in that category. This is where you can dive a little deeper into a specific content area to get the information you need.

Whether you're on a tablet, smartphone or computer, the site is not only mobile friendly, but now that it resides on [cda.org](http://cda.org), a single login is all you need.



Looking for something specific? Use the handy Resource Index to zero in on just the information you need. Sort by category, or get a complete A-Z listing.



## Endorsed Programs

Research shows that CDA members fare better in almost every facet of business than nonmembers. One reason why is CDA Endorsed Programs. From latex gloves to website design, Endorsed Programs saves you money on everything you need, whether practice management, financial services or supplies for your office.

CONTINUED FROM 747

but the stated purpose of the new name is to emphasize the provisional nature of the restoration.<sup>6</sup> The primary technique difference in the AAPD ITR description is the “removal of caries using hand or *slow-speed rotary instruments*.”

Because the ART technique has been widely used in third-world countries, usually in less than optimal conditions, it has been considered by some to be inferior to conventional dental restorative techniques. However, there is substantial and ever-increasing evidence that in certain situations, the techniques used in ART or ITR produce equal, or in some cases superior, outcomes compared to those produced by conventional restorative techniques. The remainder of this paper will describe this evidence and the scientific basis for concluding that these techniques should have an important role in management of dental caries disease.

Traditional approaches to the restoration of caries lesions in teeth require that clearly defined preparations be created within a tooth, as well as the complete removal of decay. These techniques often sacrifice healthy tooth structure in an effort to provide adequate retention when using nonadhesive materials such as amalgam. As material science has developed, the use of bonded composite and glass ionomer restorative materials have given dentistry new and improved ways to restore teeth with greater conservation of healthy structure.<sup>22</sup>

As our understanding of the pathogenesis of caries disease has increased, the methods in which dentistry treats caries lesions has also shifted. It has become clear that the caries disease process is caused by an ecological shift in the oral biofilm from beneficial to acidogenic bacterial

species. The resultant demineralization of enamel and dentin results in active decay. By reversing, or limiting the extent of salivary pH changes, teeth can be stabilized, and even remineralized.<sup>23</sup> Through use of conservative techniques and contemporary materials such as glass ionomers, it is possible to maintain healthy tooth structure, limit the risk of pulpal exposure and seal the cavity from the nutrient supplies needed by the acidogenic bacteria as part of an overall caries risk reduction strategy.

**BY REVERSING,  
or limiting the extent of  
salivary pH changes, teeth  
can be stabilized, and even  
remineralized.**

Glass ionomer restorations, introduced roughly 40 years ago, adhere to enamel and dentin primarily via calcium bonds to the mineral content of tooth structure. This provides an adaptive seal closely matched to a tooth's coefficient of expansion and contraction. Because of its unique chemistry, glass ionomer materials are most effective when placed in a wet environment, which promotes a strong chemical bond to both enamel and dentin. In addition, glass ionomer materials release fluoride into the surrounding tooth structure as a rechargeable fluoride reservoir.<sup>24,25</sup> Because of the strong chemical bond of glass ionomer materials to both enamel and dentin, and because of the fluoride release, glass ionomer materials can

stop, or at least limit, the activity of caries-causing acidogenic bacteria by depriving the bacteria of their nutrient supply and by the antimicrobial effect of fluoride.<sup>26</sup> The fluoride release also remineralizes and strengthens the surrounding tooth structure and helps to prevent recurrent decay.

Numerous studies and systematic reviews have been carried out to evaluate the ability of glass ionomer restorations to stabilize caries lesion activity, how they affect pulpal and periapical tissues, and what this may mean to a patient's experience in receiving interim care. The clinical research demonstrates favorable safety and effectiveness when conservative, partial caries removal is used versus complete caries removal as advocated by traditional restorative techniques. Additionally, conservative approaches followed by bondable restorations show diminished bacterial loads and evidence that partially excavated teeth do not have higher restoration failure rates.<sup>27,28,29,30</sup> In a 2013 study by Schwendicke et al., a systematic review of 1,257 patients and 1,628 teeth examined the effects of complete versus incomplete decay removal before restoration placement.<sup>31</sup> The authors evaluated the risk of pulpal exposure, post operative pulpal symptoms, restoration failure and caries progression. Although the risk of restoration failure appeared similar for complete versus incomplete decay removal, there were significant risk reductions for pulpal exposure and pulpal symptoms in the incomplete decay removal group. There was also not enough evidence to conclude that one technique was superior to the other in reducing caries progression. In a systematic review by Ricketts et al., 934 patients and 1,375 teeth were included in the study.<sup>32</sup> A comparison of complete

caries excavation versus partial caries excavation was completed using a variety of bonded and conventional restorations. Pulpal exposure occurred in 22 percent of the teeth treated with complete caries excavation versus only 5 percent in teeth treated with partial caries excavation. Positive postoperative signs and symptoms at one-year follow-up occurred in 5 percent of teeth that had complete caries removal versus only 1.3 percent for partially excavated teeth. Failure of the restoration occurred in 6 percent of completely excavated teeth versus 2 percent for the partially excavated teeth.

Although the conservative approach of the ART, and ITR, technique was developed for patients experiencing barriers in accessing basic oral health care, other beneficial effects have been reported. Studies show that dental fear and anxiety affect roughly 10 percent to 20 percent of the U.S. population, resulting in disease progression, lost work and school hours and diminished quality of life.<sup>33,34</sup> Of all of the procedures in dentistry, fear of the sight and feel of a needle produces the most fear.<sup>35</sup> Because ART procedures, and ITR in the VDH, are done without the use of a drill or anesthetic, these procedures produce less pain and anxiety than conventional restorations. This has been verified in a systematic review by Carvalho that concluded that ART promotes less pain and discomfort for patients, even though the procedure is performed with no anesthesia, contributing to a reduction of anxiety and fear during the dental treatment.<sup>36</sup> This data leads to the conclusion that it is advantageous to provide these procedures to young children and those with dental fear as well as other patients in an effort to desensitize them to the dental experience.

## Conclusions

Pacific has developed and is demonstrating the VDH system. The VDH uses dentists working with allied dental professionals in geographically distributed, telehealth connected teams to bring oral health to traditionally underserved people across California. In addition to collecting diagnostic information, delivering health promotion and prevention education, performing preventive procedures and providing case management services, allied professionals in the VDH system are trained to place ITRs under the general supervision of dentists.

The technique used to place ITRs in the VDH system is similar to what has been described in the extensive literature on ART. Although first described as a technique suited for countries where dental care is delivered in less than optimal conditions, there is substantial, increasing evidence that in certain situations the techniques used in ART or ITR produce equal, or in some cases superior, outcomes compared to the outcomes produced by conventional restorative techniques. The ITR technique does not require the removal of all caries infected tooth structure, can stop the progress of decay and can restore function and esthetics while producing fewer pulpal symptoms, less pain and less anxiety than conventional restorative techniques. When used with children and adults who do not access the traditional dental care system in the VDH system, this technique can keep caries from progressing while allowing dentists to monitor the tooth and make further treatment decisions. It is a valuable adjunct to the VDH system and a technique with increasing utility in traditional dental settings. ■■■■

## REFERENCES

1. Glassman P, Harrington M, Namakian M, Subar P. The Virtual Dental Home: Bringing Oral Health to Vulnerable and Underserved Populations. *J Calif Dent Assoc* 2012; 40(7):569-577.
2. Budenz A, Subar P. Community-based Prevention and Early Intervention Strategies. *J Calif Dent Assoc* 2012;40(7):597-603.
3. U.S. Department of Health and Human Services. *Oral Health in America: A Report of the Surgeon General*. Rockville, MD: U.S. Department of Health and Human Services, National Institute of Dental and Craniofacial Research, National Institutes of Health, 2000.
4. The Institute of Medicine. *Advancing Oral Health in America*. 2011. The National Academies Press. Washington D.C.
5. The Institute of Medicine and the National Research Council. *Improving access to oral health care for vulnerable and underserved populations*. 2011. The National Academies Press. Washington D.C.
6. American Academy of Pediatric Dentistry. Policy on Interim Therapeutic Restorations (ITR). Adopted 2001. Revised 2004, 2008. [www.aapd.org/media/Policies\\_Guidelines/P\\_ITR.pdf](http://www.aapd.org/media/Policies_Guidelines/P_ITR.pdf). Accessed Jan. 15, 2012.
7. California Office of Statewide Planning and Development. Health Workforce Pilot Project Program. [www.oshpd.ca.gov/hwdd/HWPP.html](http://www.oshpd.ca.gov/hwdd/HWPP.html). Accessed Jan. 15, 2012.
8. California Office of Statewide Planning and Development. Health Workforce Pilot Project Application #172. [www.oshpd.ca.gov/hwdd/pdfs/HWPP/Abstract\\_HMPP172.pdf](http://www.oshpd.ca.gov/hwdd/pdfs/HWPP/Abstract_HMPP172.pdf). Accessed Jan. 15, 2012.
9. California Business and Professions Code Section 1741(c).
10. California Business and Professions Code Section 1902(d).
11. Berwick DM. Disseminating Innovations in Health Care. *J Am Dent Assoc* 2003;289(15):1969-1975.
12. Cain M, Mittman R. Diffusion of Innovation in Health Care. California Health Care Foundation. 2002.
13. O'Donnell JA, Modesto A, Oakley M, et al. Sealants and dental caries insight into dentists' behaviors regarding implementation of clinical practice recommendations. *J Am Dent Assoc* 2013;144(4):e24-e30.
14. Niederman R, Richards D, Brands W. The changing standard of care. *J Am Dent Assoc* 2012;143(5):434-437.
15. Ambrogi R. California Takes a Giant Step Towards Daubert. *BullsEye Blog*. Dec. 18, 2012. [www.ims-expertservices.com/blog/2012/california-takes-step-towards-daubert](http://www.ims-expertservices.com/blog/2012/california-takes-step-towards-daubert). Accessed May 27, 2013.
16. Seale NS, Casamassimo PS. Access to dental care for children in the United States: A survey of general practitioners. *J Am Dent Assoc* 2003;134(12):1630-1640.
17. Burke FJT, McHugh S, Shaw L, et al. U.K. dentists' attitudes and behavior toward atraumatic restorative treatment for primary teeth. *Br Dent J* 2005;199(6):365-369.
18. Navarro MF, Modena KC, Freitas MCC, Fagundes TC. Transferring ART research into education in Brazil. *J Appl Oral Sci* 2009;17(sp. issue):99-105.
19. Ruiz O, Frencken JE. ART integration in oral health care systems in Latin American countries as perceived by directors of oral health. *J Appl Oral Sci* 2009;17(sp. issue):106-113.
20. Frencken JE, Leal SC, Navarro MF. Twenty-five-year atraumatic restorative treatment (ART) approach: a comprehensive overview. *Clin Oral Invest* 2012;16(5):1337-46.
21. Momand P, Stjernsward J. *How to carry out atraumatic*





### Fellowship in Geriatric Dentistry

The UCSF Multidisciplinary Geriatric Fellowship in Dentistry, Medicine and Mental/Behavioral Health seeks qualified dental applicants who are interested in:

1. Enhancing their ability to provide quality care to older adults;
2. Advanced training for a career in hospital dentistry, public health, teaching and research, or practice specializing in the treatment of older adults;
3. Interdisciplinary, team-based clinical experiences.

### Program Overview

This one or two year fellowship offers interdisciplinary, team-based clinical, education, leadership and research training in the care of older adults, with a focus on underserved populations. The program includes a core didactic curriculum combined with clinical training and the opportunity to conduct research. Education and clinical activities are uniquely adapted to prior experience and interests of each fellow.

### Eligibility and Application Information

- Licensed or eligible to pursue licensure to practice dentistry in California
- U.S. citizen or permanent resident status
- Previous post-doctoral training or clinical practice experience
- Education stipend provided; may be eligible for education loan deferment
- Applications are now being accepted for 2014-2015. Please submit a CV, Personal Statement and 3 Letters of Recommendation to Elaine Chow, email address below.
- For more program information please visit the following website: <http://dentistry.ucsf.edu/admissions/postgraduate-programs/fellowship-in-geriatric-dentistry>

A rolling admissions process will be used. We will review applications beginning in September with interviews starting as early as October. Applicants are encouraged to apply as early as possible.

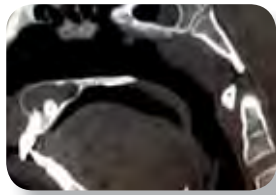
### For further information please contact:

Elaine Chow  
Geriatrics Education Coordinator  
Department of Medicine  
University of California, San Francisco  
4150 Clement St. VA181G  
San Francisco, CA 94121  
Phone: 415-221-4810 x 4453  
Fax: 415-750-6641  
Email: [echow@medicine.ucsf.edu](mailto:echow@medicine.ucsf.edu)

*restorative treatment (ART) on decayed teeth: A training manual for public health workers.* World Health Organization. 2008.

22. Mertz-Fairhurst EJ, Curtis JW, Ertle JW, et al. Ultraconservative and cariostatic sealed restorations: Results at year 10. *J Am Dent Assoc* 1998;129:55-65.
23. Jensen L, Budenz AW, Featherstone JD, et al. Clinical protocols for caries management by risk assessment. *J Calif Dental Assoc* 2007;35(10):714-723.
24. Rekha CV, Varma B. Comparative evaluation of tensile bond strength and microleakage of conventional glass ionomer cement, resin modified glass ionomer cement and compomer: An in vivo study. *Contemp Clin Dent* 2012 Jul-Sep;3(3):282-287.
25. Basso GR, Della Bona A, Gbbi DL, Cecchetti D. Fluoride release from restorative materials. *Braz Dent J* 2011; 22(5):35-8.
26. Oong EM, Griffin SO, Kohn WG, Gooch BF, Caulfield PW. The effect of dental sealants on bacterial levels in caries lesions: a review of the literature. *J Am Dent Assoc* 2008;139(3):271-8.
27. Foley J, Evans D, Blackwell A. Partial caries removal and cariostatic materials in carious primary molar teeth: A randomized controlled clinical trial. *Br Dent J* 2004;197(11):697-701.
28. Maltz M, Henz SL, de Oliveira EF, et al. Conventional caries removal and sealed caries in permanent teeth: a microbiological evaluation. *J Dent* 2012;40:776-782.
29. Thompson V, Craig RG, Curro FA, et al. Treatment of deep carious lesions by complete excavation or partial removal: A critical review. *J Am Dent Assoc* 2008;139:705-712.
30. Innes NPT, Evans DJP, Stirrups DR. Sealing caries in primary molars: Randomized control trial, 5 year results. *J Dent Res* 2011;90(12):1405-1410.
31. Schwendicke F, Dorfer CE, Paris S. Incomplete caries removal: A systematic review and meta-analysis. *J Dent Res* 2013;92(4):306-314.
32. Ricketts D, Lamont T, Innes NPT, Kidd E, et al. Operative caries management in adults and children. *The Cochrane Collaboration* 2013;3:1-51.
33. Tickle M, Milsom K, Crawford FI, et al. Dental anxiety is considerably associated with pain experience during dental procedures. *Community Dent Oral Epidemiol* 2012 Aug;40(4):343-350.
34. Gordon D, Heimberg RG, Tellez M, et al. A critical review of approaches to the treatment of dental anxiety in adults. *J Anxiety Disord* 2013;Apr:1-14.
35. Erten H, Akarslan ZZ, Bodrumlu E. Dental fear and anxiety levels of patients attending a dental clinic. *Quintessence Int* 2006 Apr;37(4):304-310.
36. Carvalho TS, Ribeiro TR, Bonecker M, et al. The atraumatic restorative treatment approach: An "atraumatic" alternative. *Med Oral Pathol Oral Cir Bucal* 2009 Dec;14(12):668-673.

**THE CORRESPONDING AUTHOR**, Paul Glassman, DDS, MA, MBA, can be reached at [pglassman@pacific.edu](mailto:pglassman@pacific.edu).



# Bilateral Impacted Inverted Mesiodens Associated With Dentigerous Cyst

ADITI AMIT BYATNAL, BDS; AMIT BYATNAL, MDS; ANKUR SINGH, MDS;  
VENKADASALAPATHI NARAYANASWAMY, MDS; AND RAGHU RADHAKRISHNAN, MDS, PHD

**ABSTRACT** Mesiodens, the most common type of supernumerary tooth, usually results in malocclusion, poor esthetics and cyst formation. The occurrence of a dentigerous cyst around the crown of an unerupted supernumerary tooth is infrequent. We present a case of a dentigerous cyst associated with a nonsyndromic bilateral impacted inverted supernumerary tooth in a 13-year-old boy. A thorough clinical workup, including 3-D reconstruction image and histological examination confirming the features of a dentigerous cyst is presented in this report.

## AUTHORS

**Aditi Amit Byatnal, BDS,** is a resident in the Department of Oral Pathology and Microbiology at the Manipal College of Dental Sciences, Manipal University in Manipal, Karnataka, India.  
*Conflict of Interest*  
*Disclosure:* None reported.

**Amit Byatnal, MDS,** is an assistant professor in the Department of Oral Medicine and Radiology, at AMES Dental College and Hospital in Raichur, Karnataka, India.  
*Conflict of Interest*  
*Disclosure:* None reported.

**Ankur Singh, MDS,** is an assistant professor in the Department of Oral Pathology and Microbiology at the Manipal College of Dental Sciences.  
*Conflict of Interest*  
*Disclosure:* None reported.

**Venkadasalapathi Narayanaswamy, MDS,** is a consultant surgeon in the Orbit and Oculoplasty Clinic at the Aravind Eye Hospital and Postgraduate Centre in Madurai, Tamil Nadu, India.  
*Conflict of Interest*  
*Disclosure:* None reported.

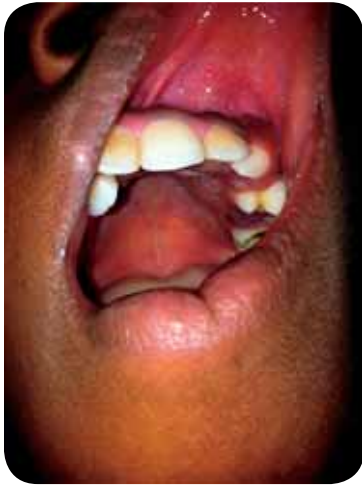**Raghu Radhakrishnan, MDS, PhD,** is a professor in the Department of Oral Pathology and Microbiology at the Manipal College of Dental Sciences.  
*Conflict of Interest*  
*Disclosure:* None reported.

Supernumerary teeth are developmental disturbances that occur because of abnormalities in the morphodifferentiation of the tooth resulting in polydontia. A supernumerary tooth occurring in the midline of the maxilla between the two central incisors is commonly termed a mesiodens. The significant complaint of patients with mesiodens is malocclusion and poor esthetics. Very rarely a dentigerous cyst or follicular cyst may be associated with an unerupted supernumerary tooth.<sup>1</sup> The literature is replete with the reports of dentigerous cysts and supernumerary teeth as two separate entities. However, the development of a dentigerous cyst involving an unerupted supernumerary tooth is not so frequent. We present a rare case of dentigerous cyst associated with an inverted, impacted supernumerary tooth in a 13-year-old

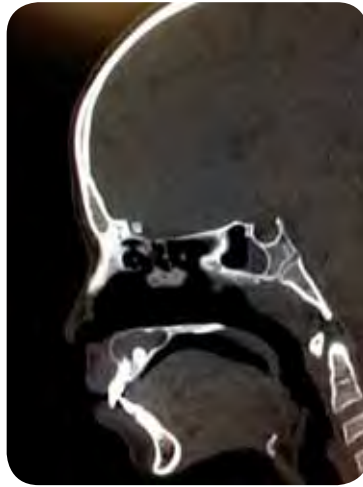boy. Thorough clinical examination, relevant imaging, along with 3-D reconstruction and histopathologic examination, corroborated the diagnosis of dentigerous cyst and confirmed that this rare finding was nonsyndromic.

## Case Presentation

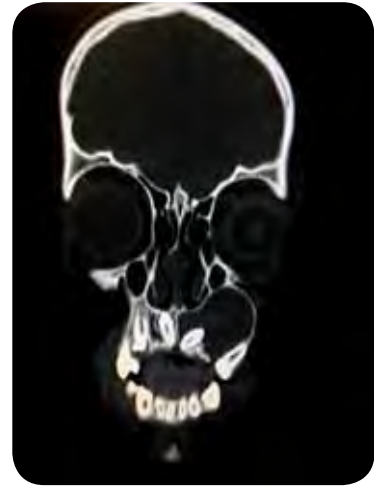A 13-year-old boy was referred to the clinic with a swelling in the upper anterior jaw that had occurred for two years. History of presenting illness suggested that the patient had neglected this enlargement, as it was asymptomatic. Past medical and dental histories were noncontributory. On general examination, the patient was apparently healthy with no history of trauma or any systemic disorders. Intraoral examination revealed normal eruption pattern of the teeth, which were properly formed in both arches. An enlargement measuring about 5 cm by 4 cm in dimension and extending



**FIGURE 1.** Swelling measuring 5 cm x 4 cm extending from left maxillary central incisor to left maxillary canine causing obliteration of mucobuccal fold.



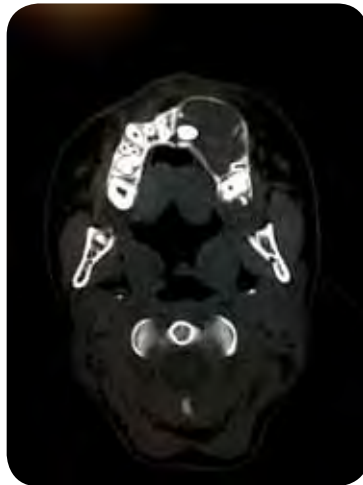**FIGURE 2A.** Sagittal CT showing presence of hyperdense mass at the tip of maxillary central incisor suggesting of supernumerary tooth.



**FIGURE 2B.** Coronal CT showing bilateral inverted supernumerary teeth in the anterior maxillary region; left supernumerary tooth associated with well-defined hypodense area surrounded by thick hyperdense border.

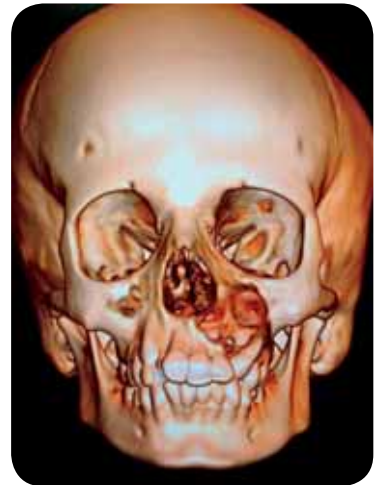from the left maxillary central incisor to the maxillary canine with obliteration of the mucobuccal fold was evident. The swelling was soft, fluctuant and nontender without any evident color change of overlying gingival or alveolar mucosa (**FIGURE 1**). The maxillary anterior teeth were nonmobile and responded positively to vitality tests.

After obtaining informed consent from the patient, a computed tomographic (CT) examination was carried out with a 128-slice multidetector computed tomographic (MDCT) scanner (Siemens SOMATOM Definition AS+, Erlangen, Germany). Sagittal, coronal and axial CT slices of 0.6 mm thickness were obtained, along with the 3-D reconstructed images. Sagittal CT image revealed a well-defined spherical hyperdense mass at the root tip of the permanent maxillary central incisor, suggestive of an impacted supernumerary tooth, which was seen to be enveloped by well-defined hypodense mass surrounded by thick hyperdense border, measuring about 2 cm by 3 cm in dimension, extending from the central incisor to the floor of the maxilla (**FIGURE 2A**). Coronal CT image revealed two inverted, impacted supernumerary



**FIGURE 2C.** Axial CT showing well-defined hypodense area in association with supernumerary tooth; along with destruction of buccolingual cortical plates.

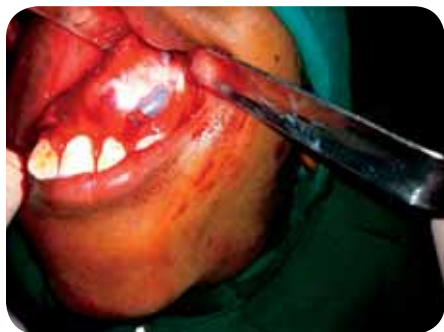teeth bilaterally in the anterior maxilla, with the left supernumerary tooth being associated with well-defined hypodense area surrounded by thick hyperdense border extending from the lateral nasal fossa to the floor of maxillary antrum, and inferiorly to the mesial aspect of maxillary first premolar, suggestive of an impacted supernumerary tooth associated with a cyst (**FIGURE 2B**). An axial CT image also showed a well-



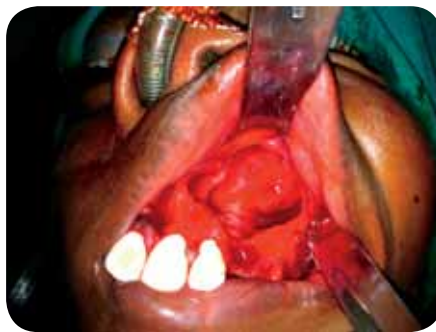**FIGURE 2D.** Three-dimensional reconstruction image showing osteolytic activity in left maxillary anterior region.

defined hypodense area in association with a supernumerary tooth with well-formed hyperdense border roughly 3 cm by 4 cm in size, extending from the midline to the mesial root of first premolar, and buccolingual destruction of cortical plates, suggestive of a cystic cavity (**FIGURE 2C**). A 3-D reconstructed image showed osteolytic activity in the left anterior maxillary region with displacement of the maxillary sinus

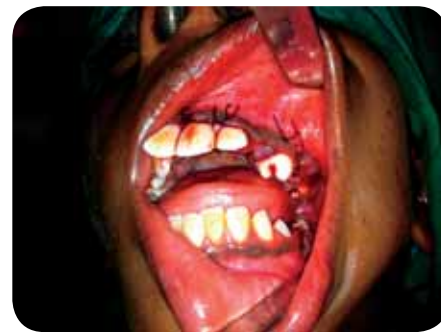



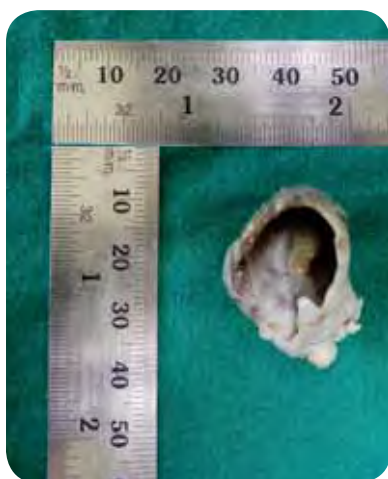**FIGURE 3A.** Surgical enucleation of the cyst under general anesthesia along with extraction of impacted mesiodens.



**FIGURE 3B.** Post enucleation and extraction.



**FIGURE 3C.** Postsurgical sutures placed.



**FIGURE 4.** Gross examination — well-defined cystic lesion associated with an inverted mesiodens.

and laterally to the mesial aspect of first premolar (**FIGURE 2D**). On the basis of clinical and radiographic examination, a provisional diagnosis of inverted, impacted bilateral supernumerary teeth in association with dentigerous cyst was made.

The lesion was surgically enucleated under general anesthesia along with the extraction of the impacted mesiodens associated with it (**FIGURES 3A** and **3B**) and sutures were placed (**FIGURE 3C**). Gross examination of the enucleated cyst showed a soft-tissue specimen measuring about 5 cm by 3 cm in dimension, grayish brown in color, firm in consistency, associated with an impacted supernumerary tooth or mesiodens (**FIGURE 4**). On histopathological examination, a thin cystic lining and cystic

capsule comprising of delicate collagen fibers, abundant ground substance, vascular spaces, occasional inflammatory cells and odontogenic rests were noted (**FIGURE 5A**). On high-power view, the cystic cavity lined by 1-3 layered nonkeratinized stratified squamous epithelium resembling reduced enamel epithelium was noted (**FIGURE 5B**). The cystic lining at places showed ciliated columnar epithelium (**FIGURE 5C**). Correlating with the clinical and radiographic findings, the histologic features were suggestive of dentigerous cyst in association with an impacted mesiodens.

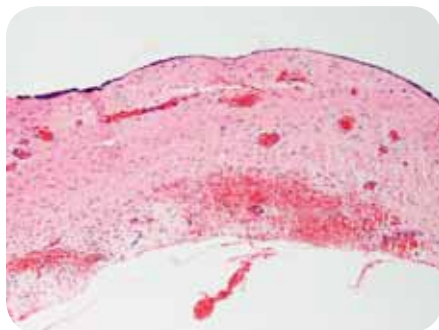
## Discussion

Jaw cysts in the maxillary anterior region, either developmental or inflammatory, most often result in bony enlargement. Most common among the developmental jaw cysts in the anterior maxilla is a dentigerous cyst, which has its peak incidence in the second decade of life, with a slightly higher predilection for males.<sup>1</sup> The occurrence of a dentigerous cyst in the maxillary anterior teeth is rare unless the tooth is unerupted, impacted or malformed. Radiographically it demonstrates a unilocular radiolucency with a well-defined sclerotic border around the crown of an unerupted tooth, as was seen in this case.

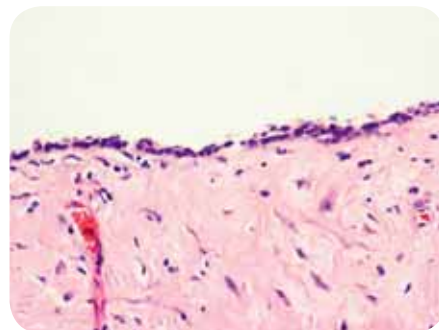
A dentigerous cyst in association with supernumerary teeth is rare, constituting about 5 to 6 percent of all dentigerous cysts. Mesiodens, known to occur between the maxillary central incisors, is the most common type of supernumerary tooth. It is usually present as a conical crown with a

single root often in an inverted position, as was noted in our case. In many instances, a mesiodens is associated with disturbances in tooth eruption, diastema, axial rotation or inclination of erupted permanent incisors, resorption of adjacent teeth and rarely the development of a dentigerous cyst. A few cases of dentigerous cysts associated with impacted supernumerary teeth have been reported.<sup>2-11</sup> A rare finding of a dentigerous cyst in association with an impacted inverted mesiodens following trauma to permanent maxillary central incisor has been reported.<sup>4</sup> There was, however, no history of trauma elicited in our case and the normal complement of teeth in the maxillary anterior region was vital.

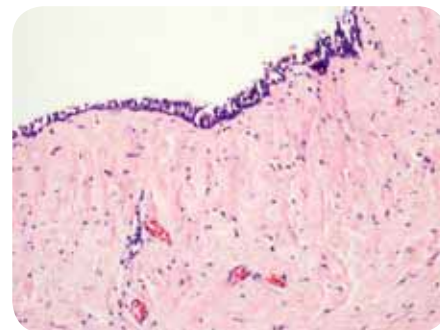
Histologically, the dentigerous cyst displays a thin fibrous cyst wall with a myxomatous appearance. The epithelial lining consists of 2-4 layers of flat or cuboidal cells of reduced enamel epithelium and is characteristically nonkeratinized. Nests, islands or strands of odontogenic epithelium are often seen in fibrous capsule. Localized proliferation of the epithelial lining may occur in response to inflammation. Hyaline bodies, also called Rushton bodies, may be found in the epithelium, especially in cysts exhibiting inflammation. Sometimes mucous secreting cells and rarely ciliated cells form a part of the epithelial lining, as was noted in this case. Occasionally sebaceous cells and lymphoid follicles with germinal centers are seen in the connective tissue capsule. Although, Primosch<sup>12</sup> in his observation reported an



**FIGURE 5A.** Thin cystic capsule composed of delicate collagen fibers with focal chronic inflammatory cells infiltration and occasional odontogenic rests (hematoxylin and eosin stain, 4x magnification).



**FIGURE 5B.** Cystic cavity lined by 1-3 layered non-keratinized stratified squamous epithelium (hematoxylin and eosin stain, 20x magnification).



**FIGURE 5C.** Cystic lining showing ciliated columnar epithelium at places (hematoxylin and eosin stain, 20x magnification).

enlargement of the follicular space in 30 percent of anterior supernumerary teeth, histological evidence of cyst formation was noted in only 4 to 9 percent of cases.

Mesiodentes are classified into rudimentary and supplementary mesiodens on the basis of their appearance. While supplementary mesiodens resemble a natural tooth in both size and shape, rudimentary mesiodens exhibit abnormal shape and smaller size. Based on morphology, mesiodens are categorized as conical, tuberculated or molariform.<sup>12,13</sup> Conical mesiodens usually occur singly, in an upright or inverted position, mostly erupted and at times impacted. Tyrologou et al.<sup>14</sup> and Roychoudhury et al.<sup>15</sup> observed inverted impacted mesiodens in 51.3 percent and 62.5 percent of their cases respectively.

The bilateral conical mesiodens noted in our case and in an inverted position is an unusual finding. Generally located palatally between the maxillary central incisors, mesiodens tend to displace erupting permanent central incisors.<sup>12,13</sup> There was, however, no displacement of teeth observed in our case. Tuberculate mesiodens presents with a barrel-shaped crown with several tubercles or cusps and with an incomplete or abnormally formed root. They rarely erupt but delay the eruption of permanent incisors, and tend to occupy a more palatal position.<sup>13</sup> Molariform mesiodens forms the third type, which has a premolar-like crown and an incompletely formed root.

Histogenesis of mesiodens is supported by three theories in literature.<sup>13</sup> Theory of phylogenetic reversion (atavism), which postulates that the mesiodens represent a phylogenetic relic of extinct ancestors who had three central incisors has been discarded by the embryologists. The theory of dichotomy suggests that the tooth bud is split to create two teeth, one of which is the mesiodens. The most accepted theory suggesting the hyperactivity of the dental lamina states that the remnants of the dental lamina or the palatal offshoots of the active dental lamina are induced to develop an extra tooth bud resulting in a supernumerary tooth.

Once an accessory tooth germ is formed in the vicinity of the incisors class of teeth its epithelium is equipped with signaling molecules. Fibroblast growth factor (FGF8) is seen to be widely expressed within the first arch epithelium. The ectomesenchyme if competent, reciprocate to these signals by expressing Pax 9 (a homeobox gene), a marker of tooth ectomesenchyme, which is induced by fibroblast growth factor. The co-expression of bone morphogenetic proteins in various domains of the epithelium has an initial inhibitory and subsequent inductive role. Depending on the interplay of these factors, the shape of the mesiodens becomes evident at the bell stage.

The presence of unerupted supernumerary teeth could either be syndrome associated or nonsyndromic or systemic conditions. Few of the syndromes associated with supernumerary teeth are depicted in the **TABLE**.<sup>16</sup> In our case no features supporting any of these syndromes were noted. It is infrequent to find multiple supernumerary teeth in individuals with no other associated disease or syndrome and very few cases have been reported in the literature.<sup>17,18</sup>

## Conclusion

Our report further documents an unusual presentation of a nonsyndromic bilaterally inverted, impacted supernumerary teeth associated with a dentigerous cyst. Detection of accessory teeth may be fairly obvious, either by patient's complaint or clinical examination. Alternatively, they are invariably detected after radiographic examination. The mesiodens is a common, and yet an intriguing, dental anomaly that a dental practitioner chances upon, as it is associated with varied complications and systemic disorders. It is important to diagnose these anomalies, which are developmental, in order to avert many a complication associated with these, including the development of jaw cysts. The occurrence of bilateral mesiodens with a dentigerous cyst presented here was diagnosed early and timely surgical intervention instituted. ■■■■

TABLE

Syndromes Associated With Unerupted Supernumerary Teeth<sup>16</sup>

Syndrome	Type of inheritance	General manifestations
Cleidocranial dysplasia	Autosomal dominant	Clavicular hypoplasia, delayed ossification of skull, excessively large fontanelles, delayed closure of sutures, high narrow arched palate, prolonged retention of deciduous teeth
Down's syndrome	Sporadic	Mental retardation, brachycephaly, hypertelorism, depressed nasal bridge, flat occiput, broad and short neck, excessive joint laxity
Gardner syndrome	Autosomal dominant	Multiple polyps in colon, extra-colonic tumors, desmoid tumors, generalized skeletal changes
GAPO syndrome	Autosomal recessive	Growth retardation, alopecia, pseudoanodontia and progressive optic atrophy
Nance-Horan syndrome	X-linked	Congenital cataract leading to profound vision loss, characteristic dysmorphic features, dental anomalies, mental retardation
Noonan's syndrome	Autosomal dominant	Congenital heart defect, hypertrophic cardiomyopathy, short stature, learning problems, impaired blood clotting and a characteristic configuration of facial features including a webbed neck and a flat nose bridge
Oral-facial-digital syndrome	X-linked dominant	Cleft tongue, cleft palate, syndactyly, bradydactyly, kidney disease
Osteoglophonic dysplasia	Autosomal dominant	Craniosynostosis, respiratory problems, rhizomelic dwarfism, multiple metaphyseal defects, anterior beaking of the vertebrae and other abnormalities
Progeria	Autosomal dominant	Limited growth, full-body alopecia, a small face with a shallow recessed jaw and a pinched nose, atherosclerosis, cardiovascular problems, scleroderma, prominent scalp veins
SOX2 anophthalmia syndrome	Autosomal dominant	Anophthalmia or microphthalmia, seizures, brain abnormalities, slow growth, delayed development of motor skills
Tricho-rhino-phalangeal syndrome	Autosomal dominant	Fine and sparse scalp hair, thin nails, pear-shaped broad nose and cone-shaped epiphyses of the middle phalanges of some fingers and toes
Yunis-Varon syndrome	Autosomal recessive	Growth retardation before and after birth, defective growth of the bones of the skull along with complete or partial absence of the shoulder blades and characteristic facial features
Zimmerman-Laband syndrome	Autosomal dominant	Gingival fibromatosis, hypoplasia of the distal phalanges, nail dysplasia, joint hypermobility and sometimes hepatosplenomegaly

## REFERENCES

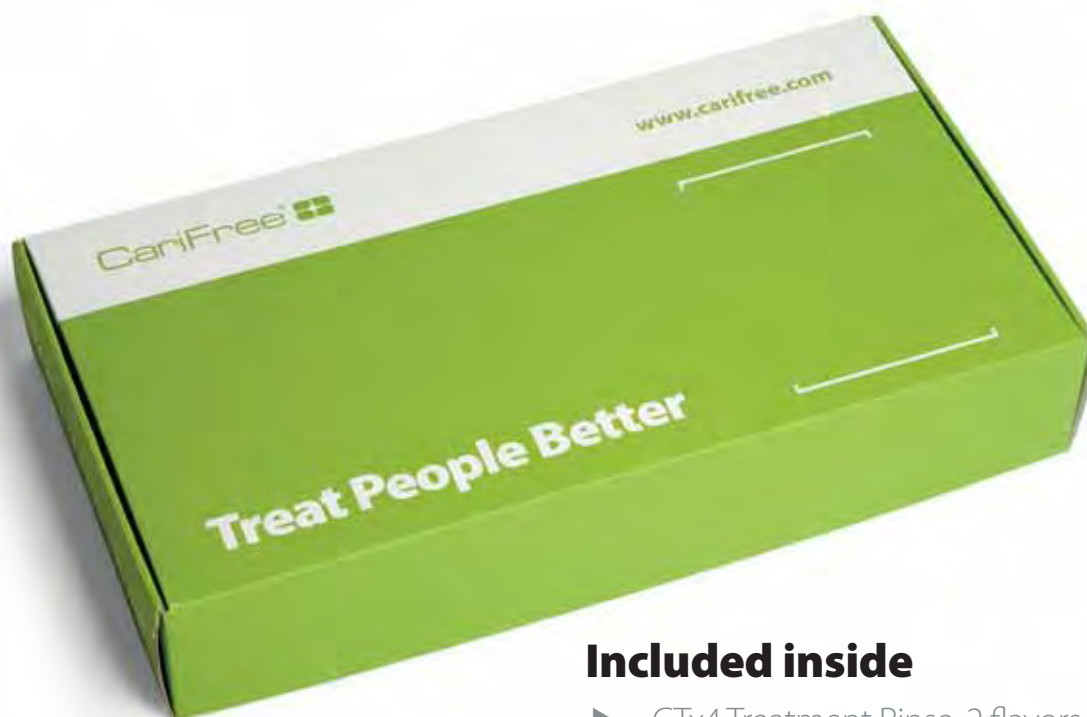- Regezi AJ, Sciubba JJ, Jordan RCK. Oral Pathology: Clinical-Pathologic Correlations, 5th ed. St. Louis: Saunders; 2008:242-244.
- Agarwal NK. Dentigerous cyst in a child associated with multiple inverted supernumerary teeth: a rare occurrence. *Int J Burns Trauma* 2012;2(3):171-173.
- Kalaskar RR, Kalaskar AR. Multidisciplinary management of impacted central incisors due to supernumerary teeth and an associated dentigerous cyst. *Contemp Clin Dent* 2011;2(1):53-58.
- Sharma D, Garg S, Singh G, Swami S. Trauma-induced dentigerous cyst involving an inverted impacted mesiodens: case report. *Dent Traumatol* 2010;26(3):289-291.
- Khan MH, Alam MT, Haque S, Khan SH, Fatema CN, Tahsin T, et al. Upper lip swelling caused by a large dentigerous cyst with mesiodens. *Mymensingh Med J* 2008;17(2 Suppl):S100-103.
- Dinkar AD, Dawasaz AA, Shenoy S. Dentigerous cyst associated with multiple mesiodens: A case report. *J Indian Soc Pedod Prev Dent* 2007;25(1):56-59.
- Scolozzi P, Lombardi T, Richter M. Upper lip swelling caused by a large dentigerous cyst. *Eur Arch Otorhinolaryngol* 2005;262(3):246-249.
- Awang MN, Siar CH. Dentigerous cyst due to mesiodens: report of two cases. *J Ir Dent Assoc* 1989;35(3):117-118.
- Kessler HP, Kraut RA. Dentigerous cyst associated with an impacted mesiodens. *Gen Dent* 1999;37(1):47-49.
- Papadopoulos MS. An unusual case of dentigerous cyst due to mesiodens. *Br J Oral Surg* 1981;19(4):307-308.
- Thoma KH, Smith HW. Dentigerous cyst of maxilla formed from a mesiodens. *Am J Orthod Surg* 1946;32:297-303.
- Primosch RE. Anterior supernumerary teeth: assessment and surgical intervention in children. *Pediatr Dent* 1981;3(2):204-215.
- Russell KA, Folwarczna MA. Mesiodens — diagnosis and management of a common supernumerary tooth. *J Can Dent Assoc* 2003;69(6):362-366.
- Tyrologou S, Koch G, Kuro J. Location, complications and treatment of mesiodentes — a retrospective study in children. *Swed Dent J* 2005;29(1), 1-9.
- Roychoudhury A, Gupta Y, Prakash H. Mesiodens: a retrospective study of fifty teeth. *J Indian Soc Pedod Prev Dent* 2000;18(4):144-146.
- Bayar GR, Ortakoglu K, Sencimen M. Multiple impacted teeth: Report of 3 cases. *Eur J Dent* 2008;2(1):73-8.
- Khambete N, Kumar R. Genetics and presence of non-syndromic supernumerary teeth: A mystery case report and review of literature. *Contemp Clin Dent* 2012;3(4):499-502.
- Akgun OM, Sabuncuoglu F, Altug A, Altun C. Non-syndrome patient with bilateral supernumerary teeth: Case report and 9-year follow-up. *Eur J Dent* 2013;7(1):123-6.

THE CORRESPONDING AUTHOR, Raghu Radhakrishnan, MDS, PhD, can be reached at raghu.radhakrishnan@gmail.com.



# CariFree dental professionals

can't help but do the right thing.



## Included inside

- ▶ CTx4 Treatment Rinse, 2 flavors
- ▶ CTx3 Rinse, 2 flavors
- ▶ CTx4 Gel 5000, 2 flavors
- ▶ Balance by Dr. Kim Kutsch, 2 copies
- ▶ Literature and reviews

Find out what they are using to fight the caries epidemic, and decide if it's right for you, **FREE.**

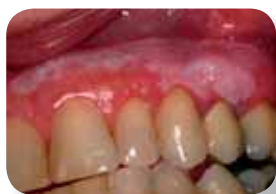**Treat People Better™** at **box.carifree.com.**

Use code **B2ER5M** to get your free box

Valid in U.S. only. 1 per practice, first 50 boxes free.

CariFree®

**866.928.4445**  
**www.carifree.com**



# Lesion Characteristics and Responses After CO<sub>2</sub> Laser Vaporization in Five Patients With Gingival Leukoplakia

NITA CHAINANI-WU, DMD, MS, PHD, AND SOL SILVERMAN JR., MA, DDS

**ABSTRACT** Gingival leukoplakia, a premalignant condition, can pose difficulties to surgical access because of the presence of teeth and potential extensions into the periodontal ligament. We present a series of five patients with gingival leukoplakia who were treated with carbon dioxide laser vaporization. We describe lesion characteristics and recurrence patterns suggesting that presence of gingival leukoplakia on facial and palatal/lingual aspect through the interproximal areas may increase the risk of recurrence after conservative surgical removal.

## AUTHORS

**Nita Chainani-Wu, DMD, MS, PhD**, has a private practice limited to oral medicine in Mountain View, Calif., and is a health sciences associate clinical professor in the Department of Orofacial Sciences at the University of California, San Francisco.  
*Conflict of Interest*  
*Disclosure: None reported.*

**Sol Silverman Jr., MA, DDS**, is a professor emeritus in the Department of Orofacial Sciences at the University of California, San Francisco.  
*Conflict of Interest*  
*Disclosure: None reported.*

Oral leukoplakia is defined as “white plaques of questionable risk having excluded (other) known diseases or disorders that carry no increased risk for cancer.”<sup>1</sup> Leukoplakia is a lesion with malignant potential for squamous cell carcinoma. Surgical removal with either a scalpel or soft tissue laser such as a carbon dioxide (CO<sub>2</sub>) laser is the standard treatment approach.<sup>2</sup>

The advantages of CO<sub>2</sub> laser excision or vaporization include a bloodless field preserving visibility, precise control and improved healing with less scarring. Therefore, this is a popular treatment approach for management of leukoplakia. The frequency of recurrence of oral leukoplakia after CO<sub>2</sub> laser removal has been reported in several publications.<sup>3-10</sup> These estimates have been quite variable

and have ranged from 9 to 38 percent. None of the reported estimates to our knowledge was stratified by lesion characteristics.

Our clinical observation is that the likelihood of recurrence of oral leukoplakia varies based upon the clinical characteristics of the lesion, including accessibility of the margins of the lesion during surgical removal. Gingival leukoplakias, particularly those extending from the facial to palatal/lingual gingiva pose special difficulties because of the presence of teeth and potential extensions into the periodontal ligament, which limit surgical access.

## Patients and Methods

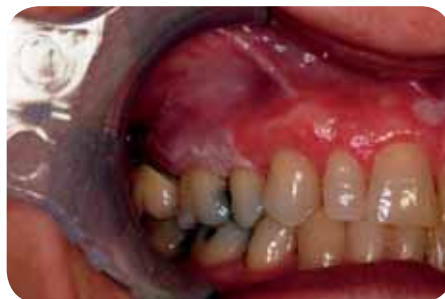We present a case series of five patients with gingival leukoplakia who were treated with carbon dioxide laser vaporization. None of the five patients has any known drug allergies.

All cases were treated on an outpatient basis under local anesthesia using 2% lidocaine with 1:100,000 epinephrine. A CO<sub>2</sub> laser set on continuous mode was used. It was operated in a noncontact fashion, where the tip was held close to the tissue, but without touching the surface. The power settings varied from 4 W to 8 W during the procedures. The exposure time and other details of the individual procedures varied based on the extent and accessibility of the lesions. The tissue ablation included the oral epithelium and underlying connective tissue to the periosteum.

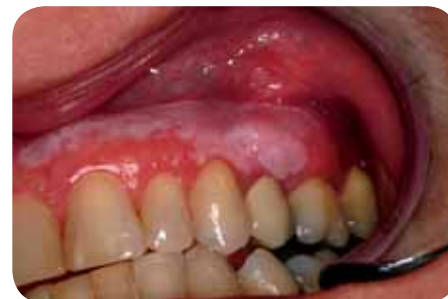The effects of the CO<sub>2</sub> laser on tissue are influenced by the energy level at the point of tissue contact, exposure time and tissue type. The energy level at the point of tissue contact is influenced by the settings on the laser unit specified by the operator, as well as the distance of the tip from the tissue. As the distance of the tip from the tissue increases (defocusing) the energy level at the point of tissue contact drops while the surface area exposed to the laser energy increases. Therefore, the clinician can control the tissue effects during the procedure in multiple ways.

Presurgical incisional biopsies of the most clinically suspicious areas for dysplasia within the lesion were obtained in all cases. Clinical characteristics indicating increased likelihood of microscopic dysplasia or carcinoma include the following: presence of symptoms; presence of ulceration, redness, nodules or verrucous changes on inspection; presence of induration on palpation and positive uptake of toluidine blue stain.

The ablation process was started by first creating a dotted outline with the laser to delineate the extent of the surgical field, which included the lesion and 2 mm lateral margins unless restricted by the anatomy of the site. The

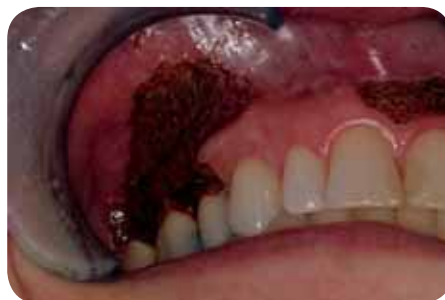

**FIGURE 1A.**

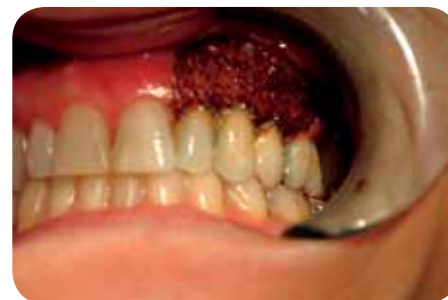

**FIGURE 1B.**

**FIGURES 1A AND 1B.** White changes on the maxillary facial gingiva, bilateral. Changes were limited to the facial gingiva and did not extend on to the palatal side on the affected areas except for the area associated with tooth No. 2.



**FIGURE 1C.**



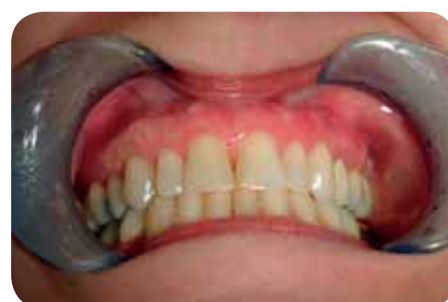**FIGURE 1D.**

**FIGURES 1C AND 1D.** Immediate postoperative appearance following a laser vaporization procedure.

ablation was started at one margin and systematically extended with overlapping passes of laser energy until vaporization of the entire outlined area was completed. Vaporization of extensive leukoplakia was done over multiple visits with removal of part of the lesion at each visit, starting with areas that would allow the maximum proportion of surgical margins to end in normal mucosa. This strategy allows for evaluation of healing and treatment response to laser vaporization of localized areas of leukoplakia within extensive lesions. This strategy also allows outpatient treatment with reduced healing time following a given procedure.

#### Case 1: March 2006

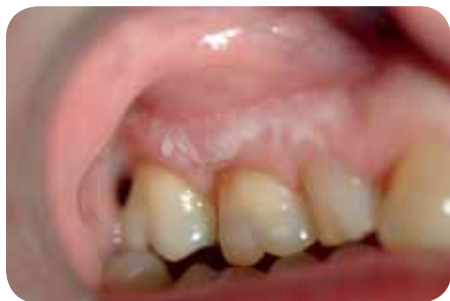A 53-year-old Caucasian woman with chief complaint of “white patches in the mouth.” These were asymptomatic and first noticed by the patient about eight to 10 years ago, at which time they were localized to the upper right facial gingiva. About two years ago, she noticed that white, patch-like changes were also present



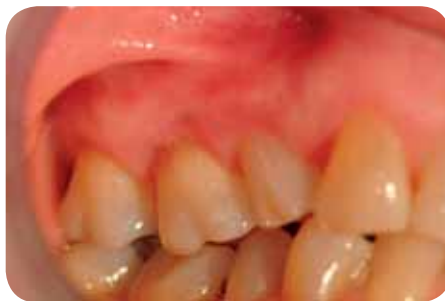**FIGURE 1E.** Three months after completion of the laser vaporization. There was no recurrence at her last follow-up appointment, which was more than three years after the completion of laser vaporization.

on the upper left facial gingiva. She reported no significant medical problems, and was not on any medications. She did not have a history of tobacco use, and reported alcohol intake of one to two glasses of wine three to four times per week. Extraoral examination of the head and neck was within normal limits (WNL). Intraorally, white, plaque-like changes that did not rub off were present bilaterally on the upper facial gingiva and in the area of tooth No. 2 extending posteriorly

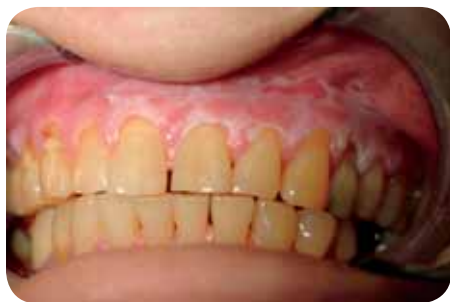



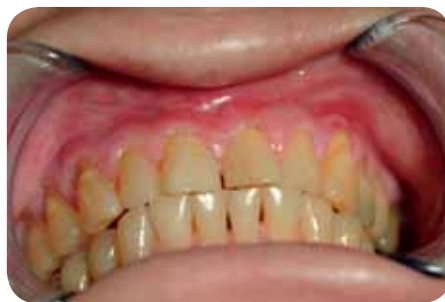**FIGURE 2A.** White changes on the maxillary right facial gingiva. Changes were limited to the facial gingiva and did not extend on to the palatal side on the affected areas.



**FIGURE 2B.** There was no recurrence at her last follow-up appointment, which was about one year after the completion of laser vaporization.



**FIGURE 3A.** White changes on the facial gingiva in the area of teeth Nos. 7 to 14. Changes were limited to the facial gingiva and did not extend onto the palatal side on the affected areas.



**FIGURE 3B.** One month after completion of the laser vaporization that was done over two visits. There was no recurrence at her last follow-up appointment, which was 10 months after the completion of laser vaporization.

to the right maxillary tuberosity and around to the palatal gingiva associated with tooth No. 2 (**FIGURES 1A-1E**). The remaining palatal gingiva was WNL. All areas were toluidine blue negative. The clinical impression was leukoplakia. A biopsy of the facial gingiva in tooth No. 14 area showed “hyperkeratosis with mild dysplasia.” Laser vaporization was completed between April and October 2006, with complete resolution of the leukoplakia. She has been followed periodically with no recurrence as of her last clinic visit in August 2009, more than three years after the last laser excision.

#### Case 2: June 2007

A 64-year-old Caucasian woman with chief complaint of “white changes on gum.” These changes were first noticed by her general dentist and were asymptomatic and of unknown duration. Her medical history included hypothyroidism, hypercholesterolemia and osteopenia.

Her medications included levothyroxine, raloxifene and atorvastatin. She had a history of cigarette smoking, one-half pack per day from ages 18 to 22, and reported alcohol intake of one glass of wine per day. Extraoral examination of the head and neck was WNL. Intraorally, white, plaque-like changes that did not rub off were present on the upper right facial gingiva, in the area of teeth Nos. 2 to 4 and extending posteriorly to the right maxillary tuberosity (**FIGURES 2A AND 2B**). Palatal gingiva was WNL. All areas were toluidine blue negative. The clinical impression was leukoplakia. A biopsy of the facial gingiva associated with tooth No. 2 area showed “moderate epithelial dysplasia.” Laser vaporization was completed from July to August 2007, with complete resolution of the leukoplakia. She has been followed periodically with no recurrence as of her last clinic visit in January 2012, more than four years after completion of the laser excision.

#### Case 3: December 2006

A 76-year-old Caucasian woman with chief complaint of “white lesions.” These changes were first noticed by her general dentist and were asymptomatic and of unknown duration. Her medical history included hypertension, arthritis and breast cancer diagnosed in 1977. Her medications included felodipine, losartan, hydrochlorothiazide, clonidine, atenolol, dexchlorpheniramine maleate and aspirin. She reported allergies to latex, chrome and nickel. She had never smoked and did not consume any alcohol.

Extraoral examination of the head and neck was WNL. Intraorally, white, plaque-like changes that did not rub off were present on the upper facial gingiva, in the area of teeth Nos. 3-4 and Nos. 8-13 (**FIGURES 3A AND 3B**). Palatal gingiva was WNL. The clinical impression was leukoplakia. A biopsy of the facial gingiva in the area of tooth No. 9 showed “hyperkeratosis without dysplasia.” A subsequent biopsy of facial gingiva in the area of tooth No. 12 showed “verruciform hyperkeratosis without dysplasia.” Laser vaporization of leukoplakia on facial gingival in the area of teeth Nos. 8-13 was completed between December 2006 and January 2007, with resolution of the leukoplakia. She was followed periodically with no recurrence as of her last clinic visit in November 2007, about one year after completion of the laser vaporization.

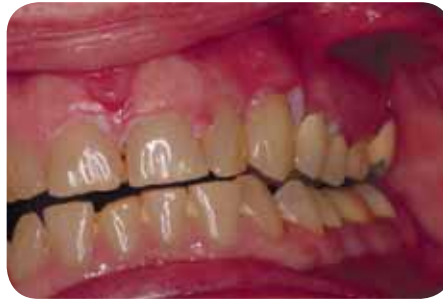#### Case 4: March 2002

A 52-year-old Caucasian woman with chief complaint of “white lesions in the mouth.” These changes were first noticed by her general dentist and were asymptomatic and of unknown duration. Her medical history was significant for hypertension, multiple sclerosis and chronic facial pain. Her medications included interferon

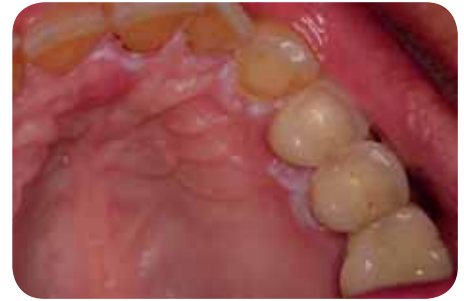beta 1a, carbamazepine, fosinopril, tolterodine, sertraline hydrochloride and progesterone. She had never smoked and did not consume any alcohol. She lived in Southern California and was seeing her local dentist and otolaryngologist for oral examinations between appointments at the University of California, San Francisco.

Extraoral examination of the head and neck was WNL. Intraorally, white, plaque-like changes that did not rub off and had a slightly verrucous surface were present on the upper facial, interproximal and palatal gingiva, in the area of teeth Nos. 8-13 (**FIGURES 4A AND 4B**). The clinical impression was leukoplakia. A biopsy of the anterior facial gingiva showed “atypical papillary-verruciform proliferation.”

Serial laser excision and vaporization procedures of the leukoplakia on the facial gingiva in the area of teeth Nos. 8-13 were completed. At each visit, the palatal, facial and interproximal areas of segments of the leukoplakia and the underlying connective tissue in that segment (up to the periosteum) were excised and vaporized using a carbon dioxide laser and a curette. However, after each procedure the leukoplakia recurred. Each time the recurrences occurred within about two to three months. The last laser procedure was done in 2006, following which it was decided to manage her by close follow-up to monitor for progression and the need for more extensive surgical treatment. From 2008 onward the patient was being followed by her local otolaryngologist. The oral changes progressed over time and at the last contact with her physicians in 2011 it was noted that the changes had slowly progressed to a verrucous carcinoma, and a partial maxillectomy was planned.

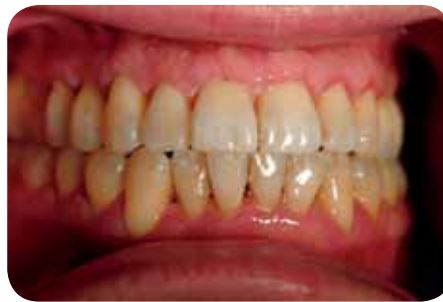

**FIGURE 4A.**

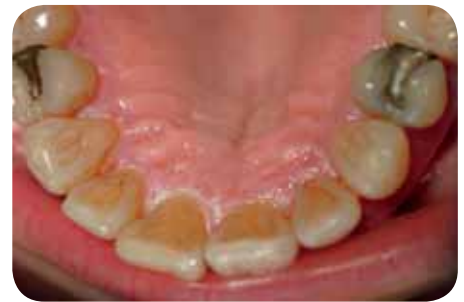

**FIGURE 4B.**

**FIGURES 4A AND 4B.** White, plaque-like changes on the facial and palatal gingiva in the area of teeth Nos. 8 to 14 with involvement of the marginal and interproximal gingiva.



**FIGURE 5A.**



**FIGURE 5B.**

**FIGURES 5A AND 5B.** White, flat, plaque-like changes on the facial and palatal gingiva in the area of teeth Nos. 4 to 11 were present. Changes were mainly on the marginal gingiva, and extended into the interproximal areas between the teeth.

### Case 5: January 2002

A 44-year-old male referred with “white changes on the gingiva.” These changes were first noticed about four years ago by his general dentist who suspected lichen planus. Patient had slight sensitivity on flossing. He had a history of psoriasis and the only medication he was using was topical hydrocortisone on the skin. He had never smoked and was a social drinker.

Extraoral examination of the head and neck was WNL. Intraorally, smooth, white, plaque-like changes that did not rub off were present on the upper facial, interproximal and palatal gingiva, in the area of teeth Nos. 4-10 (**FIGURES 5A AND 5B**). The clinical impression was leukoplakia. A biopsy of the facial gingiva associated with tooth No. 5 showed “focal hyperkeratosis with mild dysplasia.”

Serial laser excision and vaporization procedures of the leukoplakia in area of teeth Nos. 4-10 were completed. Over four separate visits, a localized area of gingiva within the region between teeth

Nos. 4 and 10 was treated. This involved vaporization and removal of the palatal, facial and interproximal areas of segments of the leukoplakia and the underlying connective tissue in that segment (up to the periosteum) using a carbon dioxide laser and a curette. However, after each procedure the leukoplakia recurred. It was therefore decided to manage the oral condition by follow-up examinations to monitor for progression and the need for any surgical treatment. At the most recent follow-up examination in September 2011, the leukoplakia remained stable without any evidence of spread or neoplastic activity.

### Discussion

For persistent leukoplakia, a risk for possible malignant transformation exists. Therefore, removal as a prophylactic measure must be considered. Transformation rates for leukoplakia vary greatly, with presence of certain clinical features indicating an increased risk for malignant transformation,

CONTINUES ON 765

# Print, meet digital.



Delivered to your mobile device each month, the ePub *Journal* includes dynamic interactivity, such as embedded videos and one-click web and email links for more information, as well as the ability to “clip” an article or photo and share it through social media or email. Available for iPad, iPhone, Android and Amazon Kindle Fire. Check it out at [cda.org/mobile](http://cda.org/mobile)



# Mobility Central.

This is your command center for all things CDA. Where every CDA app and ePub is right at your fingertips with your iPhone, iPad or Android. Now you can engage and connect with the content you need, how you need it. Mobility. It's a beautiful thing.



## myCDAvoice App

Voice your views with CDA on everything from new products and services to policy decisions that will shape the profession. Simply download the free app, create a profile and prepare to speak your mind.



## Update ePub

Read the ePub version of Update to enjoy additional content such as embedded videos and one-click web and email links. Special issues (such as *CDA Presents* Preliminary Program and On-Site Guide) also delivered via this ePub. Also available on Amazon Kindle Fire.



## Journal ePub

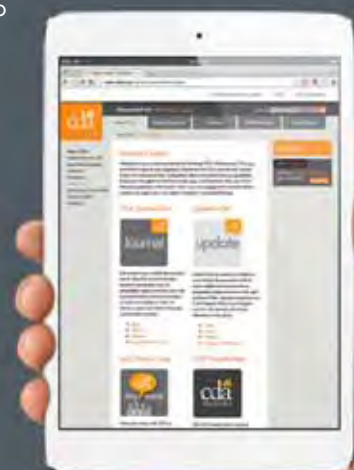The free ePub Journal includes dynamic interactivity such as embedded videos and one-click web and email links for more information, as well as the ability to "clip" an article or photo and share it through social media or email. Also available on Amazon Kindle Fire.



## CDA Presents App

The *CDA Presents* app places all the event information at your fingertips: exhibitors, conferences, speakers, special events, floor plans, hotels and much more.

[cda.org/mobile](http://cda.org/mobile)



CONTINUED FROM 762

including older age, longer duration, female sex, site (floor of mouth and lateral tongue are high-risk sites), speckled, nodular or verrucous appearance and greater size.<sup>11</sup> In addition, presence of dysplasia in the microscopic examination indicates an increased risk for malignant transformation. A strange paradox exists in patients with leukoplakia who don't smoke — there appears to be an increased risk for malignant transformation.<sup>11</sup>

In the surgical management of leukoplakia, the use of the CO<sub>2</sub> laser allows the consideration of a more conservative approach at the outset, with a major advantage of CO<sub>2</sub> laser vaporization being less scarring and therefore less morbidity for patients. Gingival leukoplakias pose additional difficulties because of the presence of teeth and potential extensions into the periodontal ligament, which limit surgical access, when using a scalpel or a CO<sub>2</sub> laser.

The CO<sub>2</sub> laser (wavelength 10600 nm) has several advantages when used in treatment of oral leukoplakia. This laser is well suited for use in ablation of soft tissue. It allows for very precise control of the extent of vaporization with concomitant blood vessel coagulation allowing a bloodless field and clear visibility. The ability to use it in noncontact mode allows better access in hard-to-reach areas in the oral cavity. The healing of CO<sub>2</sub> laser wounds results in less scarring as compared to scalpel wounds. In addition, minimal penetration of CO<sub>2</sub> laser energy beyond the treated area minimizes damage to underlying tissue.<sup>3-10</sup> In this case series, although the leukoplakia was on the gingival mucosa overlying alveolar bone, and the tissue ablation was to the level of the periosteum, complications of bone necrosis and sequestration were not observed.

In the successful treatment of leukoplakia, it is essential that all of the epithelium is ablated, without any islands

of epithelia left behind. If viable epithelial cells are inadvertently left behind, a partial or complete recurrence of the leukoplakia may occur. To minimize the possibility of leaving behind any viable epithelial cells, the CO<sub>2</sub> laser should be used in continuous mode rather than pulsed mode, and the ablation should start at one margin and systematically proceed with overlapping passes of the laser energy until ablation at the entire delineated site is completed.

In this case series of five patients, the two who had recurrences had involvement of the marginal and interproximal gingiva with lesions extending from the facial to the palatal gingiva. The three patients who did not have recurrences had minimal involvement of the marginal gingiva with the lesions confined to the facial gingiva, giving better accessibility to the margins during laser vaporization.

Also, clinical appearance may have some predictive value. Between the two patients who did have recurrences, the patient who presented with flat, smooth leukoplakia showed no progression of the lesions over nine years of follow-up, while the patient who presented with verrucous leukoplakia showed eventual progression to a verrucous carcinoma.

The microscopic appearance of the leukoplakias for case 3 (verruciform hyperkeratosis without dysplasia) and case 4 (atypical papillary-verruciform proliferation) suggest an increased risk for malignant transformation. This form of leukoplakia is consistent with proliferative verrucous leukoplakia.<sup>12</sup>

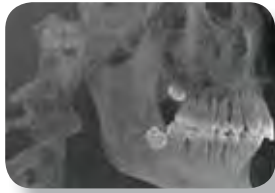In summary, the risk of recurrence of leukoplakia after laser excision may vary based upon the clinical characteristics of the lesion. Presence of gingival leukoplakia on both facial and palatal/lingual aspect, through the interproximal areas, may increase the risk of recurrence after surgical removal. This suggests that early

intervention in patients with leukoplakia limited to the facial or lingual aspect may be important, as extension of the gingival leukoplakia may significantly change the prognosis. Prospective studies on the risk of recurrence of oral leukoplakias for different subgroups of leukoplakia defined by accessibility of margins, site, size and clinical appearance of the lesions are needed. This will provide better estimates of the risk of recurrence according to lesion characteristics, which will help individual patients and their clinicians make treatment decisions. ■■■■

## REFERENCES

1. Warnakulasuriya S, Johnson NW, van der Waal I. Nomenclature and classification of potentially malignant disorders of the oral mucosa. *J Oral Pathol Med* 2007;36(10):575-580.
2. Van Der Waal I. Potentially Malignant Disorders of the Oral Oropharyngeal Mucosa; terminology, classification and present concepts of management. *Oral Oncol* 2009; 45: 317-323.
3. Van Der Hem PS, Nauta JM, Van Der Wal JE, Roodenburg JL. The results of CO<sub>2</sub> laser surgery in patients with oral leukoplakia: 25 year follow up. *Oral Oncol* 2005; 41(1): 31-37.
4. Silverman S Jr. Early diagnosis of oral cancer. *Cancer* 1988; 68(8 Suppl): 1796-9.
5. Roodenburg JL, Panders AK, Vermey A. Carbon dioxide laser surgery of oral leukoplakia. *Oral Surg Oral Med Oral Pathol* 1991; 71(6): 670-674.
6. Horch HH, Gerlach KL, Schaefer HE. CO<sub>2</sub> laser surgery of oral premalignant lesions. *Int J Oral Maxillofac Surg* 1986; 15(1):19-24.
7. White JM, Chaudhry SI, Kudler JJ, Sekandari N, Schoelch ML, Silverman S Jr. Nd:YAG and CO<sub>2</sub> laser therapy of oral mucosal lesions. *J Clin Laser Med Surg* 1998; 16(6): 299-304.
8. Schoelch ML, Sekandari N, Regezi JA, Silverman S Jr. Laser management of oral leukoplakias: a follow-up study of 70 patients. *Laryngoscope* 1999; 109(6): 949-53.
9. Thompson PJ, Wylie J. Interventional laser surgery: an effective surgical and diagnostic tool in oral precancer management. *Int J Oral Maxillofac Surg* 2002; 31(2): 145-53.
10. Ishii J, Fujita K, Komori T. Laser surgery as a treatment for oral leukoplakia. *Oral Oncol* 2003; 39(8): 759-69.
11. Napier SS, Speight PM. Natural history of potentially malignant oral lesions and conditions: an overview of the literature. *J Oral Pathol Med* 2008; 37(1):1-10.
12. Fetting A, Pogrel MA, Silverman S Jr, Bramanti TE, Da Costa M, Regezi JA. Proliferative verrucous leukoplakia of the gingiva. *Oral Surg Oral Med Oral Pathol Oral Radiol Endod* 2000; 90(6):723-30.

THE CORRESPONDING AUTHOR, Nita Chainani-Wu, DMD, MS, PhD, can be reached at nita.wu@ucsf.edu.



# Coronoid Hyperplasia in a Pediatric Patient: Case Report and Review of the Literature

ROBERT A. UTSMAN, DDS; GARY D. KLASSER, DMD; AND MARIELLA PADILLA, DDS, MS

**ABSTRACT** Coronoid hyperplasia is a rare entity of unknown etiology due to increased and persistent bone growth that has been associated with trauma, inflammation, hormonal influence and hypervascularization. A case of coronoid hyperplasia in a pediatric patient with restriction in mandibular movements and an absence of painful symptoms initially misdiagnosed as a functional temporomandibular joint (TMJ) abnormality is presented. Causative factors and management strategies are emphasized to enhance the recognition and understanding of mandibular hypomobilities.

## AUTHORS

**Robert A. Utsman, DDS,** is a professor and director of research at the School of Health Sciences at Latin-American University of Science and Technology (ULACIT) in San Jose, Costa Rica.  
*Conflict of Interest Disclosure: None reported.*

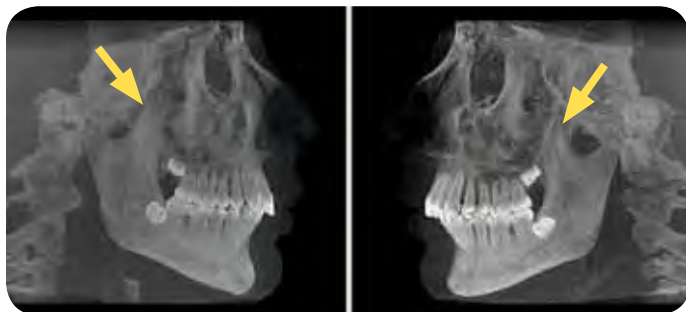**Gary D. Klasser, DMD,** is an associate professor in the Division of Diagnostic Sciences at Louisiana State University School of Dentistry in New Orleans.  
*Conflict of Interest Disclosure: None reported.*

**Mariella Padilla, DDS, MS,** is the dean of the School of Health Sciences at ULACIT.  
*Conflict of Interest Disclosure: None reported.*

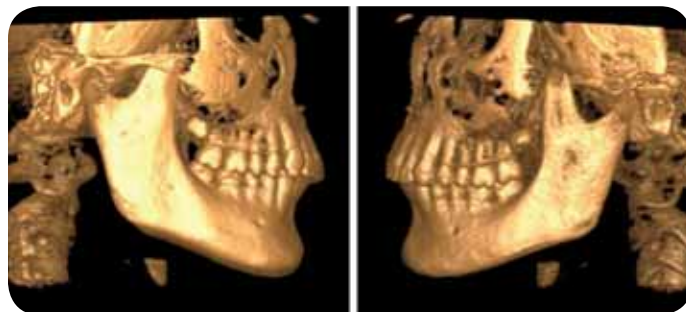
**H**yperplasia of the mandibular coronoid process (coronoid hyperplasia) in the adult population is an infrequent finding often associated with a presentation of restricted mandibular opening. Historically, reports of enlargement of the coronoid process may be found in the literature as early as 1853.<sup>1</sup> Coronoid hyperplasia, also known as coronoid impendence, is a disorder of unknown etiology of increased and persistent bone growth that has been associated with trauma, inflammation, hormonal influence and hypervascularization.<sup>2,3</sup> Aside from the clinical presentation of hypomobility, progressive unilateral enlargement can result in facial asymmetry, malocclusion

and shifting of the midpoint of the chin to the unaffected side.<sup>2,3</sup>

Epidemiologically, coronoid hyperplasia displays no ethnic predilection with cases reported in Caucasians, Blacks and Asians.<sup>4</sup> Coronoid hyperplasia may be present bilaterally or unilaterally. Bilateral coronoid hyperplasia presents with a male to female ratio of 5:1 and a mean age of 27.8 years while a unilateral presentation has a slightly less male preponderance of 4.7:1 and occurs in a younger population (mean age of 23.6 years).<sup>2</sup> Interestingly, symptoms often predate presentation by a mean of 9.0 years for bilateral and 6.75 years for unilateral cases.<sup>2</sup> The youngest patient reported in the literature is a case of bilateral coronoid hyperplasia in a neonate.<sup>5</sup>



**FIGURE 1.** Cone beam computed tomography showing the lateral comparison of the elongated bilateral coronoid process (arrows indicate elongation in the right > left).



**FIGURE 2.** Lateral comparison of the three-dimensional cone beam computed tomography revealing bilateral coronoid hyperplasia (right > left).

In the pediatric population (under the age of 12), coronoid hyperplasia is a rare entity. It has been reported bilaterally in only 21 pediatric cases<sup>6</sup> when not associated with other signs and symptoms, and unilaterally in only two cases.<sup>7,8</sup> An absence of painful symptoms and misdiagnosis as a functional temporomandibular joint (TMJ) abnormality makes it important for dentists to recognize and understand that mandibular hypomobilities such as coronoid hyperplasia should not to be dismissed, but thoroughly investigated to uncover the reason for the restriction in mandibular movements. A differential diagnosis based upon a thorough history and comprehensive examination with appropriate imaging and serologic testing to exclude systemic diseases should ensue, followed by the delivery of a well-designed plan of management. This case report of a 12-year-old Hispanic male with a predominantly right coronoid hyperplasia highlights the importance of diagnosis and management. The consequences from a lack of recognizing and appreciating etiology and clinical features of hypomobility resulting in adverse physical and psychosocial growth and development issues are discussed.

### Case Report

A 12-year-old Hispanic male was referred to the Latin-American University of Science and Technology (ULACIT) Orofacial Pain Faculty Practice

for evaluation of a pain-free but severely limited mandibular opening. Upon taking history, the patient, accompanied by an adult guardian, reported his chief complaint was the need for orthodontic care to resolve his restricted mandibular opening. Members of his family recalled initially noticing restriction in his mandibular opening approximately three years prior. He indicated his ability for mandibular opening had become more strained and restricted over the last year, recently becoming embarrassed at a birthday party because of his inability to open wide when eating a hamburger with friends. Family members indicated they believed this “inability to open” was merely a part of normal pubertal growth and thought that resolution would occur with time. Prior to visiting the clinic at ULACIT, he visited several clinicians, and the patient was repeatedly informed that he was experiencing TMJ disorder. There was no previous or current history of trauma to the mandible or familial history of similar abnormalities, and his medical history was unremarkable.

Extraoral clinical examination revealed no lymphadenopathy and there was no noticeable facial asymmetry. There was no tenderness/pain elicited upon digital palpation in the masticatory musculature or in the lateral capsules of the TMJ region. There were no intracapsular sounds identified. Intraoral clinical examination detected a well-aligned class I occlusion on the

left with a class II occlusion on the right, with no deviation/deflection in the mandibular opening. However, there was limited range of mandibular movements (opening and excursive movements). Both maximum assisted and unassisted mandibular openings were restricted to 15 mm with lateral movements to the left and right being 1 mm and 4 mm, respectively. He was unable to perform protrusive mandibular movements. A previous panoramic radiograph taken approximately three months prior to his initial visit was reviewed, but it was of poor quality and therefore deemed nondiagnostic. A cone beam computed tomography (CBCT) using i-CAT Vision software was obtained and displayed an elongated bilateral coronoid process, with a larger elongation in the right (**FIGURES 1 AND 2**), with no other TMJ remarkable findings. Based on the history, clinical examination, radiographic findings and negative serological investigations, a diagnosis of bilateral (right > left) coronoid hyperplasia was delivered.

The management plan consisted of explaining and educating the patient and his adult guardian on the findings. The patient was instructed and shown methods to maintain mandibular mobility with the goal of preventing further decrease in his maximum opening. These involved the provision of daily mouth opening exercises emphasizing rotation,



relaxation and stretch, with the latter employing sequential stacking tongue depressors. The purposes of these self-applied exercises were to avoid long-term sequelae such as myostatic or myofibrotic contracture and/or fibrous or bony ankylosis.<sup>9</sup> Unfortunately, the yield from these patient care instructions may only have a minimal effect on the long-term outcome. He was subsequently referred to the Costa Rican National Children's Hospital Department of Pediatric Dentistry, and is currently awaiting surgical intervention. He was recalled for a follow-up examination two months after his initial consult whereby no change in his range of mandibular opening or existing occlusion was detected.

## Discussion

Coronoid hyperplasia is characterized by a gradual and progressive limitation in mandibular movements usually starting at puberty. In many cases,<sup>2,7</sup> patients do not see their limited mandibular movements as a valid reason to seek professional attention because the restriction is usually not painful. In the case presented, the mandibular opening, in addition to lateral and protrusive movements of the mandible, was restricted because of the obstruction caused by the enlarged coronoid process against the zygomatic arch. Other clinical symptoms and signs reported in the literature are a mobile lump above the zygomatic arch, facial asymmetry and pain on mandibular opening,<sup>10</sup> which were absent in our case report. Clinically, it is difficult to differentiate between unilateral and bilateral cases, with abnormalities in both cases of decreased mouth opening, often accompanied with facial pain, making it likely that a continuous spectrum exists rather than two separate entities.<sup>7</sup>

The etiology of coronoid hyperplasia is not well understood, and several theories have been proposed. Hall et al.<sup>11</sup> hypothesized that coronoid hyperplasia results from a developmental bone defect in neoplastic or cartilaginous growth centers of the coronoid processes, causing continued growth and hyperplasia. It has also been suggested that decreased mouth opening leads to an increased pull or activity of the temporalis muscle, thus creating an enlargement of the coronoid process.<sup>12,13</sup> Trauma has also been

**CORONOID HYPERPLASIA**  
is characterized by a gradual  
and progressive limitation  
in mandibular movements  
usually starting at puberty.

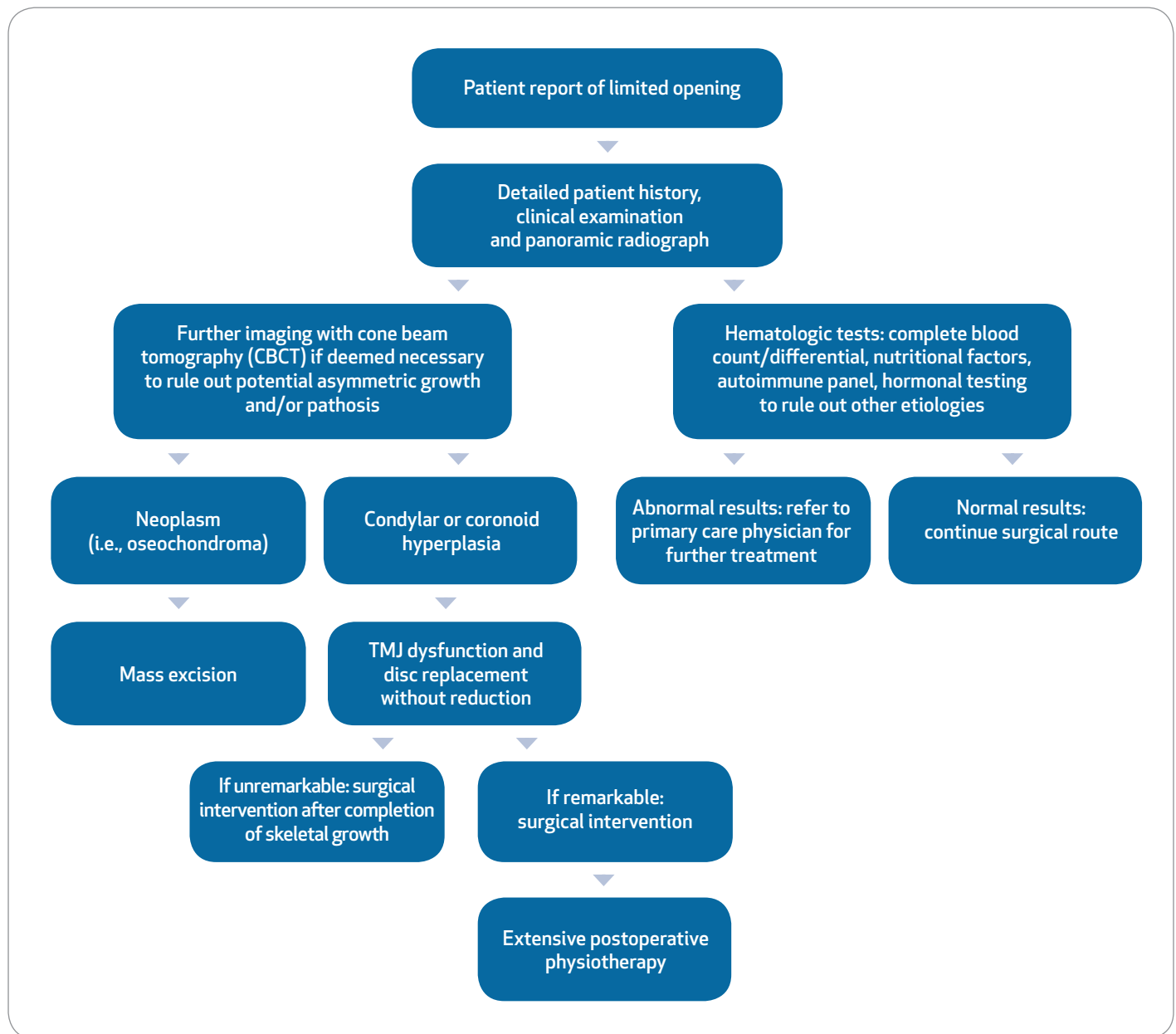
implicated; however, a causal relationship with trauma has not been well established because the majority of reported cases do not present with a history of trauma.<sup>14</sup> Hereditary or familial etiology has also been implicated in the pathogenesis of coronoid hyperplasia with reported instances of this developmental condition occurring in two members of a family.<sup>15,16</sup> However, there is no strong evidence to give firm support to this hypothesis. Similar symptoms have also been associated with trismus-pseudocamptodactyly syndrome, a rare hereditary condition associated with multiple joint contractures caused by uterine akinesia.<sup>6,17</sup> Most recently a hypotheses was proposed that coronoid hyperplasia is independent of the underlying etiological factor causing trismus in these conditions, and the bone

overgrowth is a compensatory hyperplasia from coronoid hypertrophy and temporalis hyperactivity rather than a direct effect of the disease process.<sup>18</sup>

The utility of radiographic imaging as an adjunct to the diagnostic process cannot be overlooked.<sup>19,20</sup> Plain radiographs, such as panoramic radiography, are valuable screening tools when clinical symptoms and signs are present, such as those manifested when coronoid process hyperplasia is suspected, and thus, indicated.<sup>4</sup> Interpretation of radiographic findings visualized on the panoramic radiograph may lead to further advanced radiographic imaging. In this case report, a CBCT was utilized to provide detailed imaging of the coronoid processes and the relationship to the zygomatic bone. Additionally, the results of this imaging will be very beneficial for the evaluation and the planning of the surgical aspects to improve mandibular mobility.

Supportive treatment involving physical therapy (self-administered and/or professional) is essential in the attempt to increase mobility and to prevent long-term sequelae such as myostatic or myofibrotic contracture and/or fibrous or bony ankylosis.<sup>2,4-8</sup> Manual techniques such as isotonic and isometric exercises along with other modalities, such as ultrasound and thermotherapy, should be employed both pre-operatively and postoperatively. These interventions will assist in a positive outcome and in the minimization and/or avoidance of post surgical complications such as surgically induced fibrosis or ankylosis and the tendency for coronoid process regrowth.<sup>6,7,21</sup>

The definitive treatment for coronoid hyperplasia involves surgical intervention, which generally entails a coronoidectomy, coronoidotomy, masseteric stripping or temporalis myotomy.<sup>2,6,7,18,22,23</sup> Intervention



**FIGURE 3.** Algorithm for diagnosis and management of coronoid hyperplasia.

is based on the severity and progression of symptoms and, in mild cases, should be delayed until early skeletal maturity.<sup>4,7,22-24</sup> Severe coronoid hyperplasia has the potential to reduce dentofacial skeletal development and harmonious growth, impeding the normal growth and development of the facial skeleton, proper speech and dental occlusion.<sup>7,22,23</sup> Early surgical intervention, however,

is still debatable because of difficult surgical exposure and compliance with postoperative functional therapy.<sup>4-8</sup> Our treatment strategies were based on prior studies.<sup>2,6,7,18,22-25</sup> An algorithm for the diagnosis and management of coronoid hyperplasia is shown in **FIGURE 3**. The results of any surgical/physical strategy can only be confirmed by an appropriate and prolonged clinical and radiologic follow-up.

## Conclusions

In the case presented, the patient experienced a restricted mandibular opening for more than three years. Although a panoramic radiograph was performed, several clinicians could not detect the elongated coronoid process while providing a misdirected diagnosis focused upon TMJ. Unfortunately, this lack of recognition prevented a definitive

diagnosis and delayed surgical intervention. This delay, which is similar to that reported by Tavassol et al.<sup>19</sup> (median of two years), may have compromised or complicated the surgical approach and possible outcome. The necessity of implementing a detailed history and comprehensive examination with the adjunctive diagnostic instruments, such as radiographic imaging, cannot be overemphasized. An elongated coronoid process is indisputably a rare cause of restricted mandibular opening; however, knowledge of its existence can preserve patients from months of unneeded costs and lost time resulting in misdiagnosis, inappropriate/incorrect management and delay in resolution. ■■■■■


## REFERENCES


1. Langenbeck B. Angeborene Kleinert der Unterkiefer. *Langenbecks Arch Surg* 1861;1:451.
2. McLoughlin PM, Hopper C, Bowley NB. Hyperplasia of the mandibular coronoid process: an analysis of 31 cases and a review of the literature. *J Oral Maxillofac Surg* 1995 Mar; 53(3):250-5.
3. Rajmakers PG, Karssemakers LH, Tuinzing DB. Female predominance and effect of gender on unilateral condylar hyperplasia: a review and meta-analysis. *J Oral Maxillofac Surg* 2012 Jan; 70(1):e72-6.
4. Iqbal S, Hamid AL, Purmal K. Unilateral coronoid hyperplasia following trauma: a case report. *Dent Traumatol* 2009 Dec; 25(6):626-30. Epub 2009 Oct 14.
5. Fabie L, Boutault F, Gas C, Paoli JR. Neonatal bilateral idiopathic hyperplasia of the coronoid processes: case report. *J Oral Maxillofac Surg* 2002 Apr; 60(4):459-62.
6. Jaskolka MS, Eppley BL, van Aalst JA. Mandibular coronoid hyperplasia in pediatric patients. *J Craniofac Surg* 2007 Jul; 18(4):849-54.
7. Galiè M, Consorti G, Tieghi R, Denes SA, Fainardi E, Schmid JL, Neusch M, Clauser L. Early surgical treatment in unilateral coronoid hyperplasia and facial asymmetry. *J Craniofac Surg* 2010 Jan; 21(1):129-33.
8. Lucaya J, Herrera M, Vera J. Unilateral hyperplasia of the coronoid process in a child: a cause of restricted opening of the mouth. *Radiology* 1982 Aug; 144(3):528.
9. Okeson JP. *Management of Temporomandibular Disorders and Occlusion*, 6th ed. St. Louis: CV Mosby, 2007: 457-460.
10. Tucker MR, Guilford WB, Howard CW. Coronoid process hyperplasia causing restricted opening and facial asymmetry. *Oral Surg Oral Med Oral Pathol* 1984 Aug; 58(2):130-2.
11. Hall RE, Orbach S, Landesberg R. Bilateral hyperplasia of the mandibular coronoid processes: a report of two cases. *Oral Surg Oral Med Oral Pathol* 1989 Feb; 67(2):141-5.
12. Lyon LZ, Sarnat BG. Limited opening of the mouth caused by enlarged coronoid processes: report of case. *J Am Dent Assoc* 1963 Nov; 67:644-50.
13. Isberg A, Isacson G, Nah KS. Mandibular coronoid process locking: a prospective study of frequency and association with internal derangement of the temporomandibular joint. *Oral Surg Oral Med Oral Pathol* 1987 Mar; 63(3):275-9.
14. Tucker MR, Guilford WB, Howard CW. Coronoid process hyperplasia causing restricted opening and facial asymmetry. *Oral Surg Oral Med Oral Pathol* 1984 Aug; 58(2):130-132.
15. York BV, Cockerham S. Bilateral hyperplasia of the coronoid processes in siblings. *Oral Surg Oral Med Oral Pathol* 1983 Dec; 56(6):584-5.
16. Marra LM. Bilateral coronoid hyperplasia, a developmental defect. *Oral Surg Oral Med Oral Pathol* 1983 Jan; 55(1):10-3.
17. Yamashita DDR, Arnet GF. Trismus pseudocamptodactyly syndrome. *J Oral Surg* 1980 Aug; 38(8):625-630.
18. Chakranarayan A, Jeyaraj P. Coronoid hyperplasia in chronic progressive trismus. *Med Hypotheses* 2011 Nov; 77(5):863-8. Epub 2011 Aug 23.
19. Tavassol F, Spalthoff S, Essig H, Bredt M, Gellrich NC, Kokemüller H. Elongated coronoid process: CT-based quantitative analysis of the coronoid process and review of literature. *Int J Oral Maxillofac Surg* 2012 Mar; 41(3):331-8. Epub 2011 Dec 20.
20. Nah KS. Condylar bony changes in patients with temporomandibular disorders: a CBCT study. *Imaging Sci Dent* 2012 Dec; 42(4):249-53. doi: 10.5624/isd.2012.42.4.249. Epub 2012 Dec 23.
21. Loh HS, Ling SY, Lian CB, Shanmugasuntharam P. Bilateral coronoid hyperplasia — a report with a view on its management. *J Oral Rehabil* 1997 Oct; 24(10):782-7.
22. Mehrotra D, Dhasmana S, Kamboj M, Gambhir G. Condylar hyperplasia and facial asymmetry: report of five cases. *J Maxillofac Oral Surg* 2011 Mar; 10(1):50-6. doi: 10.1007/s12663-010-0141-5. Epub 2011 Feb 4.
23. Costa YM, Porporatti AL, Stuginski-Barbosa J, Cassano DS, Bonjardim LR, Conti PC. Coronoid process hyperplasia: an unusual cause of mandibular hypomobility. *Braz Dent J* 2012;23(3):252-5.
24. Sleeman D, Warren E, McAuliffe M. Unilateral coronoid hyperplasia associated with early childhood facial trauma: a case presentation. *J Ir Dent Assoc* 2012 Aug-Sep; 58(4):212-4.
25. Ponsford MW, Stella JP. Algorithm for the differential diagnosis of posterior open bites: two illustrative cases. *J Oral Maxillofac Surg* 2013 Jan; 71(1):110-27.

THE CORRESPONDING AUTHOR, Robert A. Utsman, DDS, can be reached at rutsmana282@ulacit.ed.cr.



**Top Splinting Material**  
visit us at ADA, Booth #2359







EUROPEAN UNION  
EUROPEAN REGIONAL DEVELOPMENT FUND  
INVESTMENT IN YOUR FUTURE

**Dentapreg America Inc.**  
1819 Main Street, Suite 200A 34236 Sarasota  
FL / Tel.: +(1) 866-697-5266  
Fax: +(1) 941-925-2913  
mail: debbie.dentapreg@gmail.com

Manufactured by: ADM, a.s., U Vodáreny 2, 616 00 Brno, Czech Republic



**20% OFF**

**Coupon code: DenUS13**  
Valid until 11/30/2013 only  
[www.dentapreg.com](http://www.dentapreg.com)





help highlight and enforce certain aspects of treatments the patient may have a hard time fully grasping. The functionality of the app is simple. Animations are grouped into categories from which users can select a desired video. For the interactive version, an added sidebar exists for the drawing feature. Users can also erase and trash a given drawing, and tabs for emailing and saving are easy to see toward the bottom of the page. The market for interactive animated dental education software will continue to grow and Dentapedia is one such software that allows dentists and offices to educate and better explain treatment at a fairly economical entry-level cost.

From the founders of YouTube comes Mixbit, an app designed for users to create videos with fun and intuitive tools. Users record video by simply tapping and holding a record button on the screen for the duration of the recording. The app splits the recording into multiple clips lasting 16 seconds each. Users can take any combination of up to 256 clips (about an hour) to create a video project, which can be published to the Mixbit website and shared to a Twitter or Facebook account. The most creative feature of Mixbit is the ability to use clips from published videos of other users to create custom collaborative video projects called remixes. When viewing published videos, users simply tap and hold a clip of their choice until a green check appears to make it available for use in their own projects. While users can select these clips through the app, the ability to create a remix is currently available only through the Mixbit website. Telling creative stories through video is now possible and fun with Mixbit.

OCTOBER 2013 771



**Triplt Travel Organizer (Triplt, Inc., Free)**

Whether it's business or leisure, dentists are frequently in the air catching C.E. courses and dental meetings, or vacationing with family. Coordinating flights, hotels and the like can be confusing and scattered between emails, printouts or hand-written calendars. Available in either ad-supported or ad-free versions, Triplt allows users to pool multiple flights, hotel stays and reservations in an easy-to-view format. Users can manually enter all travel information or forward travel emails to Triplt. It can also automatically import itineraries directly from Gmail. It does this by scanning the users' inbox for travel information via a secure protocol the company says safely links its email to Triplt without the need for an email password. This can be shut off easily through the app or the users' email settings. Weather updates and maps displaying exactly where the user is and where they're trying to go are also free functions. Triplt Pro is also available for a yearly fee and includes check-in reminders, fare tracking, changes in flight status and a seat upgrade alert based on personal preferences.

—Darien Hakimian, DDS

**Twitter Update (Twitter Inc., Free)**

The screen is not broken, that line connecting tweets on Twitter is here to help. Conversations on Twitter have traditionally been difficult to follow, but the microblogging site recently released an update to help streamline the process. Those using Twitter.com or the apps for the iPhone and Android devices, will now see a line that links conversations in chronological order. Users will need to be following both participants to see the conversation. Prior to the update, tweets that were part of a conversation were scattered throughout a users' timeline with little context. The update adds more of a traditional social network feel that resembles the comment section on Facebook posts. Also included in the Twitter update is a button that allows users to report abuse on Android devices and Twitter.com as a way to curb online harassment. The button was already available on the iPhone. In addition, Twitter reduced the size of the app for "entry-level" Android devices with limited storage space to help make it easier to install.

—Blake Ellington, Tech Trends Editor

**CDA Update/Journal "ePubs"****(California Dental Association, Free)**

CDA recently made its *Journal* and *Update* publications available in a new electronic format optimized for tablet and mobile reading. The new "ePub" (electronic publication) format provides greater interactivity, allowing CDA to deliver additional content such as embedded videos, links to websites and email addresses and a dynamic "clippings" feature, which allows users to use a two-finger "touch" to select an article or photo and easily share out to social media networks. The ePubs also offer readers a more streamlined process for obtaining further information as it relates to the printed articles. When studies and reports are referred to in the *Journal*, for example, the ePub allows users to click a link and be taken directly to those reports. In addition, special publications (such as the *CDA Presents On-Site Guide*) will also be made available in electronic format via the ePubs. The *Update* and *Journal* ePubs function on all major tablets and smartphones that use the iOS, Android or Kindle Fire platforms. Both ePubs operate on the MAZ app platform, which is used by hundreds of major magazines including *Inc.* and *Forbes*. For more information and to download, visit [cda.org/apps](http://cda.org/apps).

—Blaine Wasylkiw, director of online services, CDA

**Would you like to write about new technology?**

Dentists interested in contributing to this section should contact Tech Trends Editor Blake Ellington at [blake.ellington@cda.org](mailto:blake.ellington@cda.org).

cda.org/jobs →



The new cda.org classifieds work harder than ever. From job listings to practice or equipment sales, it's all **free** to CDA members. Check it out at [cda.org/classifieds](https://cda.org/classifieds).



# Specializing in the Selling and Appraising of Dental Practices



**CALIFORNIA  
PRACTICE SALES INC.**

Serving California Since 1974

**"Your local Southern  
California Broker"**

Phone: (714) 639-2775

(800) 697-5656

Fax: (714) 771-1346

Email: [jknipf@aol.com](mailto:jknipf@aol.com)

[rpalumbo@calpracticesales.com](mailto:rpalumbo@calpracticesales.com)

[WWW.CALPRACTICESALES.COM](http://WWW.CALPRACTICESALES.COM)



*John Knipf & Robert Palumbo*

## LOS ANGELES COUNTY

**BEVERLY HILLS** - GP/Perio Prosth emphasis on Perio Surgery & Implants in 4 story med bldg w/ 3ops. Grossed 1M in 2012. ID#4035  
**COVINA** - Leasehold & Equip Only! 3 eq op office located in 1 story med building. Reasonable rent with excellent terms. ID #4355.  
**CULVER CITY** - Leasehold & Equip Only! 10 eq op office in a single story bld. In residential area. Heavy traffic flow. ID #4261.  
**HUNTINGTON PARK** (GP) Price Reduced! Estab. in 2008. In a 2 story free stranding bldg near residential area. Has 4 eq ops. ID#4295.  
**LOS ANGELES** (GP) - Well designed practice w/ 5 eq op in a strip shopping center. 20 years of goodwill. Some Denti-cal. ID#2771.  
**LOS ANGELES** (GP) - Three operatory office located on a 13 story prof bldg. Fee for service. 14 yrs of goodwill. Net \$209K. ID#2831.  
**LOS ANGELES** (GP) - Turn-Key office located in busy small shopping center. 3 operatories. Some Ortho. Near residential area. ID#4367.  
**MONTROSE** - GP w/ 35 yrs of gdwll is located in a residential area w/ great street visibility. 4 ops. Fee for service. ID #4383.  
**PACOIMA** - Leasehold & Equipment Only! Two eq op w/ 1 plmbd not eq office in small strip mall. Charts included. ID #4361.  
**RESEDA** - GP located on a single story bldg w/ heavy traffic flow. 18 year of gdwll. 5 eq operatories. Some Ortho. Net \$235K. ID#4333.  
**TORRANCE** (GP) - Modern designed office w/ 44 yrs of gdwll. Has 3 eq ops, 1 plmbd not eq w/ digital x-ray & Eaglesoft soft. ID#4375.  
**TORRANCE** - GP w/ over 30 yrs of gdwll in 2 story prof med bldg. Consists of 8 eq ops, 1 plmbd not eq in 2,208 sq ft suite. ID #4377.

## ORANGE COUNTY

**ANAHEIM HILLS** - Leasehold & Equipment Only! Beautiful office in busy shopping center w/ 3 eq ops, 1 plmbd not eq. ID #4379.  
**COSTA MESA** - Three (3) eq ops office w/ over 19 yrs of gdwll in busy strip mall. Fee for service. Revenues of \$38K/mo. ID#4365.  
**HUNTINGTON BEACH** (GP) - Fee for service practice w/ 3 eq ops, 3plmbd not eq in a 2,100 sqft ste on a busy street. ID#4395.  
**MISSION VIEGO** (GP) - Well designed turn-key practice w/ 3 eq op & 3 plmbd is located in a prestigious shopping center. ID #4303.  
**SAN CLEMENTE** (GP) - Modern designed turn-key office in 2 story med bldg w/ 4 eq ops, 2 plmbd not eq for expansion. ID 4359.

## RIVERSIDE / SAN BERNARDINO COUNTIES

**APPLE VALLEY** (GP) - Well established practice w/ 5 eq op, 3 plmbd not eq, Dentrux software and digital x-ray. Net \$214K. ID #4349.  
**BARSTOW**(GP) - Long established office w/ 4 eq ops in a single story bldg. Easy freeway access. Fee for service. ID #4241  
**PALM DESERT** (GP) - Well established practice w/ 5 eq ops in 1 story bldg w/ ample parking & excellent signage. Net \$119K. ID#4331.  
**PALM SPRINGS** - Leasehold & Equip Only! Practice located on a busy street w/ 4 eq ops in a 2,000 sq ft office. ID #4387.  
**RIVERSIDE** - Fee for service practice w/ over 50 yrs of gdwll. Modern office w/ 4 eq ops in corner single prof. blfg. ID #4351.

## SAN DIEGO C OUNTY

**CHULA VISTA** (GP) - Located in downtown. Store front. Consists of 4 eq ops 1 plmbd not eq. Some Cap. Net \$152K. # 4279.  
**OCEANSIDE** - Leasehold & Some Equipment Only! Beautiful office in a single shopping center w/ 5 not eq ops in a 1,500 sqft ste. #4363  
**RAMONA** (GP) - Established in 1979 and located in single strip mall. Busy area. Fee for service. Consists of 3 eq op. ID #4305.  
**SAN DIEGO** (GP) - In free standing bldg w/ private prkng. Consists of 5 ops w/ Dentrux software. Monthly revenues of ~\$40K. ID #4279.  
**SAN DIEGO** (GP) - Beautiful Turn-Key practice with 8 eq ops in a modern designed shopping center. Absentee owner. ID #4335.

## VENTURA & SANTA BARBARA COUNTY

**SANTA BARBARA** (GP) - Well established practice w/ 3 eq ops in a 1,100 sqft ste. 100% Cash . Net \$215K. Condo for sale. ID # 4393.

<http://www.calpracticesales.com/blog>

*Call us about Debt Consolidation & Retirement Planning*  
**VISIT OUR WEBSITE [WWW.CALPRACTICESALES.COM](http://WWW.CALPRACTICESALES.COM)**  
**CA DRE#00491323**

John Knipf  
President

*John W Knipf* (Neff)

Also serving you: Robert Palumbo, Executive V. P. /Partner, Alice C. King, V.P.,  
Greg Beamer, V.P., Tina Ochoa, V.P., & Maria Silva, V.P.

## How to Place a Free Classified Ad

The *Journal* has changed its classified advertising policy for CDA members to place free classified ads online and publish in the *Journal*. CDA members can place any classified ad. Non-CDA members can post employment classifieds or place display ads in the *Journal*.

All classified ads must be submitted through [cda.org/classifieds](http://cda.org/classifieds). Fill out the blank fields provided, including whether the ad is to appear online only or online and in the *Journal*. Click "post" to submit your ad in its final form. The ad will post immediately on [cda.org](http://cda.org) and will remain for 90 days. Space permitting, your ad will run one time in the next issue of the *Journal* following the posting of your online ad. After 90 days, you will need to repost your ad if you wish to continue running it online. Note that CDA reserves the right to modify your classified ad for CDA style and to correct typographical errors.

Classified ads for publication in the *Journal* must be submitted by the fifth of every month, prior to the month of publication. Example: Jan. 5 at 9 a.m. is the deadline for the February issue of the *Journal*. If the fifth falls on a weekend or holiday, then the deadline will be 9 a.m. the following workday. After the deadline closes, classified ads for the *Journal* will not be accepted, altered or canceled. Deadlines are firm.

Classified advertisements categories are: Equipment for Sale, Offices for Sale, Offices for Rent or Lease, Available Positions, Opportunities Wanted and Practices for Sale.

### How to Place a Display Ad

Nonmembers are welcome to place display ads. For information on display advertising, please contact Corey Gerhard at 916-554-5304 or [corey.gerhard@cda.org](mailto:corey.gerhard@cda.org).

CDA reserves the right to edit copy and does not assume liability for contents of classified advertising.

## AVAILABLE POSITIONS

### REGISTERED DENTAL ASSISTANT —

Would you like to work in a positive, enjoyable pediatric dentistry office where you can feel proud of the work you do and be recognized for your efforts? If so, look no further. We'd love to have you join our private pediatric specialty dental office in Chino/Chino Hills. If you are interested in this wonderful opportunity, visit our website at [kidsdentalspecialists.com](http://kidsdentalspecialists.com) and drop off your electronic resume to Dr. Tran at [drlindatran@kidsdentalspecialists.com](mailto:drlindatran@kidsdentalspecialists.com). We look forward to meeting you!

**DENTAL ASSISTANT —** We are looking to bring on an Ortho Assistant for our new ortho program. This is a great opportunity to work with a renowned Orthodontist. Please email your resume to [bayareadentist2009@yahoo.com](mailto:bayareadentist2009@yahoo.com) for immediate consideration.

**DENTAL HYGIENIST —** We are a relatively new office that is trying to expand its operations. We have an opportunity to accommodate a relatively novice hygienist who is looking to get some hours and experience under his/her belt. The office is open late evenings and weekends and we expect all our team members to be inline with our philosophy of what it takes to build a practice. We are looking for mostly

CONTINUES ON 778

## When Looking to Invest in Professional Dental Space Dental Professionals Choose



## Linda Brown

30 Years of Experience  
Serving the Dental Community  
Proven Record of Performance

- Dental Office Leasing and Sales
- Investment Properties
- Owner/User Properties
- Locations Throughout Southern California

For your next move,

Contact Linda Brown:

Direct Line: (818) 466-0221

Fax: (818) 593-3850

E-mail: [LindaB@TOLD.com](mailto:LindaB@TOLD.com)

website: [www.TOLD.com](http://www.TOLD.com)

CA DRE #: 01465757

**TOLD**  
partners INC.  
INDUSTRIAL/COMMERCIAL REAL ESTATE  
CA DRE #: 01132455





# WESTERN PRACTICE

## 800.641.4179

WPS@SUCCEED.NET

WESTERNPRACTICESALES.COM

### BAY AREA

**BC-162 PLEASANT HILL Facility:** Updated office, large windows & views of the outdoors. Open floor plan. 1,852 sf w/6 ops **Reduced! \$150k**

**BC-175 EAST CONTRA COSTA:** Vast employment, shopping & activities! 1,995 sf w/5ops **\$300k**

**BN-183 HAYWARD:** *Kick it up a notch by increasing the current very relaxed work schedule!* 1,300 sf w/ 3 ops **\$150k**

**CC-077 BENICIA:** Highly visible. Within walking distance of downtown. 820 sf w/2 ops **\$100k**

**CC-151 SANTA ROSA:** Stable patient base, well-respected, close to Memorial Hospital. 2,262 sf w/ 6 ops **\$875k Real Estate avail.**

**CC-170 SOLANO COUNTY:** Minutes from nearby wine country! 950 sf w/3 ops **\$225k**

**CN-158 PETALUMA:** Predominantly Capitation practice. 1,000 sf w/ 4 ops **Reduced! \$395k**

**CN-184 SOLANO COUNTY:** Well established, premier practice. 2,180 sf w/ 5 ops. State of the art equipment **\$775k**

**CN-189 ANTIOCH VICINITY:** In the heart of the beautiful California Delta! 3 ops **\$275k**

**D-9091 ATHONTON:** Turnkey operation 969 sf & 3 ops **Call for Details!**

**DC-113 MILPITAS:** Seller retiring! Great location 1,009 sf w/ 3 ops. Plumbed for 1 add'l **\$110k**

**DC-164 WATSONVILLE:** Shopping complex/main thoroughfare. Modern & Attractive. 2,365 sf w/ 6 ops **\$395k**

**DG-116 SALINAS AREA:** Large, loyal & stable. Popular Retail Center. 1,400 sf w/5 ops. State-of-the-art Equipment **Reduced! \$205k**

**DG-124 MILPITAS:** Highly visible. Desirable area. 960 sf w/ 2 ops + 1 add'l **\$130k**

**DG-156 SAN JOSE:** Hardwood Floors & plenty of windows! 1,160 sf w/ 3 ops (+2 add'l) **\$145k**

**DG-161 FREMONT:** Beautiful office generating 40+ new pts/mo. 1,440 sf w/ 4 ops **\$215k**

**DN-204 SAN JOSE Facility:** Located in a popular Dental Professional building! ~1,635 sf w/ 3 ops (+2 add'l) **\$95k**

**DG-202 SARATOGA Facility:** Attractive, well-maintained, 2-story Medical/Dental/Professional building. Desirable upscale, affluent area. 1,568 sf w/ 4 ops **\$185k**

### BAY AREA CONTINUED

**DC-191 MOUNTAIN VIEW:** Rare opportunity! High quality, potentially large-scale practice. Heart of Silicon Valley. 2,000 sf w/7 ops (+1) **\$950k**

**DG-207 SUNNYVALE Facility:** Location, location, location! Reasonable rent, low overhead, easy accessibility. 650 sf w/ 2 ops **\$78k**

### NORTHERN CALIFORNIA

**EG-198 SACRAMENTO:** Tucked in well established "Pocket Area" in highly desirable corridor. 1,112 sf w/3 ops **\$155k**

**EN-145 ROCKLIN Facility:** Very desirable community! 1,400 sf w/3 ops +1 add'l **\$150k**

**EN-167 SACRAMENTO:** One of the most desirable, affluent areas. 1,849 sf w/5 ops. **\$450k**

**EN-208 SACRAMENTO:** Family-oriented FFS restorative practice! Office ~ 1,287 sf w/4 ops. **\$225k**

**FN-181 NORTH COAST:** Well respected FFS GP. Stable patient base. 1,000 sf w/3 ops **SELLER MOTIVATED! \$150k (25% int. in bldg. avail.)**

**FN-087 LAKE COUNTY:** Quality practice, friendly staff & Cerec 2,400 sf w/3+ ops **\$699k**

**FN-148 MENDOCINO CO:** "Gateway to the Redwoods!" Quality care in 4 ops **\$325k**

**FN-185 UKIAH:** Street-level office. 900 sf w/ 3 ops **\$275k**

**GG-140 CHICO VICINITY:** Selling for less than 50% of gross! 1,200 sf w/4ops. **Reduced! \$195k**

**GN-134 REDDING:** Stellar reputation, quality care and location! 2,264 sf w/4 ops. **\$500k**

**GN-149 YREKA:** Quality FFS, Warm & Caring. 900 sf w/ 3 ops. Now Only: **\$180k/Real Estate \$110k**

**GN-166 CHICO:** Well Respected w/loyal patient base. 1,800 sf w/4 ops. **\$395k (or \$450k w/Cerec)**

**GN-177 CHICO/ROVILLE:** Spacious! Spectacular! 2,500 sf w/6 ops **\$399k**

**GN-201 CHICO:** Don't Miss This Opportunity! Beautiful practice located on major thoroughfare with stellar reputation! 1,400 sf w/ 4 ops & room for another **\$425k**

**GN-196 CHICO:** Appealing location! Office ~2,510 sf w/4 ops **\$150k**

### What separates us from other brokerage firms?

As dentists and business professionals, we understand the unique aspects of dental practice sales and offer more practical knowledge than any other brokerage firm. We bring a critical inside perspective to the table when dealing with buyers and sellers by understanding the different complexities, personalities, strengths and weaknesses of one practice over another.

Our extensive buyer database and unsurpassed exposure allows us to offer you...

A Better Candidate

A Better Fit

and A Better Price!

# SALES

## CENTRAL VALLEY

**HN-059 LASSEN CO:** Quality, well-established, family-oriented. 1,600 sf w/3 ops **\$120k**

**I-9721 STOCKTON:** Prof. complex. 1,450 sf w/ 3 ops & plumbed for 1 add'l **\$75k**

**IG-067 STOCKTON:** Fully computerized, paperless, digitalized. 5,000 sf w/10 ops **Now \$425k**

**IG-165 TURLOCK:** Well established Shared/Solo Group Practice. 10 ops (shared) **\$428k**

**IN-176 TURLOCK:** Mother Lode, SF Bay & Sierras nearby! 2,500 sf w/3 ops **\$120k**

**IN-193 Modesto Facility:** Recently remodeled! High foot traffic! Can be purchased with or without new equipment. 2,300 sf w/6 ops **Listed at only \$299k**

**IN-205 STOCKTON Facility:** Get ready to practice your best dentistry here! One of the most desirable professional corridors. Newly remodeled. 1,565 sf w/ 4 ops **\$169k**

**JG-137 FRESNO:** Own the Building too! 3,500 sf w/ 5 ops **Now Only \$395k/ Real Estate \$350k**

**JG-188 FRESNO:** Loved, respected, Established! Net Profit over \$350k! 1,452 sf w/4 ops **\$390k**

**JC-178 SAN JOAQUIN VALLEY:** Historical Building in thriving area! 2,206 sf w/6 ops **\$495k**

## SPECIALTY PRACTICES

**AC-119 MILL VALLEY Prosthodontics:** State-of-the-art equipment including: digital charting and x-ray. 1,100 sf w/ 3 ops. Plumbed for 4<sup>th</sup> **\$450k**

**EG-131 ROSEVILLE/AUBURN Orthodontics:** 2 practices within ½ hour of each other! **\$175k**

**I-7861 CENTRAL VALLEY Orthodontics:** 2,000 sf, open bay w/ 8 chairs. Fee-for-Service. **\$370k**

**I-9461 CENTRAL VALLEY Orthodontics:** 1,650 sf w/5 chairs/bays & plumbed for 2 add'l **\$180k**

**IC-163 CENTRAL VALLEY Periodontics:** Well-respected FFS. 2,300 sf w/5 ops **\$175k (Bldg: \$250k)**

**EN-203 SACRAMENTO Oral Surgery:** This highly efficient office occupies ~ 3,000 sf w/ 4 fully equipped ops **\$325k**

We are a proud member of:



## ASK THE BROKER

### Valuable Advice for Doctors as the Year Comes to an End

As the fourth quarter approaches, we'd like to offer this valuable advice.

Many doctors take some time off during the holidays which results in the office being closed at year-end, possibly leaving some undeposited collections for several weeks until the new year. Other doctors prepay bills and may hold back several weeks' worth of revenue at their accountant's suggestion to facilitate in their yearly tax planning. If you are trying to sell your practice currently or are thinking of selling in the next year, I strongly suggest that you finish off the year strong and make **ALL of your deposits** so that they are posted by your bank in **this** calendar year.

The sales price of any practice is essentially determined from the previous year's tax return or Profit & Loss Statement. In the past, averages of a year or two may have been used to determine value, but in this declining economy, it's all about "what have you done for me lately"!!! Banks and buyers are only interested in what is happening ***right now***. Even if you missed work due to illness, surgery or an accident, this economy has banks and buyers very wary of any practice with ***declining revenues***, no matter what the reason.

"It's the economy" is the last excuse the bank wants to hear as the reason to why your practice revenues are declining. Not only will the bank decrease the amount of funds they are willing to loan, they will either require a ***seller carry-back*** or may not even agree to loan money unless the revenues have stabilized or start to increase again. Essentially, if the average practice multiple in your region is selling at 68% of gross receipts, the national average at this time, your practice will still sell at 68% of your current revenues. If your practice shows a decline of more than 15-20% of the usual revenues, the bank may have problems with normal financing. (NOTE: Practices in Cupertino, CA and Orange County, CA sell upwards of 100% but the issue applies in these areas as well)

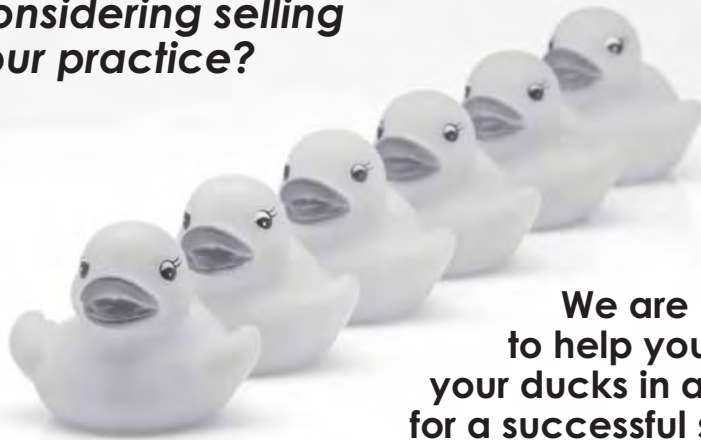***Do not confuse this information and assume  
it is a bad time to sell your practice.***

The good news is: if you make your deposits this year and your practice has not declined more than 15-20%, it is actually a "seller's" market currently and 100% financing is the norm. The loan rates are at historic lows in the 5-6% range. If you have finally decided it is time to sell and transition into the next exciting phase of your life, finish strong and make the gross receipts on your last tax return look their best!!!

***Your timing could not be better!  
Just let the numbers do the talking for you!***

Timothy G. Giroux, DDS is currently the Owner & Broker at **Western Practice Sales** and a member of the nationally recognized dental organization, ADS Transitions. You may contact **Dr Giroux at: wps@succeed.net or 800.641.4179**

## Considering selling your practice?



**We are here  
to help you get  
your ducks in a row  
for a successful sale!**

We have been handling dentist's  
practices **with care** since 1997.

It's not how many we do.  
**It's how we do it!**

**Dental Practice: Sales - Acquisitions - Mergers - Valuations**

### FEATURED LISTINGS

**MISSION VALLEY, CA** Seven op prosthodontic practice, great location!

**MISSION VALLEY EAST AREA, CA** Three op GP, high traffic area.

**RENO, NV** Growing 4 op (3 equipped) GP. Strong net income.

**New! CENTRAL IDAHO** Spacious & efficient, 3 op GP. Exceptional opportunity.

**PRACTICE  
TRANSITION  
PARTNERS**  
*realizing the possibilities*



Russell Okiyara, D.M.D.  
CA Representative



Robert Stanbery  
Owner

*Give us a try and  
experience the difference!*

**888.789.1085**

**www.practicetransitions.com**

CLASSIFIEDS, CONTINUED FROM 775

Fridays and maybe some Mondays for now. The doctor is very particular about his high expectations as to how treatment is delivered to our patients. He may require a one-on-one, hands-on prophylaxis or scaling technique demonstration on a typodont etc., what your philosophies are on the periodontal treatment options, etc. On the flip side we are a new office and don't really have a must-have requirement for a hygienist — as a result compensation will be adjusted accordingly. Send email to [folsomfamilydental@gmail.com](mailto:folsomfamilydental@gmail.com) for more information.

**DENTAL HYGIENIST** — The California Department of Corrections is currently seeking Dentists and Dental Hygienists in Northern, Central and Southern California prisons for hire as soon as possible. Please call Debbie Villa at 951.683.3753 or send email to [dvilla@ttstaffing.com](mailto:dvilla@ttstaffing.com).

**DENTIST** — State-of-the-art Palo Alto general practice seeks full-time Associate with a minimum of three years of experience, who is self driven, dedicated to technical excellence and pursuing continuing education. Must be open to mentoring, working collaboratively with staff, other dentists and with the patients. Patient culture is educated, refined and family oriented. The bar is high. We love what we do and have fun while providing top-notch care. Candidate is expected to put down roots, get involved in the community and enhance practice management and growth. Bay Area Certified Green Business. Email resume to [Connie@MulcahyFamilyDentistry.com](mailto:Connie@MulcahyFamilyDentistry.com).

### **PERIODONTISTS AND ORAL**

**SURGEONS** — We are looking to collaborate with Periodontists and Oral Surgeons for our Mobile Surgical Services in both Northern and Southern California. We are the first comprehensive mobile surgical service in the United States providing implant surgeries, periodontal surgeries and surgical extractions for dental offices. If you would like to fill your schedule with

additional surgical procedures, we are the right tool for you. Please send your resume to [jobs@implantoutreach.com](mailto:jobs@implantoutreach.com).

**ENDODONTIST** — Dear Endodontist: Our endo program is growing and we are adding more days, prompting us to add another Endodontist to our team. We will need at least one day per week commitment. Good opportunity to add more days should you prefer. Please email your resume to [bayareadentist2009@gmail.com](mailto:bayareadentist2009@gmail.com) or simply send an email or call 408.656.4567 to discuss this opportunity.

**ENDODONTIST** — Seeking a board-eligible Endodontist with 2-3 years of experience for one day a month at a private fee-for-service/PPO practice in Marina del Rey, Calif. Dentrrix, Dexis digital X-ray and Zeiss microscope. Our practice offers a very friendly and professional environment. Please contact Dr. Rayet at the office at 310.823.2343 or on her cell at 310.699.4042. You can also email your resume to [azitarayet@gmail.com](mailto:azitarayet@gmail.com).

**ORAL SURGEON** — Sacramento Oral Surgery has been providing quality oral surgery care to patients throughout the Sacramento area for more than 30 years. Founded in 1972, Sacramento Oral Surgery has five practices located in the greater Sacramento area. We are currently looking to add a full-time Oral Surgeon to join our growing team! Our doctors enjoy a professional practice experience and comprehensive compensation and benefit package that includes medical, professional liability, disability and life insurances, flexible spending account and a 401k program with employer matching contribution. Ownership potential, too! Go to [amdpi.com/Careers/Specialists.aspx](http://amdpi.com/Careers/Specialists.aspx) to apply.

**DENTIST** — Western Dental Services Inc. is hiring Dentists for offices in Concord, Manteca and throughout California. Must have DDS and valid California dental license. Send resumes to [recruiting@westerndental.com](mailto:recruiting@westerndental.com).

**DENTIST** — The California Department of Corrections is currently seeking Dentists and Dental Hygienists in Northern, Central and Southern California prisons for hire as soon as possible. Call Debbie Villa at 951.683.3753 or send email to [dvilla@ttstaffing.com](mailto:dvilla@ttstaffing.com).

**OFFICE MANAGER** — Pediatric Dental Manager position available. Are you looking to join a stable company that is experiencing a tremendous amount of growth, values your contribution and provides you with a career rather than just a job? What you'll do: Identify staff and develop talent. Create an environment that promotes pediatric dental culture and values daily. Work with IT vendors and Dentrrix software company on all technical issues and updates and much, much more. Because of the vital nature of this role, we seek candidates with five-plus years of related work experience; working

knowledge of Dentrrix; operational management knowledge of dental offices; equivalent to high school diploma or general education degree (GED). Please do not contact the office. Only contact Tyna Whipple at [tyna@vzconsultinginc.com](mailto:tyna@vzconsultinginc.com) or at 408.655.2558 for an interview or more details regarding the job.

**TREATMENT COORDINATOR** — Dear Candidate: We are a general and multispecialty office that is looking to hire a top-notch Treatment Coordinator. Come join our friendly staff and continue to grow with us as we have done over the years. If you are a confident, friendly person who has a great track record of closing small and large treatment cases with high treatment acceptance rates, we would love to hear from you. This is a great

CONTINUES ON 780

## Why a Career at Willamette Dental Group?

“The best feeling in the world is not worrying about work when you leave the office. I'm making more, working less, getting crazy good benefits, and love my job!”



Dr. Armstrong, DDS  
General Dentist | Boise, ID

### Practice proactive dentistry.

Learn more about our practice opportunities at  
[www.WillametteDental.com/careers](http://www.WillametteDental.com/careers)

Tiffany Brown  
[tbrown@willamettedental.com](mailto:tbrown@willamettedental.com)  
or Direct: 503-952-2171

  
**Willamette**  
Dental Group



## CLASSIFIEDS, CONTINUED FROM 779

full-time opportunity. Dentrix knowledge required. At least five years experience in dental offices required with at least three years doing treatment planning and presentation. Competitive compensation for the right candidate. Please email your resume to bayareadentist2009@gmail.com or call us at 408.656.4567 to discuss.

**FRONT OFFICE DENTAL SUPERVISOR**

— Children's Dental Center is a growing specialty practice that focuses on providing quality pediatric dental care. Our mission, since opening our first practice in 1980, has always been making patient care our No. 1 priority! Our Front Office Dental Supervisor provides leadership, training and direction to the front office staff including the treatment coordinators and receptionists. Must be able to work in a

fast-paced, high-volume practice while providing high-quality patient care. Depending on your experience, we offer a competitive compensation program and benefits including medical/dental/vision/life and supplemental coverage, vacation and a 401k plan. Must have high school diploma or general education degree (GED); two years' experience in dental practice at supervisory or lead role; dental background required; bilingual in Spanish/English a big plus. Please submit your resume in Word or PDF format to hrnoral@cdgdental.com.

**FRONT/BACK OFFICE** — Seeking front/back office. Has to be proficient in reception, insurance billing and assisting dentist when called upon. At least two years experience working at a dental

office. Please email resume to dentalstaff2013@gmail.com.

**ENDODONTIST** — Newer office needs an Endodontist (new grads OK) after hours and/or some Saturdays. Local to Folsom preferred. We are a relatively new dental office so ideally only need someone either after or before his/her other office hours. As usual, we face resistance with trying to refer patients to outside providers and are trying to make an in-house option available to patients. The ideal candidate would be open to coming in even for one to two cases and being reimbursed on a percentage basis pending if they completely bring 100 percent of all instruments (preferred) or use ours. Please email folsomfamilydental@gmail.com for more information.

CONTINUES ON 782

Dental Hygienists

Dental Assistants

Dentists

Front Office

# DentalPost

Your mobile & online dental industry job board

## POST SEARCH



## HIRE



Download the advantage today!

## Find your next employee!

- Post job openings, search resumes, or both
- Postings syndicated to Twitter, Facebook, Indeed.com, & more
- Dental professionals apply online or using our Mobile App
- Resumé database with pictures, personality test, & skills

Register your dental practice  
or yourself today

**www.DentalPost.net**

Questions? Email us at [contactus@dentalpost.net](mailto:contactus@dentalpost.net)

Tonya Lanthier, RDH/ Founder





**Dr. Lee Maddox**  
License #01801165  
25 Years in Business



**Dr. Dennis Hoover**  
License # 0123804  
36 Years in Business



**Dr. Thomas Wagner**  
License #01418359  
40 Years in Business



**Jim Engel**  
License #01898522  
42 Years in Business



**Kerri McCullough**  
License #01382259  
35 Years in Business



**Thinh Tran**  
License #01863784  
11 Years in Business



**Mario Molina**  
License #01423762  
35 Years in Business



**Jaci Hardison**  
License #01927713  
26 Years in Business

PRACTICE SALES • PARTNERSHIPS • MERGERS • VALUATIONS/APPRISALS • ASSOCIATESHIPS • CONTINUING EDUCATION

**BAKERSFIELD:** General Dentistry Practice. 3,650 sq. ft. suite with 8 Ops., 7 equipped. Digital x-rays and intra-oral camera. \$1.2MM in collections. \$453K Adj. Net Inc. in growing area. #CAM554

**BAKERSFIELD and SMALL FARM COMMUNITY:** Two Practices 30 min. apart. Strong patient bases. Staff and doctor work both practices. Underserved communities with room for growth. \$588K gross. \$278K adj. net. #CAM557

**BISHOP:** General Dentistry Practice & Building. 1,800 sq. ft. 5 Ops. 2011 collections of \$1MM. \$387K Adj. Net Inc. #14390

**CENTRAL COAST:** Pedodontic practice with 4 Ops. Gross over \$775K on 4-day wk. Great location. Over 800 new patients last year. #CAM546

**CENTRAL COAST:** Prosthodontic practice with 4 Ops, full in-house lab. Over \$1.1MM in gross receipts in '12. Beautiful area near shopping. #CAM535

**CHICO:** General Dentistry Practice. 2012 collections almost \$1.4MM. 2,400 sq. ft. free-standing building. Option to purchase or lease. #14392 - **In Escrow**

**COASTAL ORANGE COUNTY:** General Dentistry/Implant practice. 1,800 sq. ft., 4 Ops. Implant system in all Ops. Gross receipts \$1.2MM in '11. #CA520 **In Escrow**

**COASTAL ORANGE COUNTY:** Periodontal practice. 5 Ops. Retiring doctor. 3 days with 4 days of hygiene. 2011 gross receipts \$400K. #CAM533

**COASTAL ORANGE COUNTY:** General Dentistry Practice with modern, new equipment and high-end finishes. 2012 gross receipts of \$690K. #CA529

**DANVILLE:** FACILITY ONLY. 5 fully equipped & furnished Ops. Digital X-ray, Digital Panoramic X-ray, and central Nitrous Oxide/ Oxygen. Seller relocating after 27 years. #CA548 - **In Escrow**

**FREMONT:** 3,000+ sq. ft. suite. 10 Ops. Digital x-rays and Pan. 4,000 active patients. PPO/HMO with '12 gross receipts of \$1.2MM with Adj. Net Inc. of \$300K. #CA553

**GRASS VALLEY:** General Dentistry Practice. 1,500+ sq. ft. office. 5 Ops, 4 equipped. Collections of \$491K with Adj. Net Inc. of \$130K. #14379 - **In Escrow**

**GRASS VALLEY:** General Dentistry Practice. Almost 2,000 sq. ft. condominium for sale with 6 Ops. 2012 gross receipts \$442K. #14372

**GREATER SACRAMENTO:** General Dentistry Practice. 1,400 sq. ft. office with 5 Ops. 2012 gross receipts over \$879K. Adj. Net Inc. of \$446K. #CA525 **In Escrow**

**GREATER SACRAMENTO:** General Dentistry Practice & Building. 2,300 sq. ft. office with 6 Ops. EZ Dental Software, Pan, 8 days hygiene per week. \$900K average production last 3 years. Great location. #CA560

**GREATER SACRAMENTO:** Orthodontic Practice. Like-new 2,300 sq. ft. office with extensive leasehold improvements and 6 chairs. 220 active patients in phase 1. #CA551

**HAWAII (MAUI):** General Dentistry Practice. Approx. 1,200 sq. ft. with 4 equipped Ops. Gross receipts of \$636K. #20101

**INDIAN WELLS:** General Dentistry/TMJ Practice. 4,000 sq. ft. suite, 6 Ops. 2011 Gross Receipts over \$350K on just 1 doctor day/week. #CAM530

**LANCASTER:** General Dentistry. 2,300+ sq. ft., 4 Op office. Gross receipts of \$676K with \$174K Adj. Net income. #14376

**MERCED:** General Dentistry. 1,550 sq. ft. office with 4 Ops. 2011 gross of \$878K with Adj. Net Inc. of \$294K. #CA512

**MILPITAS:** General Dentistry. 1,440 sq. ft., professionally designed office located on major business district thoroughfare. 4 Ops with Intra-oral cameras and computers in each Op., plus a Pano X-ray. Owner is retiring after 46 years, 34 years at this location. #CA562

**MURRIETA:** General Dentistry. 4 Ops in 1,300 sq. ft. office. 2012 gross receipts were over \$530K with \$213K Adj. Net Inc. #CAM544

**LINCOLN-ROSEVILLE:** General Dentistry. 1,200+ sq. ft. office with 4 Ops. 2012 gross receipts of \$787K with Adj. Net Inc. of \$358K. #CA545

**NEWPORT BEACH:** General Dentistry with 3 Ops, newer, high-end equipment. 2012 gross receipts of \$350K on 3 1/2 days per week. #CAM534 - **In Escrow**

**NEWPORT BEACH:** General Dentistry with 4 Ops near Newport Center/Fashion Island. Gross collections of \$265K with \$58K Adj. Net. Seller refers out most specialty work, room to grow. #CAM559

**NORTH OF SACRAMENTO:** General Dentistry. Newly remodeled office with 4 equipped Ops, 5 available. Approx. 1,500 active patients. 2012 gross receipts of \$515K on 32hr/week, working about 37 wks/yr. EZ Dental, Pan., Fiber Optics. 20 hours hyg. per week. Owner retiring. Bldg. available for purchase. #CA558

**NORTH OF SACRAMENTO:** General Dentistry. 1,650 sq. ft. with 4 Ops. 2012 gross receipt of \$521K. Low overhead of 52%. #CA528

**NORTH ORANGE COUNTY:** Endodontic Practice with 5 Ops, fully equipped and 3 Zeiss wall-mounted microscopes. Practice has been established for 30 years. Gross receipts of \$370K and Adj. Net Inc. of \$172K on 3 day wk. #CAM561

**NORTH SAN DIEGO COUNTY:** Large legacy practice. 12 equipped Ops, HMO practice with large CAP check in a desirable area in North County. #CAM555

**ORANGE:** General Dentistry. 5 Ops. 2012 gross receipts of over \$830K. #CAM543

**ORANGE COUNTY:** Periodontal Practice. 6 Ops available, 5 fully equipped. 2012 gross receipts of \$450K on 4 day wk. #CAM536

**PALM SPRINGS:** General Dentistry. 4 Ops. PPO/Fee For Service, no HMO with 2012 gross receipts of \$348K. #CAM538

**RIDGECREST:** General Dentistry Practice and Dental Building. 1,500+ sq. ft. office building with 4 Ops. This small practice grossed about \$175K in 2012. #CA523

**SACRAMENTO:** General Dentistry. Owner retiring. 2,400 sq. ft. office/ building with low (54%) overhead. 8 Ops, 7 are equipped. 2012 Gross Receipts of \$642K. #CA549 - **In Escrow**

**SALINAS:** Well-established General Dentistry practice offers 4 Ops in 1,275 sq. ft. office. 2012 gross receipts of \$226K on reduced schedule. Refers out all specialty work. Great upside potential. Owner retiring after 34 years. #CA552

**SAN GABRIEL VALLEY:** General Dentistry. 4 Ops. 2011 gross receipts of \$590K on 3 1/2 day wk. #CAM541

**SAN JUAN CAPISTRANO:** General Dentistry. 4 fully-equipped Ops. Gross receipts of \$650K in '12. #CAM539 - **In Escrow**

**SAN RAMON: FACILITY ONLY.** Great location, equipment, leaseholds & furnishings only. 1,400 sq. ft. with 4 equipped Ops (2 more plumbed) #CA511

**SAN RAMON:** General Dentistry. 2012 gross receipts of \$736K with Adj. Net Inc. of \$344K. 6th plumbed in approx. 2010 sq. ft. office. #CA547

**SOUTH ORANGE COUNTY:** General Dentistry Practice with 5 Ops available, 4 fully equipped. Most specialty work referred out. 2012 Adj. net of \$324K on \$793K Collections. #CAM556 - **In Escrow**

**SOQUEL:** General Dentistry Practice in 1,100 sq. ft. office. 3 Ops. in prof. bldg. near Hwy. 1. Gross receipts of \$338K on 2 days/wk. 1,100 active patients. 10 new patients/mo. Schick Digital X-ray and Dentrix Software. Average age of equip. is 5 yrs. old. Seller moving. #CA550

**TURLOCK:** General Dentistry. Gross receipts in '12 of over \$950K with \$443K Adj. Net Inc. #CA506

**WALNUT CREEK:** Prosthodontic Practice with 3 fully-equipped Ops and full lab. 2012 gross receipts of \$530K. #CAM540

**WESTWOOD:** Amalgam-free General Dentistry Practice. 5 Ops, near UCLA. \$672K in Gross Receipts in 2012. #CAM542 **In Escrow**

**YORBA LINDA:** General Dentistry Practice with 5 well-appointed Ops in great location. Laser, Intra oral camera, and digital x-rays. 28 years in family community. 3 days hygiene and 3 doctor days per week. #CAM531

## CLASSIFIEDS, CONTINUED FROM 780

**BACK OFFICE SUPERVISOR** — Children's Dental Center in San Jose is a growing specialty practice that focuses on providing quality pediatric dental care. Our mission, since opening our first practice in 1980, has always been making patient care our No. 1 priority! The Back Office Supervisor is responsible for providing leadership and direction to the clinical staff, maintaining the high level of quality care and improving department operations productivity and efficiencies. Must be able to work in a fast-paced, high-volume practice while providing high-quality patient care. Depending on your experience, we offer a competitive compensation program and benefits including medical/dental/vision/life and supplemental coverage, vacation and a 401k plan. Must have two-plus years of dental office supervisory experience; high school diploma or general education degree

(GED) required, X-ray certificate and current CPR certification. Bilingual preferred. Must be able to effectively communicate, both written and verbal, with employees, doctors, management and others. Good analytical skills. Ability to deal with problems involving several variables. Please submit your resume in Word or PDF format to hrnorcal@cdgdental.com.

## OPPORTUNITIES WANTED

**DENTIST** — Dentist with 15 years of experience looking for Friday and Saturday position. I can perform a wide array of procedures from wisdom teeth fully impacted, molar endo, laser dentistry, CAD-CAM, children to implant restoration and much more. If interested please call 530.640.2324. Thank you, Dr. J.

**IN-HOUSE PERIODONTIST/IMPLANT SURGEON FOR YOUR OFFICE** — In-house Periodontist/Implant Surgery/Oral Surgery available for your office in the Greater San Francisco Bay Area. Implant surgery/bone grafting/perio surgery/third molar extractions/surgical extractions. Send email to bayareaperio@gmail.com or call 617.869.1442.

## EQUIPMENT FOR SALE

**EQUIPMENT FOR SALE** — Pro Form Vacuum 2, about four years old with partial boxes of laminates for bleach trays, retainers, night guards and mouth guards. All for \$100. Contact office manager, Ranielle at drmla@comcast.net.

**EQUIPMENT FOR SALE** — Complete Astra Tech Implant surgery kit fully equipped to place implants right away. Also included is a brand new set of osteotomes. This implant surgery kit has only been used four times and is very well cared for and stored. The condition is almost "new." Includes 1 contra angle handpiece WI-75E/KM W&H 20:1 — reference #22903; 1 Implant unit with cable, foot control, metal stand — reference #24412; Disposable irrigation set and tubes — reference #22176 and #22177; 1 complete surgical drill bit set — reference #24264; 1 Surgical cassette tray to hold drill bit set — reference #24980; 1 Radiographic implant guide; 1 Surgical instrument kit — reference #24980; 1 Complete torque wrench kit — reference #24110; 1 Restorative tray to hold torque wrench kit — reference #22495v; 2 fixtures/implants; 1 complete set of osteotomes + mallet and cassette (brand new). Photos available upon request. Send email to mydentist@gmail.com.

**EQUIPMENT FOR SALE** — KaVo dental chair w/light and assistant chair. Grey leather, about 10 years old. Works great but does make a noise on reclining.

# PARAGON

## DENTAL PRACTICE TRANSITIONS

### THE PARAGON DIFFERENCE

After handling thousands of transactions over the past two decades, PARAGON consultants know that no two clients and no two transactions are the same.

A practice transition is a very personal event that requires very special attention. Nothing is taken for granted. We customize every single transaction to satisfy the needs and goals of our clients. We handle each transaction as if we are the client. This is just one of the many reasons why PARAGON is so unique.

Judge for yourself! Call us for a complimentary consultation. No obligation...just a very worthwhile education!

Sign up for our free newsletter at [paragon.us.com](http://paragon.us.com)



Your local PARAGON practice transition consultant is Trish Farrell  
Contact her at 866-898-1867 or [info@paragon.us.com](mailto:info@paragon.us.com)

CONTINUES ON 784





# CARROLL & COMPANY

**"MATCHING THE RIGHT DENTIST  
TO THE RIGHT PRACTICE"**

Complete Evaluation of Dental Practices & All Aspects of Buying and Selling Transactions



*Serving you: Mike Carroll &  
Pamela Carroll-Gardiner*

## **4009 WOODLAND GP**

Woodland GP and building available w/4 fully-equipped ops in approx. 1,500 sq. ft. office in gorgeous garden setting. Well est. prevention oriented family practice w/ seasoned & loyal staff. 2012 GR \$232K+ w/just 3 doctor days. Only those interested in both the building and practice need respond. Practice asking price \$138K, building asking price \$315K.

## **4004 LOS GATOS GP**

Seller retiring from a high quality cosmetic general practice in upscale neighborhood w/well-educated and loyal patient base & long term dedicated staff. Currently working equivalent of 2+ doctor-days with hygienist working 3 days per week. Seeks to transition practice to an experienced buyer with a passion for dentistry. Modern 1,200 sq. ft. office w/4 fully-equipped ops., digital x-ray & 7 fully networked computers running Dentrix. 5 year avg. GR \$408K. 2013 GR on target for \$360K.

## **3092 SF FACILITY**

1,600 sq. ft. street-level dental facility in Marina/Cow Hollow neighborhood across from Presidio with excellent visibility and signage for foot traffic plus easy diagonal parking in front of building. Move in ready with 4 ops., 2 labs, kitchenette, reception and 2 desk areas plus 2 pvt. offices, 2 bathrooms, 1/2 basement & backyard with deck.

## **3096 NORTH BAY PERIO**

Step into quality practice with established referral base. 2,200 sq. ft. office w/6 fully-equipped ops. Modern facility kept updated with recently purchased chairs, lights, Pano & lasers. Seller will grant a fair market lease and would consider selling the office space. 5 year avg. GR \$1.2M+

## **3099 LOS GATOS GP**

Well-est. general, restorative & cosmetic practice available in very desirable neighborhood. Gorgeous 1,530 sq. ft. office in single story dental complex w/4 ops. Asking \$580K.

## **3098 SALINAS GP**

Well-known GP specializing in restorative dentistry retiring from 28 year practice located in highly visible downtown office. 4 fully-equipped ops., Panorex, digital x-ray & recent equipment upgrades. 2 year avg. GR \$331K+ w/approx. 152 doctor days/yr. Asking \$210K.

## **3095 SAN CARLOS**

Seller well-known for quality patient care retiring from established practice with loyal patient base, in highly desirable neighborhood. Asking \$515K.

## **3085 MODESTO GP**

State-of-the-art practice in approx. 2,800 sq. ft. facility w/7 fully-equipped ops. This practice is for an established dentist or 2 dentists w/experience & who will appreciate a high quality practice. Asking \$745K.

## **4002 SANTA CRUZ AREA GP & BLDG**

Well-est. practice in modern 1,250 sq. ft. office w/4 ops. 5 year avg. GR \$630K+ w/ just 4 doctor days. Selling building & practice together. Practice asking price \$430K, building to be determined.

## **4001 NORTHERN SONOMA COUNTY GP**

Approx. 1,059 sq. ft. facility w/3 fully-equipped ops and dedicated parking in downtown area. Practice & building for sale. Great opportunity. Practice Asking \$311K, building to be determined.

## **3094 NORTH BAY PERIO**

North Bay Perio now available. Seller retiring from well-est. practice with seasoned staff and active referral base. 1,300 sq. ft. very nice office with 4 fully-equipped operatories. 2012 GR \$450K+ with just 3 1/2 doctor days and 5 days of hygiene per week. Great upside potential since owner does few implants. Asking \$271K.



### **Contact Us:**

Carroll & Company  
2055 Woodside Road, Ste 160  
Redwood City, CA 94061

### **Phone:**

650.403.1010

### **Email:**

dental@carrollandco.info

### **Website:**

www.carrollandco.info

CA DRE #00777682



## CLASSIFIEDS, CONTINUED FROM 782

Assistant chair has a crack on the back but is fully functional. Available for pick up or local delivery for \$100. Can ship by freight but you pay shipping. Email to sonomafamilydentist@yahoo.com is the best way to contact me. Chairs are available now.

## OFFICES FOR RENT/LEASE

**OFFICE FOR RENT/LEASE** — Beautiful modern dental office for sublease in Brentwood, Calif., for two or more days per week. Preferably an Endodontist or Orthodontist. Office has two equipped operatories. All modern, new equipment. Send email to jasdeep\_grewal@yahoo.com for more information.

**OFFICE FOR RENT/LEASE** — Specialty office in Bakersfield, Calif., for rent/lease. Established dental office. Four plumbed operatories. Newly remodeled. Quiet room. 1,000 sq. feet. Tremendous amount of under serviced young families in the area. Perfect for pediatric dentist, endodontist or oral surgeon. \$1,250 a month. Please call 661-871-0780.

**OFFICE FOR RENT/LEASE** — Great opportunity in Irvine, Calif., to sublease two operatories in our five-operator office. The office suite is in a three-story medical building. The operatories are plumbed and ready for you to add your chairs and X-ray units. There is plenty of room for your supplies and a large front desk area with room for your computer

and office supplies. Great for someone looking to cut overhead. Email us at russellcannondds@earthlink.net. Check out our office on our website at drrussellcannon.com or call at 949.552.7874 and ask for Debi Cannon.

**OFFICE FOR RENT/LEASE** — Beautiful lakefront dental practice in South Lake Tahoe. Must-see, gorgeous 800 sq. ft. dental practice. Custom building situated on the lake. All four operatories' sliders open directly to lake, private office, fireplace. Interested parties please contact 775.783.9898 or email stolldds@aol.com for further details.

**OFFICE FOR RENT/LEASE** — Placerville, Calif., dental office for lease. Lease a highly successful dental office with prime location across from hospital. Office is 1,676 sq. ft. and has five operatories. Freestanding building has raised-floor access. Call Gil Larsen, DDS, at 530.677.4256.

**OFFICE FOR RENT/LEASE** — Redding, Calif., 2,900 sq. ft., five-plus operator dental office in nice part of town. Must see. Upstairs: patient bathroom, spacious waiting room, business office with chart cabinets, private office, small doctors' laboratory, sterilization area and area for pano or X-ray developing; all operatories plumbed for nitrous and locked tank storage; all operatories wired for wall mounted X-ray units; three X-ray units in place; all operatories have Cat 5 cabling for computer/digital hook ups; some equipment and furniture available with lease; alarm system in place; adequate parking and more. Downstairs: open-air basement includes two bathrooms, supply storage room, computer server room, kitchen, and more. Gross production in past \$1.25 million on four days per week/48 week schedule. Contact Soren H. Jacobsen, DDS, 530.510.1186 or email to sorendds@gmail.com.

**PAYROLL COMPLETE UP TO 5 EMPLOYEES**  
**\$19<sup>.99</sup>** PER PAYROLL

**FREE Set-Up - FREE First Month - FREE "Forever" Digital Archiving**

**All inclusive payroll includes Quarterly and Annual Reports and Taxes Paid!**

**Easy to Use: Log on ✓ Enter Hours ✓ Log off. We do the rest.**

**866-840-3400**

**\*No recurring monthly, only pay for what you use**

**\*We pay your workers comp thru the system**

**\*Taxes paid using EFTPS for your protection**

**\*Phones always answered by a live person**

**\*No paper to store or have destroyed**

**\*Direct Deposit Available**

**WWW.Green60.com**

Payroll Processing  
 by  
**green**  
 60.COM®

CONTINUES ON 786



**Specialists in the Sale and Appraisal of Dental Practices**  
***Serving California Dentists since 1966***  
**How much is your practice worth??**  
***Selling or Buying, Call PPS today!***

**Practices  
Wanted**

**NORTHERN CALIFORNIA**  
**(415) 899-8580 – (800) 422-2818**  
**Raymond and Edna Irving**  
**Ray@PPSsellsDDS.com**  
**www.PPSsellsDDS.com**  
**California DRE License 1422122**

**SOUTHERN CALIFORNIA**  
**(714) 832-0230 – (800) 695-2732**  
**Thomas Fitterer and Dean George**  
**PPSincnet@aol.com**  
**www.PPSDental.com**  
**California DRE License 324962**

**RARE OPPORTUNITY - SAN FRANCISCO'S EAST BAY - VERY TRENDY LOCATION**  
**2012 collected \$1.9 Million. 2013 trending \$2.2+ Million with Available Profits of \$1.3 Million.**

Performance realized by One Dentist. Surprisingly, this practice is not close to realizing its potential. Smart Successor who tweaks the practice where it needs to be tweaked shall then make this into something special. Paperless and digital. Ambitious SoCal Dentist who is not averse to commuting should consider this opportunity. Location shall be constant New Patient generator. Great Two Dentist purchase.

Make this a "One Stop" Shop. Little competition with phenomenal upside.

**Full Price \$1.2 Million. Contact Ray Irving at 415-899-8580 or Ray@PPSsellsDDS.com.**

- 6052 BERKELEY** Trendy north side shopping area. Very strong foundation. 2,000 active patients. 4-days of Hygiene. Beautiful hi-tech office with great curb appeal. 2012 collected \$590,000. Lots of work referred out.
- 6050 MERCED** 2013 trending \$360,000. Very profitable. Refers Endo, OS & Perio. Not a Delta Premiere Practice. Great foundation to build upon. Full Price \$150,000.
- 6048 SALINAS** Great opportunity for the ambitious, Ideal for two Dentists. 10 days of Hygiene per week. 2012 collected \$1.1 Million. 2013 tracking \$1.2 Million. Practice did well during Great Recession.
- 6047 STOCKTON** Best location outside Brookside Community on West March Lane. Annualized revenues of \$540,000. Attractive 3-Op office. Package sale includes condo.
- 6046 PINOLE** Collected \$500,000 in 2012. 4-days of Hygiene produced \$178,600. Beautiful office. Refers Endo. Lots of Goodwill here.
- 6045 MANTECA / MODESTO AREA'S RIPON** Great location. 3 Ops, 2 more wired & plumbed. \$180,000 invested here. Practice did more when Owner worked harder. 2012 collected \$327,000 on 3-day week with 5-weeks off.
- 6044 MODESTO** Best location. New development occurring nearby. Collects \$380,000. Digital with computers in Ops. Very attractive office.
- 6043 EL SOBRANTE** 3-day practice collected \$170,000 in 2012. 3-Ops. Building optional purchase.
- 6041 PLEASANT HILL** Collected \$365,000 with Profits of \$142,000 in 2012. Owner slowing down. Previous 3-years averaged collections of \$415,000 and Profits of \$180,000.
- 6040 SANTA ROSA** Beautiful 4-Op office. Paperless and digital. Collected \$480,000 in 2012. Should have done more! Prior year did \$625,000. Package includes condo.
- 6039 CALIFORNIA'S SOUTH LAKE TAHOE.** Long established. 2012 collected \$515,000 with 30 Op units off. Realized Profits of \$230,000+. Attractive 3-Op office.
- 6008 MENDOCINO COAST'S FORT BRAGG** Cultural haven offers attractive lifestyle. 2012 collected \$750,000. 2013 shall top \$800,000. 4-days of Hygiene. Digital radiography. Computers in Ops. Full price \$235,000.

**\*\*FOUNDERS OF PRACTICE SALES\*\***

120+ years of combined expertise and experience!  
3,000+ Sales - - 10,000+ Appraisals

**\*\*CONFIDENTIAL\*\***

PPS Representatives do not give our business name when returning your calls.

- TEMECULA - MURIETTA VALLEY** Hi identity. Classic GP. Gorgeous 6-Op office. Grosses apprx \$800K. Right Buyer can gross to \$2 Million in 5-years. Valuable Dental/Professional Building also available.
- PASADENA AREA** \$6K-to-\$7K/mth in HMO. Grossing \$750,000 part-time. Did \$1+ Million when Owner spent more time here. Full Price \$850,000.
- FONTANA** 100,000 autos pass daily. Hispanic. PT Owner grosses \$250K. FT Successor should Gross \$500K+. Remodeled. Firm price \$275,000.
- ALISO VIEJO** Best Shopping Ctr location. Grosses almost \$1 Million. 5 ops "state-of-the-art". PT Owner. Wants "hands-on" Owner. Work here, live at beach! Over 70 NPs/month. FP \$900,000.
- CUCAMONGA** 50 NPs/mth. Located off freeway exit. 5-ops. Beautiful. Grossed \$850K in 2012. Should do \$1.2 in 2013. FP \$850,000.
- RIVERSIDE** Hi Identity building 4 Sale. Elegant 5-ops. CT digital Pan & x-rays. PT Conservative Female Owner Grossed \$550K. One PPO. Full-time Successor shall do better.
- RIVERSIDE** Grosses \$1.3 Million. \$6-to-\$7K/mth from HMO. Does ortho. 10-ops in 3,000 sq.ft. with low rent. Hi identity Shopping Ctr near Wal-Mart. FP \$1 Million.
- IRVINE** Grossed \$1.2 Million in 2012. 2013 should do \$1.3+. 5-ops. Absentee Owner. Unique transition assistance available. FP \$1 Million.
- SAN FERNANDO VALLEY** Best location. Grosses \$1.2 Million. Lots of work referred. This is \$2 Million location. 8-ops. 30 Hygiene pts/day. Full price \$1.2 Million.
- SAN FERNANDO VALLEY – BEST HISPANIC LOCATION** 7 state-of-art Ops, room to expand. 70 NP's/mth. Building part of sale. Another \$2 Million location.
- TORRANCE – GARDENA** Very conservative Chinese DDS. Lots of work referred. Young Chinese/AM Successor will do \$600K. FP \$185,000.
- LANCASTER** Established location. Equipped. Seller needed more room. Many walk-ins each day. Seller did \$900,000 here. FP \$125,000.
- BALDWIN PARK** 80% Hispanic. High identity building. 3-ops. Grosses \$250,000. FP \$150,000.
- BAKERSFIELD** Grosses \$750,000. Established 50-years. 5-ops. Successor should do \$1 Million. FP \$500,000.
- SMALL TOWN NEAR BAKERSFIELD** Practice & RE. Gross \$400,000 with full time DDS. Practice & Building \$350,000.
- ORANGE** Female DDS doing \$30-to-\$40K/mth part-time. Seller will work-back for smooth transfer. FP \$295,000.
- VICTOR VALLEY** High Identity Shopping Center. Grosses \$650,000. 8-ops, low overhead. FP \$550,000.
- REDLANDS** Low overhead, 5-ops, digital. Gross \$30,000+/mth. FP \$350,000.
- NEVADA** Small resort city near Las Vegas. 5 state-of-art Ops. Grosses \$600K 3-days. Will do \$600K more with 3 more days. FP \$600,000.
- DENTURE CENTER** 30+ denture patients/day. Grosses \$1.3 Million. Patients ask "Will you do Implants?" Answer always "We just do dentures." Specialist will take to \$2 Million. FP \$1 Million.

CLASSIFIEDS, CONTINUED FROM 784

## OFFICES FOR RENT/LEASE

**PRACTICE FOR SALE** — Garden Grove general practice with more than 30 years of goodwill. The office is located in a well-known professional building adjacent to Garden Grove Hospital. The office consists of four operatories, private office, chart room, two restrooms, combined central sterilization and minilab, with the larger lab down the hall. There are three X-ray units, Panorex and an automatic film processor. The office is paperless and electronically submits claims. Recent complications have made it difficult for the dentist to continue to practice. This is a great opportunity for a dentist wishing to merge his practice and enlarge the patient base, or a full-time associate who desires to work part-time building a practice of his/her own. The owner-dentist is available by appointment for any questions or concerns regarding the office and transition. Send email to Whitney Tharaldson, Select Practice Services Inc. at wtharaldson@gmail.com or call 626.384.8080.

**PRACTICE FOR SALE** — General and ortho practice for sale at a great price. Practice for sale in Mojave, Calif. It has been both a general and ortho practice for a long time. Call 805.259.5147 for more detail. Asking \$55,000.

**PRACTICE FOR SALE** — A terrific general practice opportunity in San Diego. This gem consistently collects well above \$800k with four fully equipped operatories, sterilization room, adj. lab, digital X-rays and 7.5 days of hygiene/wk. This well-maintained seller-owned building has two 1,200 sq. ft. suites, which could be connected for expansion. This is an exceptional turnkey practice for a new or experienced clinician looking for an opportunity to work with great patients and a stellar team. Owner retiring. Asking \$725,000. Contact trish@paragon.us.com or call 858.243.1901.



## PRACTICE SALES AND LEASING



Paul Maimone  
Broker/Owner

**Time to Sell? Inventory & Rates are Still Low! Buyer Demand is Still High!**

**BAKERSFIELD #26** — 3,500 sq ft free stand. duplex bldg. w a (5) op fully equipped turnkey dental office. Located on a main thoroughfare w monument signage. Move in condition.

**BAKERSFIELD #27** — (4) op comput G.P. starter pract. 2 ops of new eqt. (2) add. plmbd ops. Opened June 2012. (12) mos Gross Collect \$75K p.t. & growing. Mixed pts. Seller moving. **NEW**

**BEVERLY HILLS** — Great startup or second office. (2) op Turnkey Office. Leaseholds & eqt'd. No charts. Located in a smaller two story prof. bldg. on a main thoroughfare. Low rent. **NEW**

**CENTRAL VALLEY/So. FRESNO COUNTY** — (3) op comput. G.P. in smaller town w ltd. competition. Newer eqt. Networked & digital. Dentrix & Dexis. Gross Collect \$40K+/mos.

**CORONA** — Dental Spa & Free Stand. Bldg. for sale. (5) op comput. G.P. w (2) spa rooms; one for facials & one for massage. Drop dead gorgeous facility w all the special touches. New eqt. Digital X-rays. Pano eqt'd. Production of \$1.0M+ on a (4) day week.

**EAST VENTURA COUNTY** — (3) op compt. G.P. Fee for Service. Located in a smaller prof. bldg. w some exposure & visibility. Pano eqt'd. 2013 Proj. Gross Collect \$500K. **PENDING**

**ENCINO** — (4) op compt G.P. in a well-known, recently remodeled prof bldg. on a main thoroughfare. Magnificent panoramic Valley views in (3) ops. Cash/Ins/PPO. Gross Collect \$600K/yr on a (4) day week. Digital X-Rays & laser eqt'd. 34+ yrs of Goodwill. **NEW**

**HAWTHORNE** — (7) op compt. G.P. in a free stand. bldg. on a main St. Exposure & visibility. (6) ops fully eqt'd. Digital X-rays. Cash/Ins/PPO. Many walk-ins. Collecting \$30K+/mos. **NEW**

**OXNARD #7** — (5) op turnkey G.P. No pts. In a free stand bldg. on a main thoroughfare.

**SAN JOAQUIN VALLEY** — G.P. & Bldg. in small town w ltd. competition. (4) op comput. office. Cash/Ins/PPO. Annual Gross Collect \$500K+. Low overhead. Seller retiring. **REDUCED**

**SANTA CLARITA VALLEY** — Cash/Ins/PPO bread and butter practice. (4) ops eqt'd. Located in a medical/dental/professional bldg. complex. 40+ yrs of Goodwill. Seller retiring. **NEW**

**TOLUCA LAKE** — Starter Pract. (4) op comput. G.P. (2) ops eqt'd w new eqt./ (2) plmbd. Digital X-rays. In free stand. bldg. Main thoroughfare. Collect ~ \$10k/mos on (1) day/wk **SOLD**

**WEST SAN FERNANDO VALLEY PEDO/ORTHO OFFICE** — Comput. Pedo/Ortho office. (3) op open bay & (1) op quiet room. Pano eqt'd. Digital X-rays. Cash/Ins/PPO small % Denti-Cal. 30+ years of Goodwill. Annual Gross Collect \$600K+. Seller retiring but will assist with transition and/or stay to do Ortho.

**WOODLAND HILLS #4** — Beautiful state of the art (9) op comput G.P. in a Shop Ctr. on a main thoroughfare. Excellent exposure/visibility/signage! (6) ops eqt'd w newer eqt. (3) add. plumbed. 2013 Projected Gross Collect \$370K on a 3-3.5 day wk. Cash/Ins/PPO/HMO pts. **PENDING**

**UPCOMING PRACTICES:** Agoura, Alhambra, Beverly Hills, Camarillo, Covina, Glendora, Montebello, Monrovia, Pasadena, SFV, Torrance, Ventura, West Covina, & Westchester.

**D & M SERVICES:**

- Practice Sales & Appraisals
- Practice & Equipment Financing
- Expert Witness Court Testimony
- Pre - Death and Disability Planning
- Practice Search & Matching Services
- Locate & Negotiate Dental Lease Space
- Medical/Dental Bldg. Sales & Leasing
- Pre - Sale Planning

P.O. Box #6681, WOODLAND HILLS, CA. 91365  
Toll Free 866.425.1877 Outside So. CA or 818.591.1401 Fax: 818.591.1998  
www.dmppractice.com CA DRE Broker License # 01172430

CA Representative for the National Association of Practice Brokers (NAPB)



# EXPERIENCE THE DIFFERENCE

- Lee Skarin and Associates has been serving the dental profession since 1959.
- Kurt Skarin has over 30 years experience in dental practice sales.
- We have sold more practices than any broker in the state within the last 12 months.
- Our experienced practice appraisals are backed with credentials unequaled among dental practice brokers.
- We provide in-house legal counsel to advise you in all aspects of the sale and purchase, including the tax consequences of the sale.
- Excellent financing is available, in most cases for 100% of the purchase price.
- With a reputation for experienced, conscientious, and ethical performance, we give our clients personal attention in all aspects of the purchase.



With scores of Buyers, profiles of their practice interests and financial ability, **Lee Skarin & Associates** is able to find the right buyer for your practice.

*Experience the difference. Call Lee Skarin and Associates for responses to all of your questions - No obligation!*

Visit our website for current listings: [www.LeeSkarinandAssociates.com](http://www.LeeSkarinandAssociates.com)

Dental Practice Brokers CA DRE #00863149



# LEE SKARIN & ASSOCIATES INC.



**Offices:**  
805.777.7707  
818.991.6552  
800.752.7461



## ADVERTISER INDEX

California Practice Sales	calpracticesales.net	774
CariFree	carifree.com	758
Carroll & Company Practice Sales	carrollandco.info	783
CDA Membership	cda.org/member	733
CDA Practice Support	cdacompass.com	738-739
D&M Practice Sales	dmpractice.com	786
Dental Post	dentalpost.net	780
Dentapreg, ADM a.s.	dentapreg.com	770
Green60	green60.com	784
Implant Direct	implantdirect.com	734
Keller Laboratories	kellerlab.com	791
Lee Skarin & Associates	leeskarinandassociates.com	787
Paragon Dental Practice Transitions	paragon.us.com	782
Practice Transition Partners	practicetransitions.com	778
Professional Practice Sales of the Great West	415-899-8580	785
Professional Practice Transitions	pptsales.com	781
TDIC	tdicsolutions.com	726
TOLD Partners	told.com	775
Ultradent	ultradent.com	792
UCSF School of Dentistry	echow@medicine.ucsf.edu	752
US Bank	usbank.com/practicefinance	732
Western Practice Sales/John M. Cahill Associates	westernpracticesales.com	776-777
Willamette Dental	willamettedental.com	779

FOR ADVERTISING INFORMATION, PLEASE CONTACT COREY GERHARD AT 916.554.5304.

CONTINUED FROM 790

The point is there have always been suspicion, distrust and downright animosity between the northern and southern halves of the state. The Southerners extolled their weather, trying at the same time to downplay their smog, and were regarded by Northerners as a laid-back, flakey bunch of certifiable nut cases. The Southerners, when they bothered to reply at all, cited Haight-Ashbury as not exactly Park Avenue, but resented smug San Franciscans for having two bridges over real water.

This went on for years, and everybody agreed that the San Andreas Fault should have run east-west instead of north-south so that eventually (perhaps next Tuesday) we could be separated physically as well as culturally.

Paradoxically, just 20 years ago, the two dental societies representing the northern and southern dental communities decided that individually they had more foibles than Aesop. So, for their mutual benefit, they would join and form the California Dental Association. Actually, there had always been a CDA, this being the name the northern contingent had always had. The Southerners whacked the “S” off their name to make it unanimous.

This momentous decision was heralded as the right thing to do, uniting the two halves of the state as never before, eliminating duplications of paperwork, personnel and office space. Merging the two treasuries was a little more complicated.

“How much you got?” demanded the Southerners, holding their checkbook very close to the chest.

“Forty-two million zillion dollars,” replied the Northerners. “Match that and we have a deal.”

“No problem,” lied the Southerners. “We have on hand here — uh, lessee — 59 quintillion dollars and 79 cents.”

## Finally, all parties agreed to the venue when it was pointed out that Sacramento was the state capital, after all, and not Burbank, as many supposed.

This went on for a while, kind of like hammering out a prenuptial agreement. They finally deposited \$18.48 in their new account, and the new association was born with Burt Press as the first president.

While the Southern delegation was out celebrating the occasion with taco parties in their hot tubs, it was decided to make the headquarters of the newly formed CDA in Sacramento, a mere 90 miles up the road in a northeasterly direction from San Francisco. It was reported at the time that there was some dissension among the Southern dentists, many of whom had never been to Sacramento, believing instead that it was a popular Mexican expression of dismay.

Flushed with the success of the merger, the old CDA, in the spirit of compromise, offered the headquarters of the new CDA to Los Angeles for a short time. Then the delegates began showing up at meetings in really ugly Bermuda shorts and thongs, making it difficult for ADA to take the new group seriously. So the whole shebang was finally moved north to Sacramento, where it is today. Few noticed until later that Sacramento was about as far away from San Diego as Buffalo, New York, and by that time it was too late: letterheads had been printed and CDA’s very own post office box had been assigned.

Finally, all parties agreed to the venue when it was pointed out that Sacramento was the state capital, after all, and not Burbank, as many supposed. This fact would enable CDA lobbyists to better exert their influence on the governor and the legislators on those infrequent occasions when these luminaries happened to be in town between recesses, fact-finding junkets and fence-mending visits to their constituents.

On this 20th anniversary, then, of the farsighted fusion of the Northern California Dental Association and the Southern California Dental Association, congratulations!

Your Association officials, understandably proud, have extended an open invitation whenever you are in Sacramento to drop by 1201 K Street and check out your CDA headquarters building. They have suggested, however, that all 18,000 of you do not come at once. (And bring no illusions with you about their springing for lunch!) ■■■■

## We’re Taking Your Requests

*If you have a favorite Dr. Bob column you want to see again, send an email to Publications Specialist Andrea LaMattina at [andrea.lamattina@cda.org](mailto:andrea.lamattina@cda.org). We will oblige by reprinting those requested favorites interspersed with any new Dr. Bob submissions.*

# United We Debate



The Southerners extolled their weather, trying at the same time to downplay their smog.

→ Robert E. Horseman, DDS

ILLUSTRATION  
BY VAL B. MINA

*This Dr. Bob was originally printed in the July 1992 Journal.*

Anyone who has driven the length of California from Chula Vista to Crescent City in the presence of a back seat full of kids can affirm that California is a long state. That's why Santa Barbara is home to so many people. It was not because of the palm trees or beaches, or because Santa Barbara had the distinction of zealously cherishing until recently the only traffic signal on a major freeway between the Mexican border and Oregon.

Whether driving north or south, people would say when they reached Santa Barbara, "Well, that's it! I'm not going another mile in this car with those kids!" And they would trade the car for a surfboard, buy a house and never leave home again. So California is a lengthy state, about 900 miles of it if you can believe the \$2.50 map that you used to get free at service stations before they discarded the concept of service in favor of indifferent caretakers silently regarding you with suspicion from behind thick glass barricades.

Ever since California was granted statehood in 1850, there have been groups of dissident citizens who believe the Golden State should have been divided into two states, much like North and South Dakota. Many of these same people either seriously doubt that there are such states as the Dakotas, or if there are, contend that Seward, while negotiating for Alaska, should have swapped them for British Columbia.

CONTINUES ON 789



## The Right Tool for Every Indication.



**The NTI-tss Plus is clearly a versatile tool.** Unlike other bite guards, the NTI-tss Plus is the right tool for nearly every patient. From the Nighttime Lower to the Migraine Therapy set, there's a design for every indication. And they all protect teeth, muscles and joints by suppressing nearly 70% of parafunctional muscle contraction. All with less chair time and more comfort. NTI-tss Plus. Clearly better.

**Get the tools you need today!**  
Call for your consultation or case pick-up.  
**(800) 325-3056**

**keller**  
kellerlab.com



Shipping is **FREE** when you bundle  
2 or more cases of any kind in one box.  
Offer limited to contiguous United States.

Made in the USA





With  
**UltraFit  
Tray**

Scan for a  
**Free Sample**  
or visit [opalescence.com/  
go/free-sample.aspx](http://opalescence.com/go/free-sample.aspx)




Opalescence®  
● ● ● *go*

# Be Bright

Powerful, professional  
whitening. To go!

Introducing Opalescence Go. For a more adaptable, more comfortable whitening experience. Opalescence Go offers complete molar-to-molar coverage. And its new UltraFit tray easily conforms to any patient's individual smile, ensuring the maximum amount of gel stays in contact with the teeth during whitening.



**PROUD USA  
MANUFACTURER** Ultradent is a proud USA  
manufacturer. To learn more  
visit [ultradent.com/USA](http://ultradent.com/USA)



800.552.5512 | [ultradent.com](http://ultradent.com)  
© 2013 Ultradent Products, Inc. All Rights Reserved.



**ULTRADENT**  
PRODUCTS, INC.  
Improving Oral Health Globally