

OF THE CALIFORNIA DENTAL ASSOCIATION

# Journal

MAY 2013

Premalignant and Malignant  
Lesions

Diagnosis and Management  
of Mucosal Lesions

Human Papillomavirus

Part Two

## ORAL MEDICINE UPDATE:

### ORAL CANCER ~ SCREENING, LESIONS and RELATED INFECTIONS

Joel M. Laudenschach,  
DMD

# Bundling is Optimum.

## Good

**10%** discount on Professional Liability when combined with Workers' Compensation

## Better

**10%** discount on both Professional Liability + Office Property when combined

## Optimum

Or, when you bundle three:

**20%** discount on Professional Liability

**10%** discount on Office Property

**5%** discount on Workers' Compensation

**Bonus:** **Additional 5% discount** on Professional Liability when you take the current TDIC Risk Management seminar.

**Protecting dentists.  
It's all we do.®**

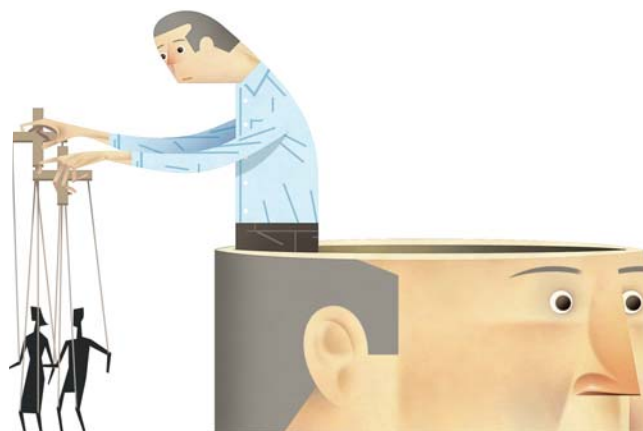
800.733.0633 | [tdicsolutions.com](http://tdicsolutions.com) | CA Insurance Lic. #0652783

Discounts apply to individual policies and are not cumulative. To obtain the Professional Liability premium five (5) percent, two-year discount, California dentists must complete the current TDIC Risk Management seminar. Call 800.733.0634 for current deadlines and seminar details.



## DEPARTMENTS

- 305** The Editor/*Unnecessary for Gentlemen*
- 311** Impressions
- 319** CDA Presents
- 357** Classifieds
- 368** Advertiser Index
- 370** Dr. Bob/*Savoring the Service Agreement*



311

## FEATURES

- 326** **ORAL MEDICINE UPDATE: ORAL CANCER — SCREENING, LESIONS AND RELATED INFECTIONS**  
*An introduction to the issue.*  
 Joel M. Laudenbach, DMD
- 329** **STANDARD EXAMINATION AND ADJUNCTIVE TECHNIQUES FOR DETECTION OF ORAL PREMALIGNANT AND MALIGNANT LESIONS**  
*This article outlines how to perform a standard comprehensive extraoral and intraoral examination and the existing commercially available adjunctive techniques for the early detection of oral cancer and premalignant lesions.*  
 A. Ross Kerr, DDS, MSD, and Sonal S. Shah, DDS
- 343** **DIAGNOSIS AND MANAGEMENT OF MUCOSAL LESIONS WITH THE POTENTIAL FOR MALIGNANT TRANSFORMATION**  
*Oral lichen planus and epithelial dysplasia are two of the most common types of oral lesions with the potential for malignant transformation. The epidemiology and management of these conditions are discussed in this review.*  
 Bassam Issa, BDS; Ricardo Padilla, DDS; and Michael T. Brennan, DDS, MHS
- 349** **HUMAN PAPILLOMAVIRUS: THE FUNDAMENTALS OF HPV FOR ORAL HEALTH CARE PROVIDERS**  
*This review provides an overview of human papillomavirus, its association with HIV and oropharyngeal cancer and information on HPV vaccinations.*  
 Katharine Ciarrocca, DMD, MEd; Lana L. Jackson, MD, PharmD, FACS; and Scott S. De Rossi, DMD

# Submitting a manuscript to the Journal? There's a site for that.



In fact, from letters to the editor to reviews, the new site is now the only way to submit anything to the *Journal of the California Dental Association*.

Upload your content, receive automatic status updates, even track progress anytime day or night. See for yourself at [www.editorialmanager.com/jcaldentassoc](http://www.editorialmanager.com/jcaldentassoc)



## Journal of the California Dental Association

published by the  
California Dental  
Association  
1201 K St., 14th Floor  
Sacramento, CA 95814  
800.232.7645  
[cda.org](http://cda.org)

**Management/Editorial**  
Kerry K. Carney, DDS, CDE  
EDITOR-IN-CHIEF  
[Kerry.Carney@cda.org](mailto:Kerry.Carney@cda.org)

Ruchi K. Sahota, DDS, CDE  
ASSOCIATE EDITOR

Brian K. Shue, DDS, CDE  
ASSOCIATE EDITOR

Peter A. DuBois  
EXECUTIVE DIRECTOR

Jennifer George  
CHIEF MARKETING OFFICER

Cathy Mudge  
VICE PRESIDENT,  
COMMUNITY AFFAIRS

Alicia Malaby  
COMMUNICATIONS  
DIRECTOR

Andrea LaMattina  
PUBLICATIONS SPECIALIST

Robert E. Horseman, DDS  
CONTRIBUTING EDITOR

Joel M. Laudenbach, DMD  
GUEST EDITOR

Blake Ellington  
STAFF WRITER

Courtney Grant  
COMMUNICATIONS  
SPECIALIST

Jack F. Conley, DDS  
EDITOR EMERITUS

# Journal

OF THE CALIFORNIA DENTAL ASSOCIATION

CDA Journal  
Volume 41, Number 5  
MAY 2013

## Advertising

Corey Gerhard  
ADVERTISING MANAGER

Jenaé Gruchow  
PROJECT/TRAFFIC  
ADMINISTRATOR

Erin Jernigan  
ASSISTANT COORDINATOR

## Production

Val B. Mina  
SENIOR GRAPHIC  
DESIGNER

Randi Taylor  
SENIOR GRAPHIC  
DESIGNER

Ann Davis  
GRAPHIC DESIGNER/  
PRODUCTION ARTIST

## California Dental Association

Lindsey A. Robinson, DDS  
PRESIDENT  
[president@cda.org](mailto:president@cda.org)

James D. Stephens, DDS  
PRESIDENT-ELECT  
[presidentelect@cda.org](mailto:presidentelect@cda.org)

Walter G. Weber, DDS  
VICE PRESIDENT  
[vicepresident@cda.org](mailto:vicepresident@cda.org)

Kenneth G. Wallis, DDS  
SECRETARY  
[secretary@cda.org](mailto:secretary@cda.org)

Clelan G. Ehrler, DDS  
TREASURER  
[treasurer@cda.org](mailto:treasurer@cda.org)

Alan L. Felsenfeld, DDS  
SPEAKER OF THE HOUSE  
[speaker@cda.org](mailto:speaker@cda.org)

Daniel G. Davidson, DMD  
IMMEDIATE PAST  
PRESIDENT  
[pastpresident@cda.org](mailto:pastpresident@cda.org)

## Reader Guide:

### Upcoming Topics

JUNE: *General Topics*  
JULY: *Ethical Dilemmas*  
AUGUST: *Children's Care*

**Classified Advertising**  
[cda.org/classifieds](http://cda.org/classifieds)

### Display Advertising

Corey Gerhard  
ADVERTISING MANAGER  
[Corey.Gerhard@cda.org](mailto:Corey.Gerhard@cda.org)  
916.554.5304

### Letters to the Editor

[www.editorialmanager.com/jcaldentassoc](http://www.editorialmanager.com/jcaldentassoc)

### Permission and Reprints

Andrea LaMattina  
PUBLICATIONS SPECIALIST  
[andrea.lamattina@cda.org](mailto:andrea.lamattina@cda.org)  
916.554.5950

### Manuscript Submissions

[www.editorialmanager.com/jcaldentassoc](http://www.editorialmanager.com/jcaldentassoc)

### Subscriptions

The subscription rate is \$18 for all active members of the association. The subscription rate for others is as follows:  
*Non-CDA members and institutional: \$40*  
*Non-ADA member dentists: \$75*  
*Foreign: \$80*  
*Single copies: \$10*  
Subscriptions may commence at any time. Please contact:  
Andrea LaMattina  
PUBLICATIONS SPECIALIST  
[andrea.lamattina@cda.org](mailto:andrea.lamattina@cda.org)  
916.554.5950

*Journal of the California Dental Association* (ISSN 1043-2256) is published monthly by the California Dental Association, 1201 K St., 16th Floor, Sacramento, CA 95814, 916-554-5950. Periodicals postage paid at Sacramento, Calif. Postmaster: Send address changes to *Journal of the California Dental Association*, P.O. Box 13749, Sacramento, CA 95853.

The *Journal of the California Dental Association* is published under the supervision of CDA's editorial staff. Neither the editorial staff, the editor nor the association are responsible for any expression of opinion or statement of fact, all of which are published solely on the authority of the author whose name is indicated. The association reserves the right to illustrate, reduce, revise or reject any manuscript submitted. Articles are considered for publication on condition that they are contributed solely to the *Journal*.

Copyright 2013 by the California Dental Association.





## Unnecessary for Gentlemen

BRIAN SHUE, DDS, CDE

**N**urses are the most ethical professionals. Members of Congress and car salespeople are the least ethical. Surprised? Those are the findings of the Gallup poll “Honesty/Ethics in Professions” from December 2012.<sup>1</sup>

Each year, 1,015 randomly sampled adults 18 and older across the U.S. are asked this question: “Please tell me how you would rate the honesty and ethical standards of people in these 22 fields — very high, high, average, low or very low?” There is a  $\pm 4$  percentage maximum margin sampling error.

Health professionals are the most trusted, capturing four of the top five choices. Nurses received a combined 85 percent of “very high” or “high” marks. Rounding out the top were pharmacists (75 percent), medical doctors and engineers (tied at 70 percent each) and dentists (62 percent). Two other health professions scored slightly above average: psychiatrists (41 percent) and chiropractors (38 percent).

Gallup reports the highest score ever achieved was 90 percent by firefighters — in the poll conducted just after the 9/11 tragedy. This annual poll does not include every profession each year (for instance, telemarketers and funeral directors will have to wait for another year). Gallup has included the dentist category in its recent polls about every three years.

Three out of five believe dentists have high ethical standards, which matches our highest score from 2006. Dentists in the last decade have received a rating of at least 56 percent, which is higher than the usual 50 percent-range that dentists have earned since first being included in the poll in 1981.



**Three out of five believe dentists have high ethical standards, which matches our highest score from 2006.**

On the other hand, two out of five don’t regard dentists as highly trustworthy. Gallup polls didn’t exist back then, but what would our dental forefathers think? We have come a long way from the 19<sup>th</sup> century dental charlatans and quacks who roamed the streets plying the trade of dentistry without respect from the general public nor the medical profession. It took great strides, too numerous to mention, to elevate dentistry in the U.S. into the respected profession of today.

Early dental organizations, from the local to the national level, endeavored to bring art, science, professionalism and ethics to prominence in our field. Although not the first or even second national dental organization, the ADA arrived in 1859 and obviously survived the 19<sup>th</sup> century. It adopted a constitution the next year, which included an article that targeted the nonethical dentist member:

Conduct of Members — Any acts of special immorality or unprofessional conduct committed by a member of this Association, shall be referred to the Committee of Arrangements, whose duty it shall be to thoroughly examine into the case and report at the next meeting, if the charges be sustained. Whereupon, by vote, the offending member may be

reprimanded or expelled: a two-thirds vote being required for expulsion, a plurality vote being sufficient for a reprimand.<sup>2</sup>

But there’s more. On Aug. 3, 1866, leaders at the ADA annual meeting debated the merits of a freshly written Code of Ethics. Ethics Committee Member and Immediate Past ADA President John H. McQuillen stated “on general principles (he) was opposed to its adoption, as unnecessary for gentlemen, and its enforcement impracticable upon those who were not.” But after much discussion very late into that Friday night, it passed.<sup>3</sup>

Although it paled in comparison to the scope of our current 6,900-word membership-binding ADA Principles of Ethics and Code of Professional Conduct, the original ADA Code of Ethics clearly captured the essence of doing the right thing — in less than 730 words.

There is much to learn from this original document. In order to push our ethics forward and earn more of the trust of today’s public, let’s take a step back and learn from the past. Here are major points from the 1866 ADA Code of Ethics in its exact language:

- The dentist should be ever ready to respond to the wants of his patrons, and should fully recognize the obligations involved in the discharge of his duties toward them.

- It is not to be expected that the patient will possess a very extended or a very accurate knowledge of professional matters.
  - The dentist should be temperate in all things, keeping both mind and body in the best possible health, that his patients may have the benefit of that clearness of judgment and skill which is their right.
  - A member of the dental profession is bound to maintain its honor, and to labor earnestly to extend its sphere of usefulness.
  - The person and office arrangements of the dentist should indicate that he is a gentleman; and he should sustain a high-toned moral character.
  - When consulted by the patient of another practitioner, the dentist should guard against inquiries or hints disparaging to the family dentist.
  - Dental surgery is a specialty in medical science.
  - Dentists are frequent witnesses, and, at the same time, the best judges of the impositions perpetrated by quacks; and it is their duty to enlighten and warn the public in regard to them.
- Though simply worded, the Code made profound statements almost 150 years ago to advance our profession.

Omitted here are a few points made in the Code that aren't relevant in today's world (such as prohibition of advertising) and no attempts were made to alter the document to make it gender neutral.

Once again, we need to prove ourselves to the public. Our public's image of the honesty of our profession should not continue to register as "average," "low," or "very low" in such large Gallup numbers. There is room for improvement.

It is obviously not going to be easy to change the minds of those who do not hold the dentist to such high esteem, yet it is even easier to betray the trust of those who already believe dentists to be honorable. Much can change with every interaction we have with our patients, either positively or negatively. Harken back to the simpler times, when a basic code of ethics helped guide the members of our profession, even before the time that dentistry became regulated and licensed.

Elevate our profession. As the 1866 ADA Code of Ethics states: "For this, and the many other benefits conferred by the competent and honorable dentist, the profession is entitled to the confidence and respect of the public." Those 19<sup>th</sup> century dentists did everything possible to accomplish that.

We have two to three years before the next Honesty and Ethics Gallup poll once again includes dentists. There's time to get it right.

Let's be that 19<sup>th</sup> century dentist. ■■■■

#### REFERENCES

1. Gallup Poll, Honesty/Ethics in Professions, December 2012. [www.gallup.com/poll/1654/honesty-ethics-professions.aspx](http://www.gallup.com/poll/1654/honesty-ethics-professions.aspx).
2. American Dental Association. *The Dental Cosmos* 2(2):97-98, September 1860.
3. Transactions of the American Dental Association, at its Sixth Annual Session. *The Dental Cosmos* 8(2):88-90, September 1866.

**cda cares**  
California Dental Association Foundation

In 2012, with the help of thousands of community and dental volunteers, CDA Cares provided \$2.8 million in free dental care to 3,600 patients in need.

Coming to the  
San Jose Convention Center  
**May 18-19, 2013**

Registration is now open. To see how you can get involved, go to [cdfoundation.org/cdacares](http://cdfoundation.org/cdacares)

**cda**  
FOUNDATION

## ARTiculating Concerns About Interim Therapeutic Restorations

We read with interest the article entitled “The Virtual Dental Home: Bringing Oral Health to Vulnerable and Underserved Populations” by Drs. Glassman, Harrington, et al., and the subsequent article “Community-based Prevention and Early Intervention Strategies” by Drs. Budenz and Subar, both of which appeared in the July 2012 edition of the *Journal of the California Dental Association*.

We congratulate the authors of these two articles for their constructive attempts to make up-to-date approaches to oral health care and prevention more accessible to the vulnerable and underserved communities in California. The importance of this objective cannot be overstated since it is not only pertinent to the reported epidemic of oral disease in these communities in California, but also globally where oral diseases are considered to constitute a pandemic.

In both of these articles, mention is made to what is termed by some in the United States as “interim therapeutic restorations,” or ITR,<sup>1</sup> but which has been known worldwide for more than 25 years and continues to be known as atraumatic restorative treatment or ART.<sup>2</sup>

Dr. Glassman and colleagues state that ART “involves removal of superficial caries using hand or slow-speed rotary instruments and placement of a glass ionomer restorative material.” Later, the authors reiterate the supposedly superficial nature of the caries removal process, stating that in the virtual dental home “the technique consists of using hand-instruments only to remove soft debris and superficial caries to obtain

clean and sound margins with subsequent placement of glass ionomer restorative material.” Our concern is that such statements do not correctly describe the ART approach and lead to a perpetuation of the common misconception we have encountered among numerous dentists in the United States who believe that caries is deliberately left behind in a cavity with the ART approach. The purpose of this letter is both to clarify this seemingly common misconception held only in the United States concerning caries removal using the ART approach and to comment on aspects relating to nomenclature.

The ART approach has been described in detail in many publications.<sup>3</sup> The caries removal procedure used with ART follows a sound scientific understanding of the caries process that has been in existence for more than 50 years.<sup>4</sup> When ART is correctly applied, the objective of the caries removal process is to remove with hand instruments only what is termed “infected dentine,” the soft, infected biomass that has no further structural use to the tooth until a hard surface is obtained which is termed “affected dentine.” This often darker and stained structure is minimally infected with bacteria and has the potential to remineralize. To believe that this constitutes the deliberate leaving behind of caries demonstrates a failure to understand properly the nature of the caries process and the pathology of the caries lesion.

It should be noted, however, that in rare instances, in very deep-caries lesions where there is a risk of pulpal exposure, we recommend as part of the ART procedure, the retention of



some soft dentine in teeth that are vital and otherwise symptomless. While such an approach might be contrary to traditional dictum, it is becoming more and more an accepted approach to avoid pulpal exposures.<sup>5</sup> In this respect, it is pleasing that in the subsequent article by Drs. Budenz and Subar, “Community-based Prevention and Early Intervention Strategies,” the authors support this conservative approach to the management of deep-caries lesions.

These authors acknowledge that “ITR is identical to ART” and quote the American Academy of Pediatric Dentistry’s definition of ITR that proposes it be used “to restore and prevent further decalcification and caries in young patients, uncooperative patients, patients with special health care needs or when traditional cavity preparation and/or placement of traditional dental restorations are not feasible and need to be postponed.”

The article then goes on to describe the advantages of ART (ITR) including success rates that are equivalent to amalgam filling material, superior resistance to recurrent decay, lack of a need for a local anesthesia, less pain and dental anxiety, and greater preservation of tooth tissue. Taking all these and other advantages of ART (ITR) into account makes us question why the American Academy of Pediatric Dentistry considers “traditional cavity preparations and/or placement of traditional dental restorations” to be better than ART. Moreover, we also question why ART should be considered “interim” based on available scientific evidence and, for that matter, why a different nomenclature is needed when referring to ART in the United States.

Since the ART approach and nomenclature have been accepted by major international dental organizations, including the World Health Organization, the FDI World Dental Federation and the Pan American Health Organization, it is only logical that dental practitioners and dental associations worldwide adhere to the same name and definition of ART. If the principal objective of the dental professional is to improve oral health, would it not be better for us all to speak the same professional language?

**CHRISTOPHER HOLMGREN, PHD, BDS, FDSRCS**  
**JO E. FRENCKEN, DDS, MSC, PHD**  
**AIDE ODONTOLOGIQUE INTERNATIONALE**

*Merigny, France*

#### REFERENCES

1. American Academy of Pediatric Dentistry Council on Clinical Affairs Oral Health Policies Reference Manual, *Policy on Interim Therapeutic Restorations (ITR)*, pages 48-9, 2008.
2. Frencken JE, Leal SC, Navarro MF. Twenty-five-year atraumatic restorative treatment (ART) approach: a comprehensive overview. *Clin Oral Investig* 16(5):1337-46, 2012.

3. Holmgren CJ, Roux D, Doméjean S. Minimal intervention dentistry: part 5. Atraumatic restorative treatment (ART) — a minimum intervention and minimally invasive approach for the management of dental caries. *Br Dent J* 214(1):11-8, 2013.
4. Fusayama T, Okuse K, Hosoda H. Relationship between hardness, discoloration, and microbial invasion in carious dentin. *J Dent Res* 45:1033-46, 1966.
5. Maltz M, Jardim JJ, Mestrinho HD, Yamaguti PM, Podestá K, Moura MS, de Paula LM. Partial removal of carious dentine: a multicenter randomized controlled trial and 18-month follow-up results. *Caries Res* 47(2):103-9, 2013.

#### Prevention Is Key

Dr. Bob's article on bacteria in the March 2013 *Journal* was written in his usual tongue-in-cheek style, however, it was one of the best pieces I have read recently on the relationship to the microorganisms we live with.

Perhaps it is time for us to recognize that we live with and are part of our biomass. This is why we have an immune system.

As health practitioners, our job is to help our patients maintain the balance between the factors that contribute to health and those that contribute to illness. Antibacterial agents are useful when our oral microorganisms are allowed to get out of balance and cause some pathology. They are not needed if the bacteria are not allowed to get out of balance in the first place. Most dental disease is caused by opportunistic infections that occur when our normal oral microorganisms are allowed to get out of balance.

For this reason, it makes good sense to support good health rather than having to constantly fight disease. This means supporting a healthy lifestyle by eating foods that are not harmful to our health. It also means maintaining healthy daily hygiene habits.

People can no longer afford the luxury of having to do expensive repairs when most dental disease is preventable.

**PHILIP HORDINER, DDS**  
*Los Altos, Calif.*

#### The Journal of the California Dental Association welcomes letters.

*We reserve the right to edit all communications and require that all letters be signed. Letters should discuss an item published in the Journal within the past two months or matters of general interest to our readership. Letters must be no more than 500 words and cite no more than five references. No illustrations will be accepted. Letters may be submitted at [editorialmanager.com/jcaldentassoc](mailto:editorialmanager.com/jcaldentassoc). By sending the letter to the Journal, the author certifies that neither the letter nor one with substantially similar content under the writer's authorship has been published or is being considered for publication elsewhere, and the author acknowledges and agrees that the letter and all rights of the author with regard to the letter become the property of the California Dental Association.*





## **It's more than the arrival of #24, it's a milestone.**

And no one understands that better than you. Sharing in that moment and keeping her smile healthy for years is one of the reasons why you became a dentist. And behind you all the way is the California Dental Association. Giving you peace of mind with TDIC, an insurance company that only protects dentists and is a top member benefit year after year. We do everything we can to help you practice safely, so you can focus on what you truly love — to care for your patients.

**CDA Membership.**  
[cda.org](https://cda.org)



# Dare to Compare on Innovation, Quality, Service and Value

## Legacy™3 Implant

All-in-1 Packaging includes implant, abutment, transfer, cover screw & healing collar  
\$200 vs \$633<sup>1</sup> from Zimmer Dental

✓ **Reality Check**  
**Zimmer Customers**  
Save \$433 with Legacy3



## SwishPlant™ Implant

All-in-1 Packaging includes implant, straight abutment/transfer, cover screw & healing collar  
\$200 vs \$737<sup>2</sup> from Straumann®


✓ **Reality Check**  
**Straumann Customers**  
Save \$537 with SwishPlant



## ReActive™ Implant

All-in-1 Packaging includes implant, abutment, transfer & cover screw  
\$200 vs \$718<sup>3</sup> from Nobel Biocare™

✓ **Reality Check**  
**Nobel Customers**  
Save \$518 with ReActive



## Implant Direct's New Las Vegas Training Center

Implant Direct offers an extensive list of educational opportunities at its Las Vegas Training Center with computers at each desk for Image Guided Surgical Training, models/mannequins for hands-on training and a four chair dental office for live surgical demonstrations.

**24 CE CREDITS**

### Implant Dentistry 101: Three-Day Introductory Course

May 16-18 | June 13-15 | July 18-20

**16 CE CREDITS**

### 3D Implantology: Two-Day Advanced Course

Featuring Anatomage Passage surgical guide starter software  
August 16-17 | October 18-19



## View Dr. Niznick's 2-Hour Lecture at Las Vegas Training Center & Earn 2 CE Credits FREE

Dr. Gerald Niznick discusses how the latest implant design innovations are shaping the future of implantology.

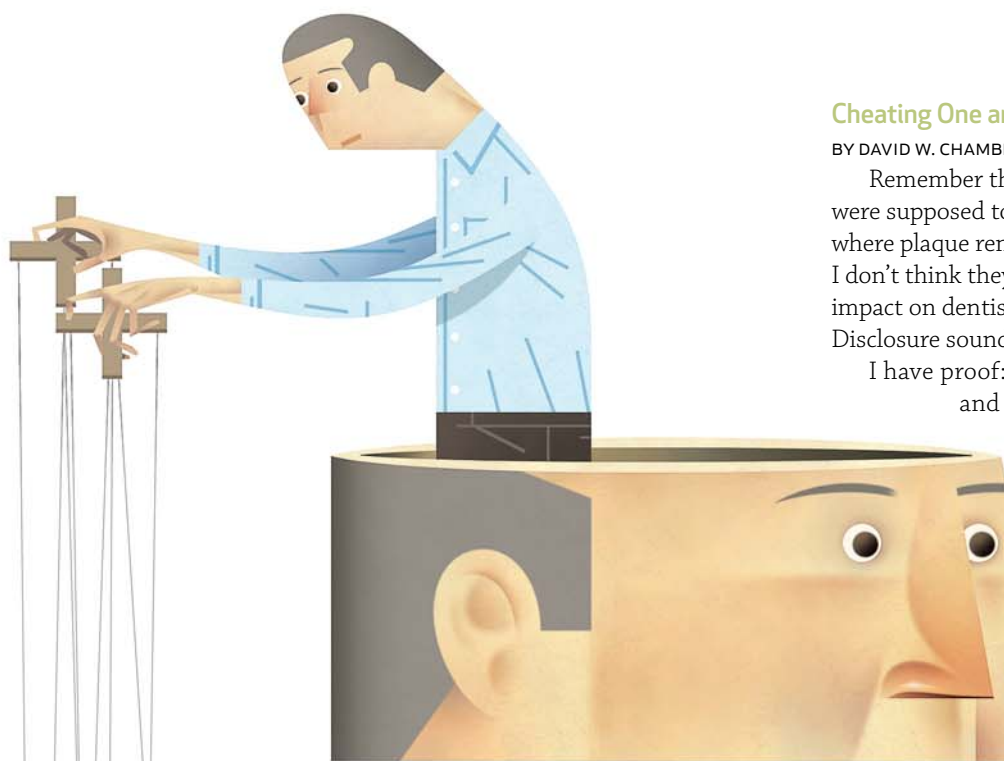


**New**  
Check out our  
easy to use mobile app!

**Introductory Offer: Make the switch & receive three FREE implants.<sup>4</sup>**

**www.implantdirect.com | 888-649-6425**

Price comparisons based upon US list prices as of January 2013. All trademarks are property of their respective companies. Satisfied among Current and Former Users, by Company US Q211 Millenium Research Group A Decision Research, Inc. Company  
<sup>1</sup>US list price for Tapered Screw-Vent with micro grooves, healing collar & straight abutment  
<sup>2</sup>US list price for SLActive Tapered Effect implant, closure screw, healing abutment, solid abutment, transfer and comfort cap.  
<sup>3</sup>US list price for NobelActive with cover screw, impression coping & abutment  
<sup>4</sup>Terms and conditions apply  
Live surgical demonstrations not available at all courses



## Cheating One and All

BY DAVID W. CHAMBERS, PHD

Remember those pink tablets patients were supposed to chew and swish to reveal where plaque remained on their teeth? I don't think they have made the big impact on dentistry some had expected. Disclosure sounds better than it is.

I have proof: Cain, Loewenstein and Moore published a study in the *Journal of Legal Studies* in 2005 in which they evaluated whether or not disclosure tidied up the temptation to take advantage of others. The game works like this: A jar full of change sits across the room,

CONTINUES ON 313

## Test Scores Show Benefit of iPad-equipped Medical School Class

Since 2010, incoming University of California, Irvine medical students have received fully loaded iPads, putting at their fingertips all the information they need to read, study or review, and now, according to a news release from the university, the benefits of the "iMedEd" initiative are showing in test scores.

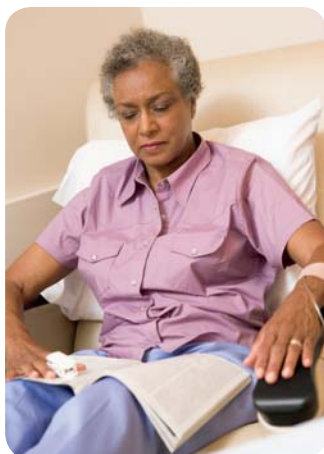UC Irvine has reported that the first class to participate in the program scored an average of 23 percent higher on their national exams than previous UC Irvine medical school classes, despite having similar incoming GPAs and MCAT scores, according to the news release.

Through the iMedEd program, students can access textbooks electronically or carry directly on the iPad. Additionally, the tablets provide podcasts of lectures and with their secure iPads, students can record and display data from digital stethoscopes, bedside diagnostic ultrasound units and a variety of other medical devices, as well as encrypted, patient-protected electronic medical records, the university noted.

For more information, see the news release at [news.uci.edu/press-releases/ucis-imeded-initiative-named-a-2012-13-apple-distinguished-program/](http://news.uci.edu/press-releases/ucis-imeded-initiative-named-a-2012-13-apple-distinguished-program/).







### Smad7 Protein Shows Preventive and Therapeutic Effects on Radiation-induced Mouth Sores

Mouse model studies show that administered genetically or topically, protein Smad7 can protect against or heal oral mucositis sores commonly associated with cancer treatment, according to a University of Colorado Cancer Center study published in the journal *Nature Medicine*.

In some cancer patients treated with radiation, mouth sores become so severe that feeding tubes are required for nutrition and narcotics are necessary to manage pain, a news release from the university reported, adding that 40-70 percent of patients treated with upper-body radiation develop the condition to some degree. Additionally, there is currently no FDA approved treatment.

"We developed a genetically engineered mouse that produces a protein called Smad7 in the surface layers of its mouth. With this protein expressed, mouse models were dramatically more resistant to the development of oral mucositis than

were controls," said CU Cancer Center investigator, Xiao-Jing Wang, PhD, and John S. Gates, in the news release.

Wang and collaborators are pursuing further research with the goal of developing Smad7 as a therapeutic agent for human oral mucositis.

"It's very reasonable to hope that this line of research will result in a drug that patients can self-administer topically to oral mucositis sores, or use to prevent them altogether, thus significantly improving the quality of life for many cancer patients," Wang said in the news release.

"We have identified new molecular mechanisms involved in oral mucositis pathogenesis, and our data suggest an alternative therapeutic strategy to block multiple pathological processes in this condition," authors concluded.

For more information, see the study published online, *Nature Medicine*, March 10, 2013, or visit [coloradocancerblogs.org/promising-new-drug-treats-and-protects-against-radiotherapy-associated-oral-mucositis/](http://coloradocancerblogs.org/promising-new-drug-treats-and-protects-against-radiotherapy-associated-oral-mucositis/).

### Preserved DNA Sheds Light on Evolving Diet

A team of researchers, led by the University of Adelaide's Australian Centre for Ancient DNA (ACAD), extracted and evaluated DNA from the tartar of 34 prehistoric northern European human skeletons and found that ancient genetic records reveal the health consequences of an evolving diet and behavior from the Stone Age to the modern day.

According to a news release from the university, after extracting the ancient DNA, researchers traced changes in the nature of oral bacteria from the last hunter-gatherers, through the first farmers to the Bronze Age and Medieval times. The data from the skeletons indicate that the transition from hunter-gatherer to farming shifted the oral microbial community to a disease-associated configuration, authors wrote.

"The composition of oral bacteria changed markedly with the introduction of farming, and again around 150 years ago. With the introduction of processed sugar and flour in the Industrial Revolution, we can see a dramatically decreased diversity in our oral bacteria, allowing domination by caries-causing strains. The modern mouth basically exists in a permanent disease state," said Alan Cooper, ACAD director and study leader, in the news release.

For more information, see the study in the journal *Nature Genetics* vol. 45(4), pp 450-455.



## Dentin Hypersensitivity in General Dental Practices in Northwest U.S.

A recent study to determine the prevalence of dentin hypersensitivity in general dental practices found that one in eight participants from general practices had dentin hypersensitivity.

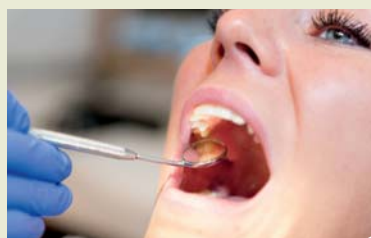Published in the *Journal of the American Dental Association*, the study describes dentin hypersensitivity as a chronic condition causing intermittent, low-level pain. The authors conducted a cross-sectional survey and diagnosed dentin hypersensitivity by means of participant responses to questions regarding pain in their teeth and gingivae, and practitioner-investigators conducted a clinical examination to rule out alternative causes of pain, the study noted.

The prevalence of dentin hypersensitivity was 12.3 percent and patients with hypersensitivity had an average 3.5 hypersensitive teeth. Additionally, the authors found the prevalence of dentin hypersensitivity to be higher among 18- to 44-year-olds than among participants 65 years or older.

"Patients with hypersensitivity were more likely to be younger, to be female and to have a high prevalence of gingival recession and at-home tooth whitening," the study noted.

"Given dentin hypersensitivity's prevalence, clinicians should diagnose it only after investigating all other possible sources of pain," authors concluded.

For more information, see the study, "The prevalence of dentin hypersensitivity in general dental practices in the northwest United States," in the *Journal of the American Dental Association*, March 1, 2013 vol. 144, no. 3, pp 288-296.



### CHEATING, CONTINUED FROM 311

and the job of the "estimator" is to guess the amount. It does not matter whether the guess is high or low, but the closer one gets to the exact amount the greater the reward.

"Estimators" are paired with "advisors" who have a closer look at the jar and have secret information that the amount of money at stake is between \$10 and \$30. They coach the "estimators" and both are paid based on the accuracy of the estimator's guess. Average guess with the help of unbiased advice = \$16.50.

When the rules were changed so that advisors receive a bonus whenever the estimators guess too high, the average guess gets a 20 percent bump to \$20. This is what was happening with the subprime mortgage market.

But wait. There is always the disclosing tablet. Surely that neutralizes the effect of using perceived superior knowledge for personal advantage. We can make things

fair by requiring that physicians reveal when they are owners of clinics that do the diagnostic imaging they order for their patients or that dentists disclose they make more money doing posterior composites than amalgams.

Cain, Loewenstein and Moore checked this out by requiring that "advisors" in their study disclose they were receiving a bonus tied to evaluator overestimates. Now the advisors averaged a further bump in suggested guess to more than \$24. No need to be bashful once the cards are on the table. And now that the evaluators understood the game, they did make an adjustment. But it was anything but adequate: they discounted the \$8 inflated estimates by \$2.

Journals and CE programs have caught on to the flimsy disclosure phenomenon. They routinely pass on the responsibility for any problems that might be created to experts and those he or she advises. Thus, they add their endorsement to the sham

that disclosure protects those who do not know from those who say they do. When I present at the big meetings on the topic of ethics, I am required to insert a slide at the beginning that absolves the sponsor. Here it is. "There are no commercial interests whatsoever associated with this presentation. I tried very hard, but could find no commercial organization interested in funding a presentation on ethics."

The nub:

① No one is exempt from the temptation to use superior knowledge for private gain.


② We are all susceptible to influence by experts.

③ Disclosure of conflicts of interest is an inadequate protection against abuses of superior knowledge.

*David W. Chambers, PhD, is professor of dental education, Arthur A. Dugoni School of Dentistry, San Francisco, and editor of the Journal of the American College of Dentists.*



You're a genius at taking impressions.



## Now, let's work on raising that Hazard Communications I.Q.

Protecting your employees and dental office from hazards is critical, although keeping up on changes to OSHA regulations isn't always easy — until now. CDA's Compass has PowerPoint presentations and informative articles to help you implement the newest requirements with minimal effort. It'll have your office running safer and smarter than ever. Simply log on to [cdacompass.com](http://cdacompass.com) today and search Hazard Communications Plan.

[cdacompass.com](http://cdacompass.com) | where smart dentists get smarter.<sup>SM</sup>





**“Now we show that  
fluoridated water  
reduces tooth decay in  
adults, even if they start  
drinking it after  
childhood.”**

GARY SLADE

### Fluoridated Water Reduces Adult Tooth Decay

In the first population-level study of its kind, a new study has found the strongest evidence yet that fluoride in drinking water provides dental health benefits to adults, even those adults who did not receive fluoridated drinking water as children.

Conducted by researchers at the University of North Carolina at Chapel Hill and the University of Adelaide, Australia, the study shows that fluoridated drinking water prevents tooth decay for all adults regardless of age and whether or not they consumed fluoridated water during childhood, according to a news release from UNC.

“It was once thought that fluoridated drinking water only benefited children who consumed it from birth,” said lead author Gary Slade, director of the oral epidemiology PhD program at UNC, in the news release. “Now we show that

fluoridated water reduces tooth decay in adults, even if they start drinking it after childhood. In public health terms, it means that more people benefit from water fluoridation than previously thought.”

The study, published online in the *Journal of Dental Research*, used survey data from 3,779 adults aged 15 and older selected at random from the Australian population between 2004 and 2006. Survey examiners measured levels of decay and study participants reported where they lived since 1964.

The authors found that adults who spent more than 75 percent of their lifetime living in fluoridated communities had significantly less tooth decay (up to 30 percent less) when compared to adults who had lived less than 25 percent of their lifetime in such communities.

For more information, see the news release at [uncnews.unc.edu/content/view/5916/71/](http://uncnews.unc.edu/content/view/5916/71/).

### U.K. TV Exposes Children to Millions of Tobacco Messages Weekly

U.K. children see millions of tobacco images and messages every week, according to a new study in *Tobacco Control* that measured the extent to which tobacco content occurs in prime-time U.K. television.

With the occurrence of tobacco categorized as actual tobacco use, implied tobacco use, tobacco paraphernalia, other references to tobacco, tobacco brand appearances or any of these, researchers evaluated all prime-time broadcasting on the five most popularly viewed U.K. television stations during three separate weeks in 2010.

The estimated number of instances of tobacco images and messages, actual tobacco use and tobacco brand appearances were 59 million, 16 million and 3 million, respectively, every week as roughly one-third (34 percent) of the 613 programs broadcast contained some tobacco content. This occurred at least once in more than half of all reality TV shows (67 percent), feature films (64 percent) and comedy (52 percent) programs, and in nearly half of soap operas (49 percent) and dramas (48 percent).

More than two-thirds of tobacco content (69 percent) featured in the 75 percent of hours of programs in the sample broadcast before the 9 p.m. “watershed,” which marks the line between material more suitable for adults than for children.

More stringent controls on tobacco in prime-time television have the potential to help reduce the uptake of youth smoking in the U.K., authors concluded.

For more information, see the study published online March 11, 2013, at [tobaccocontrol.bmj.com/content/early/2013/02/21/tobaccocontrol-2012-050650](http://tobaccocontrol.bmj.com/content/early/2013/02/21/tobaccocontrol-2012-050650).



## Genetic Code Identified for Periodontitis Bacteria

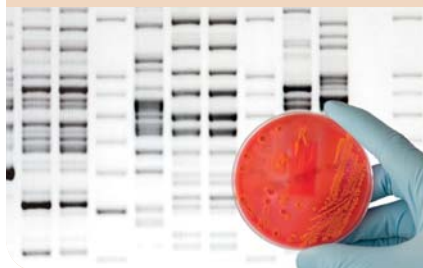Scientists from Oak Ridge National Laboratory recently identified the genetic code of bacteria linked to periodontitis, according to a news release from the lab. Published in the *Proceedings of the National Academy of Sciences*, the study profiles the SR1 bacteria, a group of microbes present in many environments, ranging from the mouth to deep within the Earth, that have never been cultivated in the laboratory. Human oral SR1 bacteria are elevated in periodontitis.

Scientists also found that the SR1 bacteria employ a unique genetic code in which the codon UGA — a sequence of nucleotides guiding protein synthesis — appears not to serve its normal role as a stop code. In fact, the scientists reported that UGA serves to introduce a glycine amino acid instead.

“This is like discovering that in a language you know well there is a dialect in which the word stop means go,” co-author Mircea Podar said in the news release.

The researchers believe the altered genetic code limits the exchange of genes between SR1 and other bacteria because they use a different genetic alphabet. The authors believe this work will help provide a path toward a better understanding of microbiological factors of periodontitis as well as to the establishment of a framework to help scientists interpret genomic data from this bacterium and others that have the same altered genetic code.

For more information, see the news release at [ornl.gov/info/press\\_releases/get\\_press\\_release.cfm?ReleaseNumber=mr20130318-00](http://ornl.gov/info/press_releases/get_press_release.cfm?ReleaseNumber=mr20130318-00) or read the study published ahead of print in *Proceedings of the National Academy of Sciences*, March 18, 2013.



## IOM Workshop Explores Oral Health Literacy

Limited oral health literacy is associated with inaccurate knowledge about preventive measures such as water fluoridation, dental care visits and oral health-related quality of life, according to a report that summarized an Institute of Medicine oral health literacy workshop, noting that the report contains the opinions of presenters but does not reflect the conclusions of the IOM. “For example, nationally only ‘44 percent of adults with less than basic health literacy skills had a dental visit in the preceding year compared with 77 percent of those with proficient health literacy skills (Rozier, 2012).’”

“The public and health care providers are largely unaware of the basic risk factors and preventive regimens for many oral diseases,” the report said. “For example, the fact that dental caries is both infectious and preventable is not generally known by the public and most health care providers. The relationship between good oral health

and well-being is also not well understood.”

In a keynote address on the importance of oral health literacy, Rep. Elijah Cummings (D-Md.) said that in the context of oral health literacy, there is much work to be done to let people know what they need to know. Families need to be educated about the importance of oral health and have access to dental services.

The definition of oral health literacy adopted as ADA policy in 2006 and cited in the IOM report is “the degree to which individuals have the capacity to obtain, process and understand basic health information and services needed to make appropriate oral health decisions.” Association policies acknowledge that limited health literacy is a possible barrier to oral disease management and that effective communication skills are essential to the practice of dentistry.

For more information, see the Feb. 21, 2013, workshop summary at [iom.edu/Reports/2013/Oral-Health-Literacy.aspx](http://iom.edu/Reports/2013/Oral-Health-Literacy.aspx) or visit [ada.org/news/8294.aspx](http://ada.org/news/8294.aspx).



**“With this new identification of osteopontin as a substrate protein for PHEX, we can begin to develop an enzyme-replacement therapy to treat XLH patients who have nonfunctional PHEX...”**

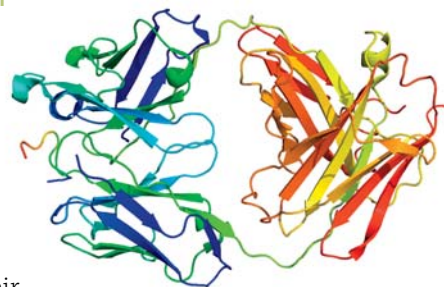
NILANA M. T. BARROS

### Study: Major Tooth Substrate Protein Plays Role in XLH

Researchers at McGill University and the Federal University of Sao Paulo recently identified osteopontin, a major bone and tooth substrate protein, as playing a role in X-linked hypophosphatemia (XLH), and according to a McGill University news release, their discovery could pave the way to effectively treating the rare disease, in which tooth abscesses can develop because infections penetrate soft teeth that are not properly calcified.

In the recent study, published in the *Journal of Bone and Mineral Research*, the team of scientists built upon earlier research that showed mutations in the single gene PHEX to be responsible for causing XLH.

“XLH is caused in part by renal phosphate wasting, which is the urinary loss from the body of phosphate, an important building block of bones and teeth, along with calcium,” said Marc McKee, a professor in the Faculty of Dentistry and the department of anatomy and cell biology at McGill University, in the news release. “In pursuing other factors



that might contribute to XLH, we used a variety of research methods to show that PHEX enzymatic activity leads to an essentially complete degradation of osteopontin in bones.”

“With this new identification of osteopontin as a substrate protein for PHEX, we can begin to develop an enzyme-replacement therapy to treat XLH patients who have nonfunctional PHEX, much as has been done using a different enzyme to treat another rare bone disease called hypophosphatasia,” said Nilana M. T. Barros, professor at the Federal University of Sao Paulo, in the news release.

For more information, see the study in the *Journal of Bone and Mineral Research*, Vol. 28:3, pp 688-699.

#### UPCOMING MEETINGS

##### 2013

July 18–20	ADA 27th New Dentist Conference, Denver, Colo., 312-440-3524 or <a href="mailto:newdentist@ada.org">newdentist@ada.org</a>
Aug. 15–17	CDA Presents <i>The Art and Science of Dentistry</i> , San Francisco, 800-CDA-SMILE (232-7645) or <a href="http://cdapresents.com">cdapresents.com</a>
Oct. 31–Nov. 5	154th ADA Annual Session, New Orleans, <a href="http://ada.org/session">ada.org/session</a>
Nov. 3–9	U.S. Dental Tennis Association, Big Island, Hawaii, 800-445-2524 or <a href="http://dentaltennis.org">dentaltennis.org</a>
Nov. 10–13	National Primary Oral Health Conference, Denver, Colo., <a href="http://nnoha.org/conference/npohc.html">nnoha.org/conference/npohc.html</a>

To have an event included on this list of nonprofit association continuing education meetings, please email Courtney Grant at [courtney.grant@cda.org](mailto:courtney.grant@cda.org).







## Looking for your C.E. certificate?

- Approximately three weeks after *CDA Presents* in Anaheim, licensed attendees will receive an email containing a link to their printable C.E. certificate.
- C.E. certificates can also be accessed at **[cdapresents.com](http://cdapresents.com)**.
- Certificates can also be mailed by request — simply call 800.232.7645 approximately three weeks after the show. Have all three-digit course codes available, as they may be needed for verification.



## The home for dental innovation.





If you're looking for the latest technology, products and services in dentistry, look no further than CDA Presents. The Anaheim tradeshow featured more than a hundred new products. If you're looking for the next big idea in dentistry, it could be one of these Cool Products.

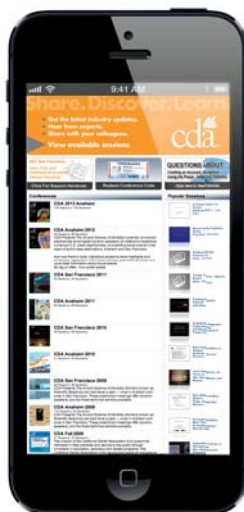	Company/Product Website	Product Description
	<b>GumChucks at OralWise Inc.</b>  <b>GumChucks®</b>  <a href="http://gumchucks.com">gumchucks.com</a>	GumChucks® is an innovative new flossing system. Resembling miniature nunchucks, they feature disposable tips equipped with a ¾-inch piece of floss. GumChucks can be used in the recommended "C" shape, something flossers can't do, providing superior control and leverage while fingers stay out of the mouth.
	<b>ProSites</b>  <b>ProSites Mobile Website Solution</b>  <a href="http://prosites.com">prosites.com</a>	Reach on-the-go patients with a new ProSites mobile website. With user-friendly navigation and prominent click-to-call and click-to-map icons, patients can find and contact your practice instantly. Plus, add unlimited pages, showcase services and play videos right from the mobile site. The mobile revolution is here—is your practice ready?
	<b>Air Techniques</b>  <b>Monarch™</b>  <a href="http://airtechniques.com">airtechniques.com</a>	<p>Air Techniques proudly introduces Monarch™, an innovative and highly effective line of infection control products designed specifically for the dental practice.</p> <p>The Monarch™ line of infection control products for surfaces, instruments, skin, hands and equipment is designed to exceed practitioner's expectations in terms of staff and patient safety, effectiveness and efficiency. This philosophy is truly emphasized in Monarch's™ tagline: Stronger, Safer, Smarter.™</p> <ul style="list-style-type: none"><li>• Stronger: Monarch™ products are extremely effective and feature the fastest clinically relevant kill times.</li><li>• Safer: Formulations are nontoxic and gentle on skin, eyes and mucous membranes. And they are free of carcinogens and hormone disrupters.</li><li>• Smarter: One-step disinfection saves time and innovative packaging designs reduce plastic container waste. Anticorrosive formulas protect lines, operatory and utility equipment.</li></ul>
	<b>Philips Sonicare</b>  <b>Philips Sonicare FlexCare Platinum</b>  <a href="http://philipsoralhealthcare.com">philipsoralhealthcare.com</a>	<p>Proven to remove up to six times more plaque between teeth,* Philips Sonicare's new InterCare brush head has unique bristles for advanced interproximal plaque removal and superior gum care. An intuitive pressure sensor and nine brushing experiences offer personalized care and interactive guidance to help patients brush correctly.</p> <p>*Than a manual toothbrush.</p>

# Cool Products

## Company/Product Website

## Product Description

	<p><b>Colgate</b></p> <p><b>PreviDent® 5000 Booster Plus</b></p> <p><b>colgateprofessional.com</b></p>	<p>New Colgate PreviDent® 5000 Booster Plus Delivers Unsurpassed Remineralization<sup>1</sup></p> <p>New Colgate® PreviDent® 5000 Booster Plus contains 1.1% sodium fluoride (5,000 ppm), FluoridGard™ technology and Tricalcium phosphate. The new formula is shown to provide:</p> <ul style="list-style-type: none"> <li>• Better remineralization after 10 days<sup>§1</sup></li> <li>• Unsurpassed remineralization after 20 days<sup>†1</sup></li> </ul> <p>Full prescribing information at <a href="http://colgateprofessional.com">colgateprofessional.com</a>.</p> <p>References:  <sup>1</sup> Data on file; Colgate-Palmolive, 2012. In vitro pH cycling model after 10 and 20 days.  <sup>†</sup> Optimized fluoride delivery system.  <sup>§</sup> Statistically better when compared to ClinPro™ 5000, MI Paste Plus™ topical creme, and PreviDent® 5000 Booster.  <sup>‡</sup> Comparison vs PreviDent® 5000 Booster, MI Paste Plus™ topical creme, and PreviDent® 5000 Booster.</p>
	<p><b>Carestream Dental</b></p> <p><b>CS Solutions</b></p> <p><b>carestreamdental.com/solutions</b></p>	<p>CS Solutions creates a new reality for restorative dentistry: one-visit, chairside restorations.</p> <p>Consisting of an intraoral scanner, restoration design software, a milling machine and a Web portal for sharing and managing restoration cases between dentists and laboratories, practices can choose between a comprehensive approach or stand-alone solutions.</p>
	<p><b>Orasoptic</b></p> <p><b>XV1</b></p> <p><b>orasoptic.com/xv1</b></p>	<p>XV1 is the world's first wireless loupe and headlight in one. This innovation seamlessly combines Orasoptic's award-winning loupes with its award-winning headlight — featuring a lightweight and completely cableless design. By removing the heavy and bulky backpacks of past headlamps, XV1 was ergonomically designed for comfort, function and style.</p> <ul style="list-style-type: none"> <li>• The world's first and only wireless loupe plus headlight in one.</li> <li>• All electronics are completely contained within the custom frame.</li> <li>• No more cables to get tangled on chairs, doorknobs or drawers.</li> </ul>
	<p><b>Sunstar</b></p> <p><b>GUM® EasyThread™ Floss</b></p> <p><b>gumbrand.com</b></p>	<p>Frustrated with your current threader floss? Now there's GUM® EasyThread™ Floss — created for easier plaque removal in hard-to-reach places. Double-ended threader sections are designed with the ideal stiffness to easily navigate around braces, bridges and implants without irritating the gums. This product features “puffy” floss with “plaque-grabbing” fibers for increased surface contact and a more thorough clean. Innovative, hygienic packaging reduces tangles and waste. Available in patient sample packs as well as a rewindable dispenser for in-office use.</p> <ul style="list-style-type: none"> <li>• Innovative, hygienic dispenser eliminates tangles and waste.</li> <li>• Dual-ended threader sections that maximize cleaning with one strand.</li> <li>• Available in 50-use office dispensers and five-strand envelopes for patient in-home trial.</li> </ul>



## Save \$100 on course audio recordings!

For \$149, you'll get your choice of Digitell's online library or CD-ROM of the *CDA Presents* courses from Anaheim.

### Online Library

- All courses include downloadable audio MP3 format.
- Presentations are available in PDF format.
- Transfer audio to your MP3 player, iPad or smartphone.
- Stream the audio via an online media player.
- Search the courses by speaker name, title and PowerPoint for easy reference and retrieval.
- A subscription includes three free co-users for easy sharing with staff, colleagues and friends.
- Access for additional users can be purchased at a discounted price.

Take advantage of this special at [prolibraries.com/cda](http://prolibraries.com/cda)



# San Francisco 2013

August 15–17 at the Moscone South Convention Center in San Francisco  
Register at [cdapresents.com](http://cdapresents.com)

Here is some information you will be asked for when registering:

- Name
- Address
- Phone number
- Registration type
- License number (if applicable)
- Emergency contact person
- Ticketed courses/events to purchase
- Password
- Email address (used for username and instant confirmation)

For your convenience, you can choose to pick up your materials on site at eBadge Exchange. This flexible option gives the ability to make changes to your registration from your personal online dashboard at any time until July 12. Otherwise, register by June 13 to have materials mailed to you prior to the meeting. Remember, CDA dues must be current for 2013 to complete your registration as a member.

**Please note: Registrations are not accepted over the phone.**

## On-site registration/bag and lanyard pickup

Moscone South Convention Center

Thursday 6:30 a.m.–5:30 p.m.

Friday 6:30 a.m.–5:30 p.m.

Saturday 6:30 a.m.–4:30 p.m.

## What is the cost for CDA dentists?

Zero. As a benefit of membership, the \$890 registration fee is waived for CDA dentists.

## Staff and guests

Dentists may register staff and guests, but not other dentists. All dentists, including nonmembers, must register as dentists.

If you register an employee who is no longer attending, you can exchange his/her badge on site for a new one at no charge.

## One-time \$75 California nonmember rate\*

Nonmembers can save \$815 with the \$75 one-time meeting registration fee.\* If you were a CDA member in 2011 or 2012, you are not eligible for the one-time nonmember \$75 registration fee for 2013. Materials cannot be mailed in advance, but can be picked up at the designated area in registration.

*\*Any nonmember who has taken advantage of this offer in the past is not eligible. The rate is for one-time use only.*

## Registration deadlines

**June 13, 2013:** To have materials mailed prior to the show. Mailed registration forms will not be accepted if postmarked after June 13. Forms received after this date will be returned.

**June 14 – Aug. 17, 2013:** Online registration remains open and materials will be available at the eBadge Exchange booth at the Moscone South Convention Center.

CDA mails registration materials at least two weeks prior to the meeting. If you do not receive materials within this time frame, call CDA at 800.232.7645.

Cancellations and/or course changes can be made from your online registration dashboard or requested in writing until July 12, 2013. After this date, refunds will not be given. If badges and/or tickets have already been mailed, the appropriate materials must be returned with your refund request and postmarked by July 12 in order to be processed.

Mail refund requests to:

CDA Presents

1201 K Street, 16th Floor

Sacramento, CA 95814





# Exhibit Hall

## Explore 80,000 square feet of dental innovation

With numerous new product launches and nearly 400 exhibiting companies filling the vibrant exhibit hall, *CDA Presents* is one of the most anticipated dental tradeshow in the U.S. It's the place to discover the latest innovations in dentistry.

### Grand Opening

Thursday, 9:30 a.m.

### Exhibit Hall Hours


Thursday, 9:30 a.m.–5:30 p.m.

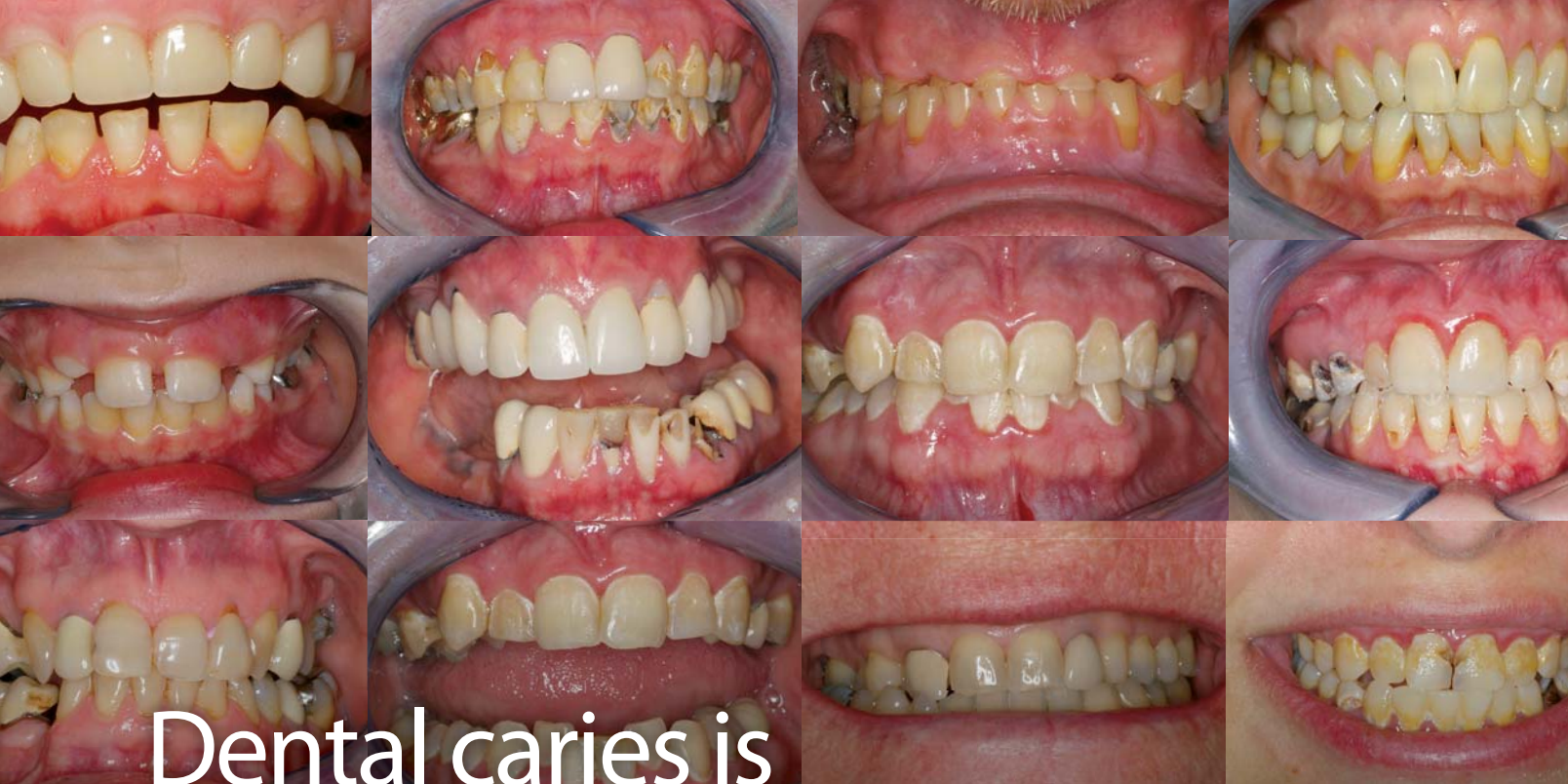Friday, 9:30 a.m.–5:30 p.m.

Saturday, 9:30 a.m.–4:30 p.m.

### Family Hours

Daily: 9:30 a.m.–noon





# Dental caries is **out of control.**



**COMPLETE  
DIAGNOSTIC AND  
TREATMENT SYSTEM**

**We are not okay with that.**

**JOIN CARIFREE  
IN DOING SOMETHING ABOUT IT!**

Schedule a free CariFree  
consultation and we will send you  
a complimentary copy of Balance.

Visit **start.carifree.com** or  
call 866.928.4445

*Limit one free book per person, US only*

**CariFree®** 





A series of circular images showing various oral lesions, including leukoplakia, erythroplakia, and possibly early-stage oral cancer, arranged in a vertical column on the left side of the page.

# Oral Medicine Update: Oral Cancer — Screening, Lesions and Related Infections

JOEL M. LAUDENBACH, DMD

## GUEST EDITOR

**Joel M. Laudенbach, DMD**, a diplomate of the American Board of Oral Medicine, practices oral medicine in Beverly Hills and Tarzana, Calif. He is an assistant professor of oral medicine and geriatric dentistry at Western University of Health Sciences and is on the medical staff at Cedars-Sinai Medical Center.  
*Conflict of Interest Disclosure: None reported.*

Conventional oral cancer assessment knowledge and skills are crucial for all oral health care providers (OHCPs). Examination and assessment skills and knowledge base, combined with clinical experience, lead to an accurate differential diagnosis and the ultimate oral diagnosis. OHCPs are faced with detecting, screening and diagnosing oral, orofacial and head/neck pathologic findings on a daily basis. Patients depend on the ability of all OHCPs to diagnose lesions/masses, perform appropriate tests and institute management when indicated. Patients also rely upon OHCPs to appropriately refer to other professionals in situations when the diagnosis and/or management of the oral/orofacial pathologic finding is beyond the OHCP's expertise. The differential diagnosis of persistent oral lesions/masses

often includes potentially malignant, premalignant and/or malignant disease(s). When any of these diseases are added to a differential diagnosis, the OHCP is faced with further characterizing the lesion(s), establishing the diagnosis in an appropriate time frame and informing/counseling the patient every step of the way.

Oral medicine is the discipline of dentistry concerned with the oral health care of medically compromised patients and with the diagnosis and nonsurgical management of medically related disorders or conditions affecting the oral and maxillofacial region. These authors present clinically relevant oral medicine topics related to oral cancer in such a way that the clinician may easily and quickly review the specific topic and then implement the updated information clinically.

This issue focuses on three important oral cancer topics.

Drs. Kerr and Shah review extraoral and intraoral examination techniques used by OHCPs to detect oral, head and neck lesions/masses in “Standard Examination and Adjunctive Techniques for Detection of Oral Premalignant and Malignant Lesions.” Currently available adjunctive techniques are reviewed concisely so OHCPs can make an informed decision about appropriate uses of these adjunctive tests. OHCPs who are using or considering using of these tests should be aware of all known potential limitations and benefits of the tests, while making sure

that a tissue diagnosis is established in an appropriate, timely fashion.

Assessment and then diagnosis of oral mucosal lesions with the potential for malignant transformation is challenging. Communication with our patients about these diseases leads to numerous questions and concerns. OHCPs need to be ready to answer and discuss these openly. Dr. Brennan et al. provide an important update on oral lichen planus and oral epithelial dysplasia. Many of the questions that our patients pose in clinical practice are answered in their article “Diagnosis and Management of Mucosal Lesions With the Potential for

Malignant Transformation.” Clinicians can use this review to implement diagnostic and management strategies, including informing patients about these lesions and any associated risks, prescribing medical management when indicated and assigning appropriate surveillance/follow-up care.

When “wart-like” lesions are detected intraorally, OHCPs are faced with explaining and answering questions about human papillomavirus (HPV), associated risk factors and possible links to oral cancer. Most dental patients are well aware of the role HPV plays in the development of cervical cancer, and patients with young or adolescent children have no doubt come across the topic of HPV vaccinations. With an educated and aware patient population, OHCPs must be up-to-date on oral HPV and be able to communicate what is known and what is not known today. OHCPs are faced with the decision of whether to use oral HPV test kits, and the task of interpreting the test results, management and appropriate referrals. In “Human Papillomavirus: The Fundamentals of HPV for Oral Health Care Providers,” Dr. Ciarrocca et al. have presented a contemporary review of HPV, which helps the OHCP to be well informed and able to communicate the various aspects of oral HPV.

These issues of the *Journal of the California Dental Association* represent a clinically relevant update of important oral medicine topics that OHCPs face daily. The information presented can be used as a resource for clinical practice. Once again, I am especially honored to have all the contributing authors participate in this project and truly appreciate their efforts. I hope you find this issue educational and useful in your oral health care practice. ■■■■

100% silk neckties.  
100% cotton onesies.  
100% CDA. [cda.org/store](http://cda.org/store)



The CDA Store is now online. Be it insulated tumblers, colorful tote bags, “smartdentist” T-shirts, or digital screen cleaners, go to [cda.org/store](http://cda.org/store) and take home a stylish piece of CDA today.





# Standard Examination and Adjunctive Techniques for Detection of Oral Premalignant and Malignant Lesions

A. ROSS KERR, DDS, MSD, AND SONAL S. SHAH, DDS

**ABSTRACT** This article outlines how to perform a standard comprehensive extraoral and intraoral examination and the existing commercially available adjunctive techniques for the early detection of oral cancer and premalignant lesions. Visualization-based techniques (e.g., autofluorescence and chemiluminescence), toluidine blue vital staining, cytopathologic tests and high-risk human papillomavirus testing are discussed in detail, including the indications and protocols for use, their advantages and disadvantages and clinical cases.

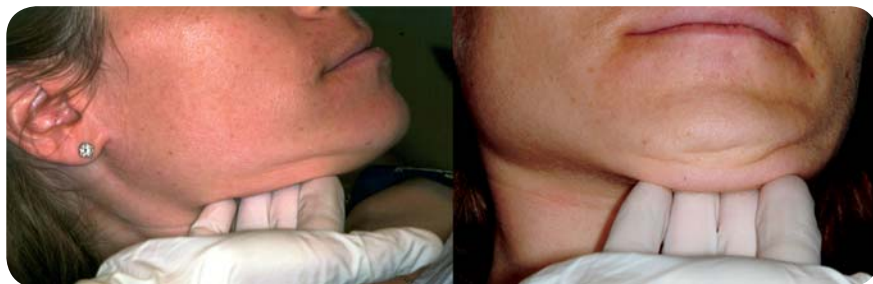## AUTHORS

**A. Ross Kerr, DDS, MSD,** is a clinical associate professor in the Department of Oral and Maxillofacial Pathology, Radiology and Medicine at New York University College of Dentistry where he is the director of the Oral Mucosal Disease Service. He received his DDS degree from McGill University in Montreal, and his MSD and certificate in oral medicine at the University of Washington. He is a diplomate of the American Board of Oral Medicine.  
*Conflict of Interest*  
*Disclosure: None reported.*

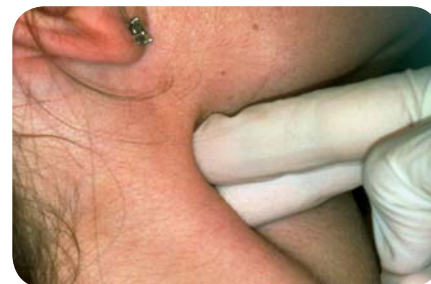**Sonal S. Shah, DDS,** is a clinical assistant professor in the Department of Oral and Maxillofacial Pathology, Radiology and Medicine at New York University College of Dentistry. He received his DDS degree from the University of Texas Health Science Center at Houston Dental Branch, and completed a general practice residency at Wyckoff Heights Medical Center and a residency in oral and maxillofacial pathology at New York Hospital Queens.  
*Conflict of Interest*  
*Disclosure: None reported.*

The American Cancer Society estimates there will be 41,380 new cases of oral cavity and pharyngeal cancer (OPC) diagnosed in the United States in 2013,<sup>1</sup> of which 3,665 will be in Californians<sup>2</sup> and 7,890 Americans will likely die from this disease.<sup>1</sup> Data from U.S. cancer registries through the National Cancer Institute's Surveillance, Epidemiology and End Results program (SEER) up to 2009 show a modest increasing trend in overall incidence and a decreasing trend in mortality rates for OPC.<sup>3</sup> Despite a significant increase from 52.9 percent for the first reporting period (1975-77) to 61.5 percent for the most recent reporting period (2002-2008), the overall relative five-year survival rate remains low, although it

should be noted that rates of > 80 percent are reported if the disease is detected early when localized to the primary site (stage I and II disease). Men are more than twice as likely as women to develop OPC, and African American men suffer the greatest incidence and mortality rates. More than 90 percent of oral and pharyngeal cancers are squamous cell carcinomas (SCCa). Alcohol, tobacco, areca nut use and poor diet have long been established as independent risk factors.<sup>4</sup> Oncogenic strains of human papillomavirus (HPV) 16 and 18, transmitted through sexual contact, can cause oral cancer, principally squamous cell carcinomas of the oropharynx (tonsils and base of tongue).<sup>5</sup> Although recent data show that up to 6 percent of oral cavity carcinomas are



**FIGURE 1.** Extraoral examination of the submandibular and submental lymph nodes.



**FIGURE 2.** Extraoral examination of the anterior neck triangle/lateral cervical lymph nodes. Note the fingers moving deep to the sternocleidomastoid muscle.

caused by HPV,<sup>6</sup> the incidence rates for HPV-related oropharyngeal cancers are fast rising and predicted to overtake those of oral cavity cancers.<sup>7</sup> Precancerous oral lesions (i.e., lesions that demonstrate epithelial dysplasia and therefore may have malignant potential) are far more prevalent than oral cancer in the general population (approximately 1-5 percent), although the overall risk for malignant transformation is low (< 2 percent per annum).<sup>8</sup>

The dental profession can play a pivotal role in efforts to reverse these statistics through early detection of oral cancer and precancerous changes, and by promoting health through risk factor modification and a healthy lifestyle (i.e., tobacco cessation, limiting alcohol intake, consuming a healthy diet and educating about modes of HPV transmission). An expert group convened by the American Dental Association suggested that “clinicians remain alert for signs of potentially malignant lesions or early-stage cancers while performing routine visual and tactile examinations in all patients,”<sup>9</sup> and the California Dental Association recommends a standard visual and tactile extraoral and intraoral examination for oral cancer by incorporating it opportunistically into routine dental examinations.<sup>10</sup> Over the last several decades, a number of adjunctive techniques have been promoted in the marketplace to facilitate such oral cancer examinations by helping to detect the presence of

abnormal oral mucosal changes, to assess their significance and to accelerate the pathway toward early diagnosis. Such techniques include visualization-based adjuncts, vital staining with toluidine blue, cytopathological-based adjuncts and salivary-based techniques. It is important that clinicians who have considered employing these techniques in their offices are aware of the evidence for their utility and effectiveness. This article focuses on the role of oral health care providers in general practice and provides an overview of the oral cancer examination and an update on these adjunctive techniques.

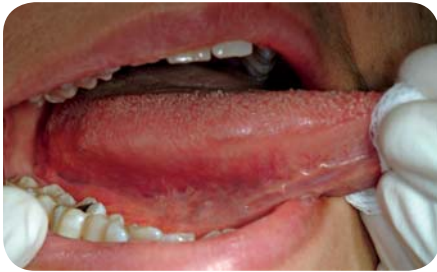### Definition of Adjunctive Techniques for Oral Cancer and Precancerous Lesions

The term “adjunctive technique” may be applied to any technology or device that can help detect oral cancer or precancerous lesions, aid in the characterization of lesions detected during a routine examination and/or facilitate the selection of appropriate sites for further diagnostic evaluation (i.e., biopsy). Its application should accelerate the pathway to a definitive diagnosis, improve diagnostic accuracy and reduce false negative rates due to sampling error. A “screening adjunctive technique” would be applied to a general population and be part of a routine examination, whereas a “diagnostic adjunctive technique” would be used only following the detection of an oral abnormality to facilitate the

diagnostic process. It is imperative for clinicians to understand that the adjunctive techniques described in this article do not replace the need for a careful visual and tactile examination, and that the gold standard for the definitive diagnosis of oral cancer and precancerous lesions remains a tissue biopsy followed by submission for histopathologic evaluation.

### Standard Oral Cancer Examination

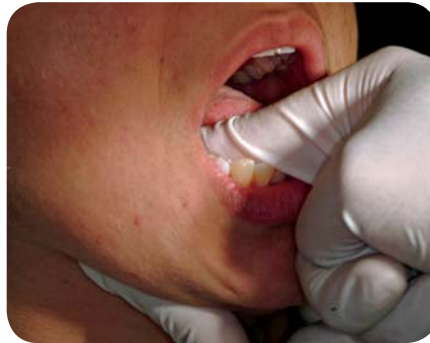A careful examination should be preceded by a routine patient history. Posing questions related to common persistent symptoms associated with oral cancer is helpful, such as pain, sores, changes in swallowing or speech and lumps in the neck. In addition, take a medical history and ask if there is a history of cancer or whether the patient is immunocompromised. Finally, take a social history assessing risk factors such as tobacco and alcohol use, a dental history and a nutritional history assessing protective factors (or lack thereof), such as a high intake of fresh fruits and vegetables.<sup>11</sup> The examination is divided into two steps. The first step is the extraoral examination, important because OPCs metastasize along the lymphatics and lead to lymph node enlargement.<sup>12</sup> Indeed, any unilateral and persistent enlargement of the neck in an adult must be considered malignant until proven otherwise. The extraoral examination begins with inspection of the head, face



**FIGURE 3.** Intraoral examination of the lateral tongue using gauze to inspect the entire surface.

and neck for any obvious asymmetry, growths, color changes or skin abnormalities. Preauricular assessment should include a focus on inspection and palpation for salivary gland, lymph node and temporomandibular joint-related pathology. Patients with suspicious skin abnormalities should be referred to a dermatologist. Inspection and palpation of midline neck structures, including the thyroid gland, while not associated with oral cancer, may reveal glandular enlargement, asymmetry or nodules within the gland. Clinicians can examine the bilobed thyroid by first locating its isthmus just inferior to the cricoid cartilage (found below the thyroid cartilage, itself identified by its prominence, the Adam's apple), and then palpating superiorly and laterally. Patients with abnormal thyroid findings should be sent to a head and neck surgeon or endocrinologist.

Lymphadenopathy due to an inflammatory etiology is associated with soft, tender and freely moveable nodes. Enlarged nodes that are firm, nontender or fixed may indicate the presence of metastasis. The head and neck can be divided into levels from superior to inferior and a collar of superficial lymph nodes of the head drain into deeper neck lymph nodes. Level I comprises the submandibular and submental triangles and lymph nodes tend to be superficial and readily palpable by asking patients to drop their chin and dragging the tissues



**FIGURE 4.** Bimanual palpation of the floor of mouth. The left index finger extraorally approximates the right finger intraorally moving from posterior to anterior.

across the inferior border of the mandible laterally and anteriorly (**FIGURE 1**). Levels II-VI nodes are found in the neck. The majority of OPCs will metastasize to levels I, II and III.<sup>13</sup> Levels II and III are found in the anterior triangle of the neck — and can be assessed by asking the patient to turn his/her head away from the side being examined and palpating anterior and deep to the anterior border of the sternocleidomastoid muscles from superior to inferior (**FIGURE 2**). The posterior triangle (level V), posterior to the sternocleidomastoid muscle, is not a common site for metastasis for oral cavity cancer, but may receive drainage from the oropharynx. It is important to point out that while nodal metastases are usually associated with a visible primary oral or pharyngeal cancer, it is possible that clinicians may not detect the primary, either because it involves pharyngeal sites unevaluable by oral health care providers (e.g., nasopharynx), or because the primary site is small or even absent (known as an “unknown primary”). In some HPV-associated oropharyngeal cancers, metastasis occurs early and an enlarged node is the earliest and only sign. All patients with persistent lymphadenopathy with no apparent explanation should be referred to a specialist (i.e., oral medicine, oral and maxillofacial pathology, oral and maxillofacial surgery or otolaryngology).

The second step is to examine all intraoral soft tissues. Oral health

care providers are the best trained to perform this examination, and it is unlikely patients will receive it elsewhere, making it a critical part of the overall examination. Oral cancer and premalignant oral lesions may develop at any site, so it is important to develop a consistent examination sequence to ensure no sites are overlooked. After illuminating the field with an adequate light source, the examination begins with the lips, observing any loss in the normally sharp cutaneous/vermillion demarcation, surface changes or color irregularities. Bimanual palpation of the lips is essential to rule out submucosal growths. While reflecting the lips and retracting the commissures, one can look for any surface, submucosal and hard tissue changes involving the labial/buccal mucosae, labial/attached gingivae and maxilla/mandible. Stensen's ducts should be identified and assessed for normal color, patency and clear saliva flow. The anterior two-thirds of the tongue (dorsal, lateral and ventral surfaces) are generally easy to visualize and palpate. A piece of gauze may be wrapped around the tongue to allow access to the posterior aspect of the dorsum and posterolateral border of the tongue where the foliate papillae can be visualized and compared bilaterally (**FIGURE 3**). The posterior one-third of the tongue is more difficult to visualize directly, however, it may be palpated and/or visualized indirectly by mirror, gag reflex permitting. Because surface changes involving the floor of the mouth may be subtle, air drying this region facilitates examination. Bimanual palpation for any growths or asymmetry can be achieved by moving two opposing fingers, one extraorally and the other intraorally, from posterior to anterior, palpating the interposing soft tissue (**FIGURE 4**). The oropharynx and retromolar trigone

# Some folks didn't believe.

**Apple** would transform consumer electronics.

**Google** would transform the way we use computers.

**Starbucks** would transform the retail business model.

**Nike** would transform leisure time.

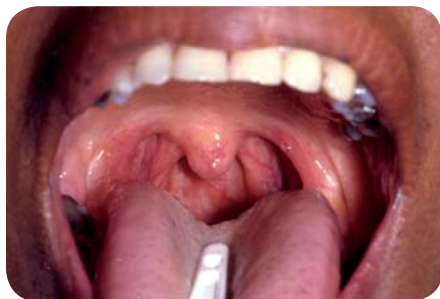We want to team up with you to transform  
private dental practice management.

<b>See how.</b>	<b>Visit</b>	<a href="http://www.stratusdental.com/cda">www.stratusdental.com/cda</a>
	<b>Call</b>	888.708.8639
	<b>Email</b>	<a href="mailto:info@stratusdental.com">info@stratusdental.com</a>



Believe. Believe. Some  
Now it's your turn. S



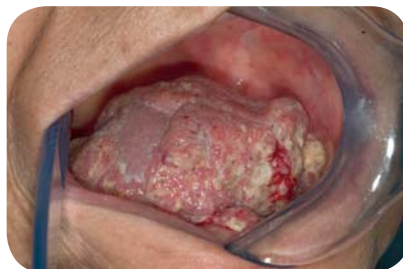

**FIGURE 5.** Intraoral examination of the oropharynx/retromolar trigone.

are often overlooked. It includes the soft palate and uvula, the anterior and posterior pillars (or fauces), the palatine tonsils (or scars from their removal), the base of the tongue (including the lingual tonsils) and the posterior pharyngeal wall. The term retromolar trigone describes the area distal to the retromolar pad encompassing some of these structures. A tongue blade or mirror can facilitate retraction of the tongue to evaluate these sites (**FIGURE 5**). The posterior pharyngeal wall can be examined by pushing down on the tongue and by asking the patient to elevate the uvula (by saying “ahh”). Palpation, in addition to visualization, of both the hard and soft palate is also important because small submucosal masses can be missed by visualization alone. Visualization-based screening adjunctive techniques may be employed once the standard examination has been completed (see below).

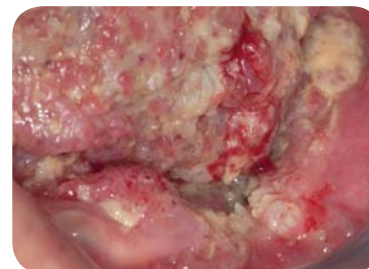
### Abnormal Findings

Most abnormal oral mucosal findings are benign in nature and have no malignant potential. Once encountered, the first step in the diagnostic process is to reach one or more provisional diagnoses (i.e., differential diagnosis) based upon a synthesis of the patient's demographics, history and physical examination. Depending upon experience and level of training, oral health care providers will have varying diagnostic abilities. Regardless of ability, there is a legal obligation to inform the patient in

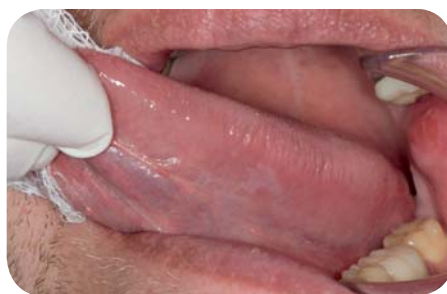

**FIGURE 6.**

**FIGURE 6.** Advanced SCCa involving the left side of tongue, floor of mouth and alveolar ridge. Note nodularity and bleeding. The lesion also shows palpable induration and there is a fixed lymphadenopathy associated.

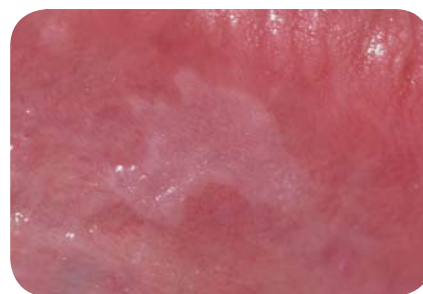

**FIGURE 6.** Detail

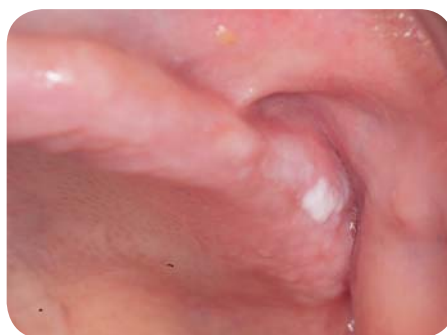

**FIGURE 7.**

**FIGURE 7.** Homogeneous leukoplakia of left ventral tongue. Note thin translucent change not associated with any apparent etiology. Biopsy revealed mild epithelial dysplasia.

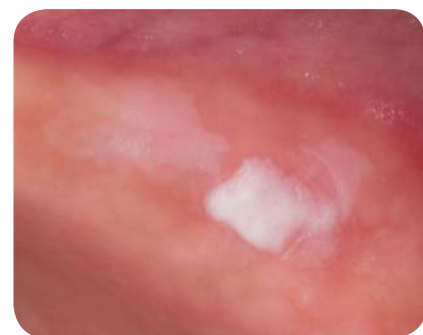

**FIGURE 7.** Detail



**FIGURE 8.**

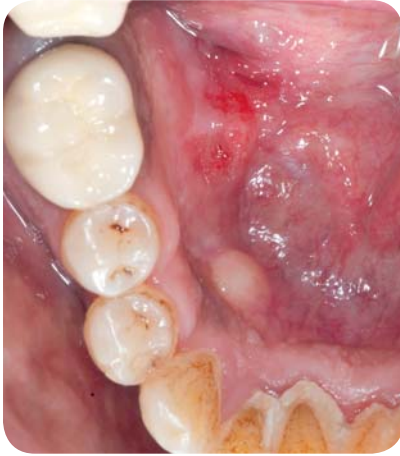**FIGURE 8.** Nonhomogeneous leukoplakia of left maxillary edentulous ridge. Note different shades of white. Biopsy of the thicker area revealed mild epithelial dysplasia.



**FIGURE 8.** Detail

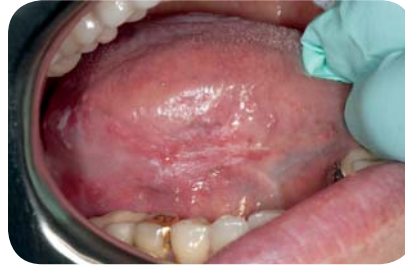terms he or she will understand about the nature of the finding and what the plan is to reach a definitive diagnosis and/or rule out serious pathology. There have been numerous legal precedents where oral health care providers have incurred damages because of a delay in diagnosis.<sup>14</sup> Recording the diagnostic process following baseline detection is critical and descriptive chart entries accompanied by photographic documentation are recommended.

Abnormal epithelial lesions for which the clinician can find no obvious cause to suggest a benign process should be considered to have malignant potential. Such lesions must undergo further evaluation to rule out epithelial dysplasia (a precancerous histopathologic diagnosis) or malignancy (i.e., SCCa). Given the unpredictable natural history of oral carcinogenesis coupled with the time point at which the disease has progressed to at the time of detection,



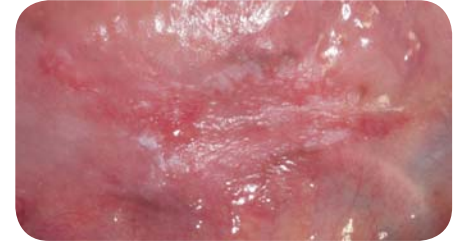
**FIGURE 9.** Erythroplakia right floor of mouth. Biopsy revealed SCCa.

oral premalignant and malignant lesions (OPMLs) demonstrate variable clinical presentations. At one end of the disease spectrum clinicians may encounter advanced cancers that have such obviously suspicious features (i.e., severe pain, large tumor, induration, lymphadenopathy, loss in function) (**FIGURE 6**) that there is no question as to their diagnosis. At the other end of the spectrum, at the earliest time point when a nest of neoplastic cells is microscopic in size and confined to the epithelium, there will be no symptoms and it may be impossible to appreciate any clinical signs. If genetic mutations in these cells are sufficient to drive carcinogenesis, the neoplastic cells will divide, uncontrolled, and their collective volume will expand over time to manifest as a visible epithelial lesion. Early changes may be subtle and appear clinically innocuous, indistinguishable from epithelial lesions with no malignant potential. Further evolution leads to a progressive accumulation of mutations and a worsening of both clinical and histopathologic features, and the period of time to malignant transformation is variable, nonlinear, unpredictable and may range from months to years. Each OPML harbors a different blend of mutations. As clinicians, we are currently unable to profile our patients' genes; therefore, we rely on our clinical acumen to determine

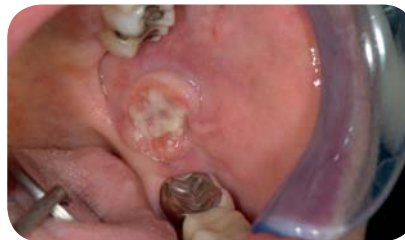

**FIGURE 10.**

**FIGURE 10.** Erythroplakia of the right lateral tongue. Biopsy revealed carcinoma in situ.

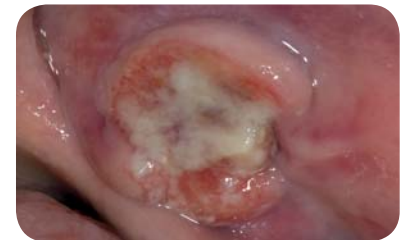

**FIGURE 10.** Detail

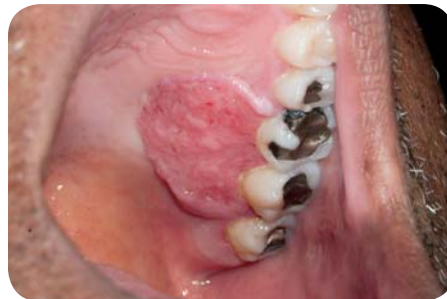

**FIGURE 11.**

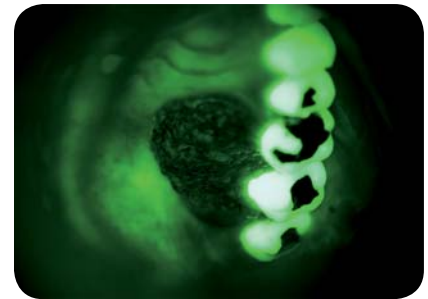
**FIGURE 11.** Solitary ulcer thought to be traumatic. Note rolled borders. The lesion also was mildly indurated. Biopsy revealed SCCa.



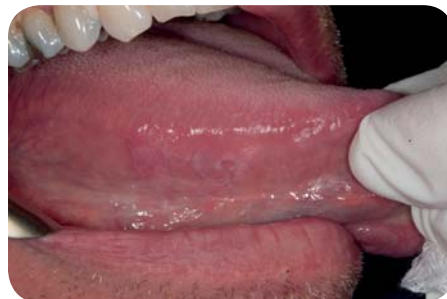**FIGURE 11.** Detail



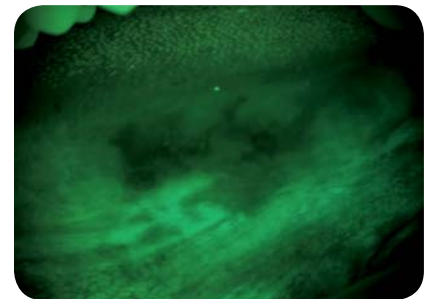
**FIGURE 12A.**



**FIGURE 12A.** Fluorescence



**FIGURE 12B.**



**FIGURE 12B.** Fluorescence

**FIGURE 12.** Showing fluorescence loss (FVL) in two patients, one with a palatal/gingival SCCa (**12A**), and one with severe epithelial dysplasia of the right lateral tongue (**12B**). Note normal surrounding mucosa displays an apple-green fluorescence.

whether an abnormal finding we detect raises suspicion. In general, serious pathology will demonstrate persistence and progressiveness. Most inflammatory, infectious or traumatic lesions will heal in two to three weeks, assuming the cause is

eliminated, and clinicians may cautiously consider such a “wait-and-watch” strategy following removal or treatment of a putative etiology (e.g., smoothing a sharp tooth rubbing against the tongue) before biopsy to rule out an OPML.



Lesion color is an important clinical feature of OPMLs, and the term “leukoplakia” is a clinical diagnosis applied to a nonwipeable white plaque for which no cause can be determined.<sup>15</sup> Leukoplakias may be homogeneous (i.e., the white change is uniform throughout the lesion and often translucent or with mild fissuring) (FIGURE 7) or nonhomogeneous (FIGURE 8). Similarly, erythroplakia and erythroleukoplakia refer to a red and mixed red/white plaque respectively for which no cause can be determined (FIGURES 9 AND 10). A red component is generally a more ominous feature than white alone. Ulceration, often yellow/tan in color because of the surface pseudomembrane, may be a clinical feature of OPMLs and may appear either alone (FIGURE 11) or in combination with red and/or white changes. OPMLs may display other clinical features ranging from plaque-like and smooth to exophytic with surface irregularity (i.e., granular, fissured or verrucous), or to superficially or deeply ulcerative (sometimes with rolled borders) or with combinations of such features. Induration (a firmness or hardness to palpation) may be commensurate with SCCa due to infiltration of the cancer into submucosal structures. Friable lesions (i.e., bleeding upon slight provocation) can indicate high-grade dysplasia or SCCa. Clinicians often associate pain only with advanced cancers, but small early cancers can be painful.<sup>16</sup> OPMLs with a larger surface area or with multifocal changes should raise higher suspicion. A condition known as “proliferative verrucous leukoplakia” (PVL) is associated with multifocal changes and carries a high risk for malignant transformation.<sup>17</sup>



FIGURE 13A.

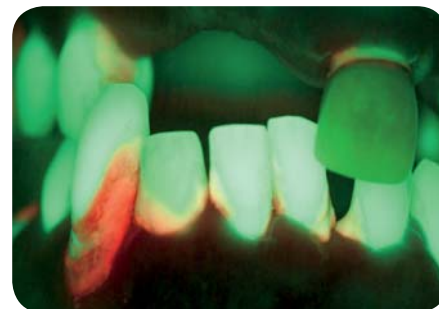


FIGURE 13B.

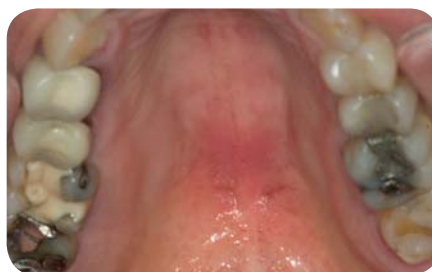

FIGURE 13C.

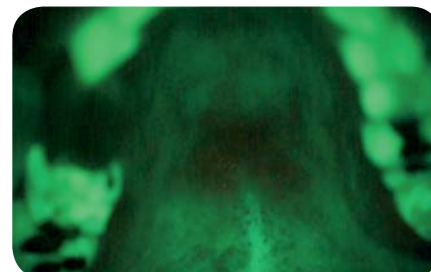


FIGURE 13C. Fluorescence

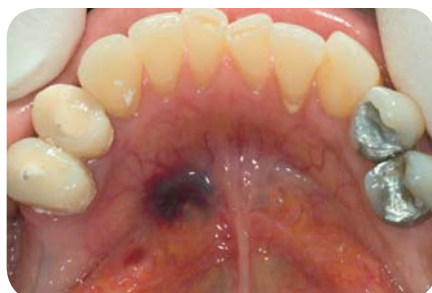

FIGURE 13D.

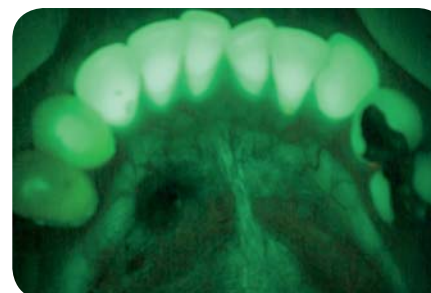


FIGURE 13D. Fluorescence

**FIGURE 13.** Handheld VELscope (13A) showing blue light. Bacterial porphyrins fluoresce orange, porcelain crown absorbs fluorescence, and normal enamel shows a strong fluorescence (13B). Confounder lesions (FVL) are erythematous candidiasis in a patient using an asthma inhaler (13C) and a hematoma secondary to an anesthetic infection (13D).

Note that other oral malignancies, which collectively account for < 10 percent, such as salivary gland malignancies, sarcomas, melanomas, lymphomas and other myeloproliferative malignancies, also share similar attributes of being persistent and progressive, except that they are not epithelially derived.

Following the detection of lesions with suspicion for OPMLs, a tissue biopsy and histopathologic diagnosis is generally performed to rule out dysplasia or SCCa. Diagnostic adjunctive techniques may be employed to facilitate this process (see below).

### Visualization-based Adjunctive Techniques

Several visualization-based devices are available in the marketplace and intended for use as screening adjuncts to the standard visual and tactile oral examination. They are thought to work under the premise that mucosal tissues undergoing abnormal metabolic or structural changes have different absorbance/reflectance profiles when exposed to various forms of light or energy.

There are two adjunctive techniques based on tissue autofluorescence, the VELscope system (LED Dental Inc.,

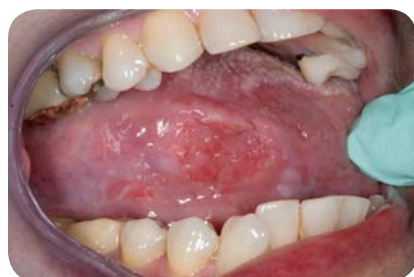

FIGURE 14A.

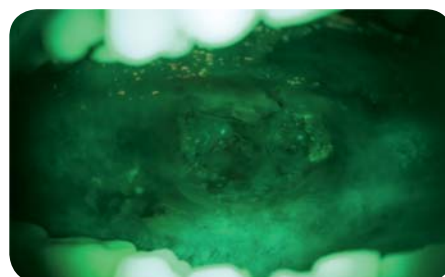


FIGURE 14A. Fluorescence

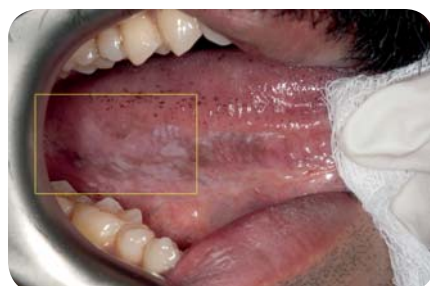

FIGURE 14B.

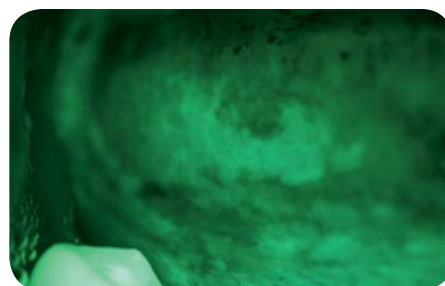

FIGURE 14B. Fluorescence

**FIGURE 14.** Showing lack/minimal fluorescence loss in two patients, illustrating false negatives. The lesion involving the right lateral tongue (**14A**) shows minimal loss of fluorescence despite being an SCCa. The leukoplakia involving the right lateral tongue (**14B**) shows an increase in fluorescence. Note pigmented changes showing FVL.

White Rock, British Columbia) and the Identafi 3000 system (DentalEZ Group, Malvern, Pa.). Both are multiuse hand-held devices that generate a blue-violet light (in the 400-450 nm range) that can excite naturally occurring tissue fluorophores (i.e., molecules such as FAD and NADH in the epithelium, and both collagen and elastin cross-links in the submucosa<sup>38</sup>) revealing a visible fluorescence emission thus enabling clinicians to visually scan the mucosa, in a darkened environment, for abnormal disruptions in autofluorescence. The VELScope system is user-friendly and there is evidence demonstrating that biopsy-proven SCCa and high-grade dysplastic lesions show a characteristic “loss of fluorescence visualization” (FVL)<sup>39</sup> (**FIGURE 12**). However, such lesions have a low prevalence and clinicians using these devices must be able to distinguish them from more common benign lesions that can also show loss of fluorescence (**FIGURE 13**), as is the case with erythematous inflammatory lesions, vascular changes or pigmented changes that all absorb blue light (i.e.,

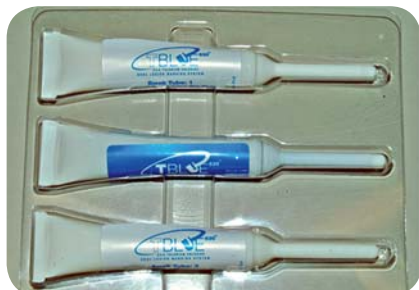so-called “confounder” lesions). There are currently no studies to support or refute whether autofluorescence devices should be employed routinely as a screening adjunct. There are studies exploring their use as a diagnostic adjunct in patients presenting with OPMLs. In the two published studies conducted by specialists on patients with OPMLs, VELscope performance compared to histopathologic diagnosis showed a range in sensitivity from 50-86 percent (i.e., ability to detect a truly positive outcome) and a 15-30 percent specificity (i.e., ability to detect a truly negative/benign outcome) for detecting dysplasia or SCCa,<sup>20,21</sup> suggesting that not all dysplastic lesions/SCCa demonstrate FVL (**FIGURE 14**), and that this technology is poor at differentiating benign lesions from dysplasia/SCCa. Preliminary data suggest that specificity may be bolstered by reappointing patients with FVL lesions three weeks later to rule out benign inflammatory lesions.<sup>22</sup> There is a learning curve in the use of autofluorescence devices and clinicians who implement them in their practice

can benefit from continuing education in the differential diagnosis of mucosal diseases, enabling them to better recognize benign confounder lesions. While most FVL lesions are also visible under standard lighting, there is some evidence to suggest that loss of fluorescence may precede clinical changes,<sup>23</sup> although more research is needed to appreciate whether earlier detection can significantly affect outcomes.

Described as a chemiluminescent light detection system, the ViziLite Plus system (Zila, a Tolmar Inc. company, Fort Collins, Colo.) consists of a prescreening acetic acid swish, followed by examination with a handheld wand that emits a chemically activated low-energy, blue-white light. If a lesion is detected, the system comes bundled with toluidine blue to further evaluate the lesion. Sites of atypical epithelium are purported to preferentially reflect the light thereby generating an “acetowhite” change. Working under a similar premise, the Microlux/DL system (AdDent Inc., Danbury, Conn.), and the Orascope DK system (Orascope, a Kerr Company, Middleton, Wis.) are multiuse systems using light-emitting diodes (LEDs). Based on the studies conducted, the use of these adjunctive techniques is not warranted.<sup>24</sup>

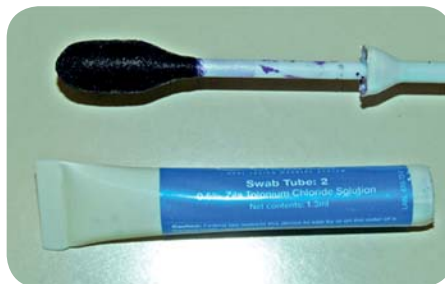### Vital Staining — Toluidine Blue

Toluidine blue (TB) staining has been used for more than half a century as a diagnostic adjunctive technique for assessing OPMLs following their detection during a standard examination. Its use as a screening adjunct for the general population has not been validated. It is a vital stain that rapidly and preferentially binds to actively dividing tissue that contains more nucleic acids than normal tissues. The dye also works on the premise that dysplastic cells are less cohesive and as such, the dye will be able to penetrate easily

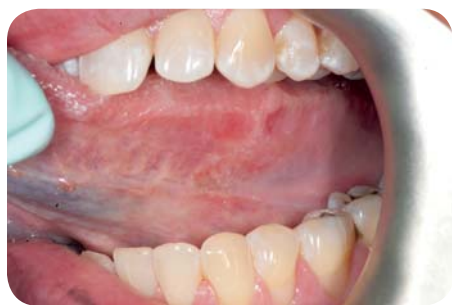

**FIGURE 15.**

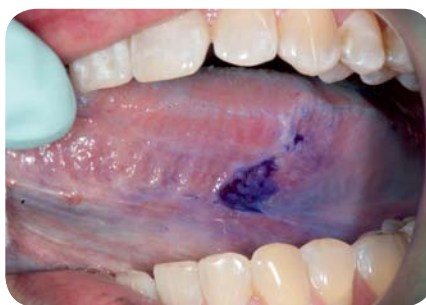**FIGURE 15.** Commercially available toluidine blue staining kit from Zila.



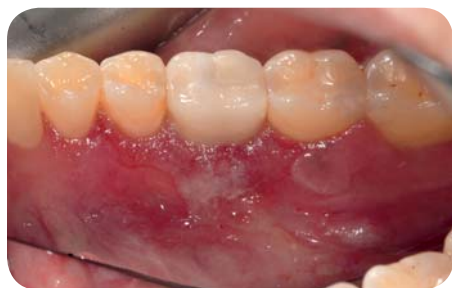**FIGURE 15.** Detail



**FIGURE 16A.**

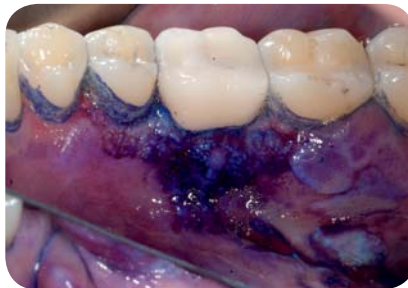

**FIGURE 16A.** Toluidine blue staining



**FIGURE 16B.**

**FIGURE 16.** Showing true positive toluidine blue staining. The ventral tongue lesion (16A) was thought to be traumatic. It was not indurated. Biopsy revealed SCCa. The mixed lesion visualized on the lingual gingivae (16B) revealed carcinoma in situ. Note the margins of this lesion along with satellite changes are visualized.



**FIGURE 16B.** Toluidine blue staining

between and into the cells. A user-friendly test kit may be purchased commercially along with ViziLite Plus and is composed of three swab tubes: two tubes with 1 percent acetic acid (prerinse and postrinse) and one tube with 0.5 percent toluidine blue solution (a pharmaceutical-grade toluidine blue) (FIGURE 15). The first step involves swabbing the lesion with the 1 percent acetic acid to remove surface debris, followed by a rinse with water for 10 seconds and then swabbing with the toluidine blue for 20 seconds. Finally, the area is swabbed with the second acetic

acid tube to remove the excess toluidine blue dye. The lesion is then evaluated for staining and retention of the blue stain, and a royal to dark blue color is considered positive (FIGURE 16).

The sensitivity and specificity of the toluidine blue test for detection of dysplastic lesions and SCCa has a broad range as reported by different studies.<sup>24</sup> Three recent studies conducted on patients with OPMLs tested with toluidine blue showed a range in sensitivity of 56-67 percent and a specificity of 57-81 percent for dysplasia or SCCa.<sup>25,26,27</sup> There was

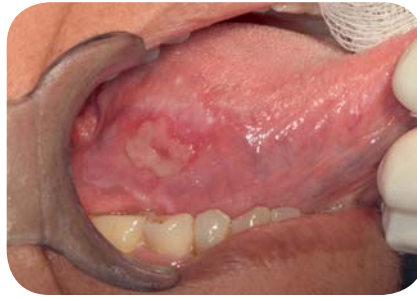a trend of increasing sensitivity with worsening disease (i.e., poorest sensitivity in lesions with mild dysplasia and highest in those with SCCa where sensitivity exceeded 90 percent). The broad ranges of values for sensitivity and specificity may be attributed to several factors including the population of OPMLs tested (a higher percentage of high-grade dysplasias and SCCa will lead to higher sensitivity), variability in the testing protocols and in the interpretation of cases of light or equivocal staining (some authors assigned a light-blue stained lesion as positive and others as negative) and differences in the clinical expertise of reporting authors. These studies show that, similar to the visualization adjunctive techniques, there is a potential for both false positives and false negatives and clinician experience is important. False positives may result when inflammatory, ulcerative and regenerating tissues are stained blue (FIGURE 17), because these tissue types also contain actively dividing cells. The recommendation of reevaluation and possibly restaining two to three weeks after baseline can reduce false-positive findings and prevent unnecessary surgical biopsies.<sup>24</sup> The tongue filiform papillae will retain the dye and false positive results can also occur when the dye is mechanically retained in the crevices of rough or fissured lesions. On the other hand, false negatives can occur and may be due to the inability of the dye to penetrate through thick hyperkeratotic tissue in some leukoplakias (FIGURE 18).

Specialists use toluidine blue to help in guiding biopsy site selection and reducing sampling error, especially with larger, nonhomogeneous, mixed or multifocal lesions where variable histopathology can exist within a lesion or between lesions. Toluidine blue also has utility in monitoring of high-risk patients with a past history of SCCa or dysplasia.



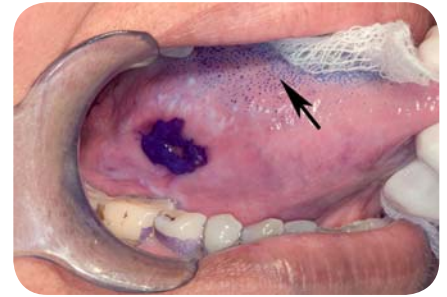
### Cytopathologic-based Adjuncts

The concept of cytological diagnosis of malignancy was based on the work of Papanicolaou and Traut, who developed this idea for gynecological diagnosis. Using exfoliative cytology to diagnose oral cancer and precancerous lesions was proposed back in the 1950s; it went out of favor and then was reintroduced in 1999 with the computer-assisted brush biopsy known as the OralCDx BrushTest (CDx Laboratories, Suffern, N.Y.). Currently, this is the only marketed cytopathologic test available to clinicians in the United States. This diagnostic adjunctive technique has a patented brush that is specifically designed to collect a transepithelial specimen of cells from all layers of the epithelium and it is indicated for small innocuous-appearing epithelial lesions for which a cause cannot be determined. Each kit comes with detailed instructions, but to summarize, topical or local anesthesia is not required and clinicians rotate the brush approximately 10 times directly on the lesion with moderate pressure until there is clinical evidence of a transepithelial sample (i.e., including the deeper basal and parabasal cells, which are the first to show dysplastic changes), which is usually pinpoint bleeding. The brush should then be spread onto a glass slide, fixed by squeezing an alcohol fixative packet generously over the slide and allowed to air dry. There are residual cells on the brush and CDx Labs provides a vial of fixative into which the brush may be placed as a backup. The slide should then be placed into the plastic slide holder and put in the postage-paid box provided, along with the completed patient data form and insurance information. At the laboratory, the slide is stained and analyzed to identify abnormal cellular morphology, such as increased nuclear to cytoplasmic

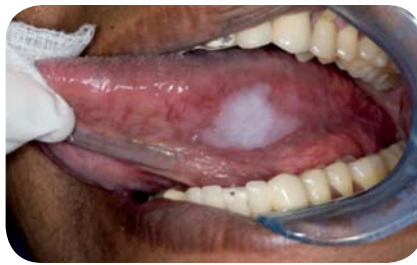

**FIGURE 17.**

**FIGURE 17.** Showing false positive toluidine staining. This was an ulcer related to a lichenoid mucositis (note the white reticular changes at the periphery).

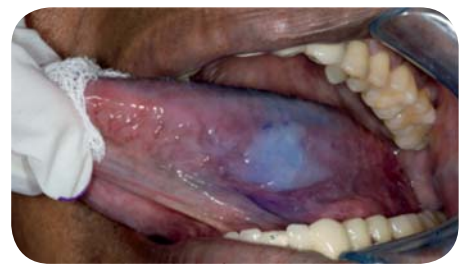

**FIGURE 17.** Toluidine blue staining

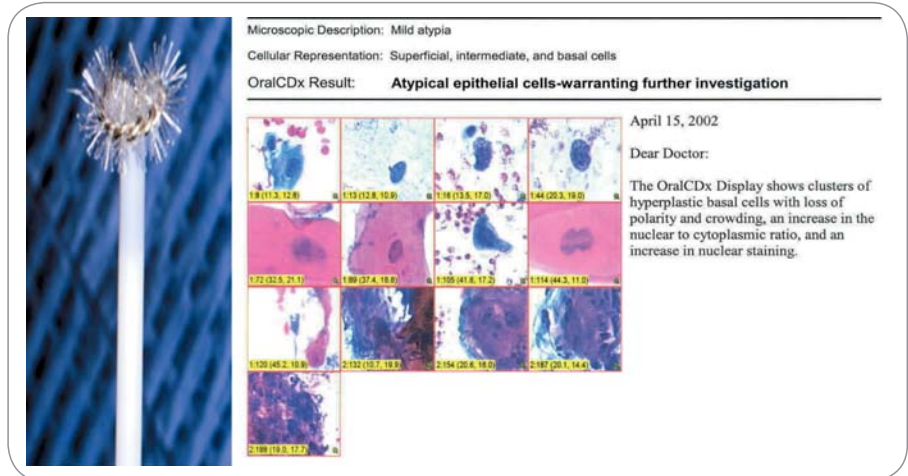


**FIGURE 18.**

**FIGURE 18.** Showing a false negative toluidine blue staining. This was a leukoplakia with mild epithelial dysplasia.



**FIGURE 18.** Toluidine blue staining



**FIGURE 19.** OralCDx BrushTest showing the brush and a report. Note the gallery of abnormal cells and an atypical test result warranting scalpel biopsy revealing a carcinoma in situ.

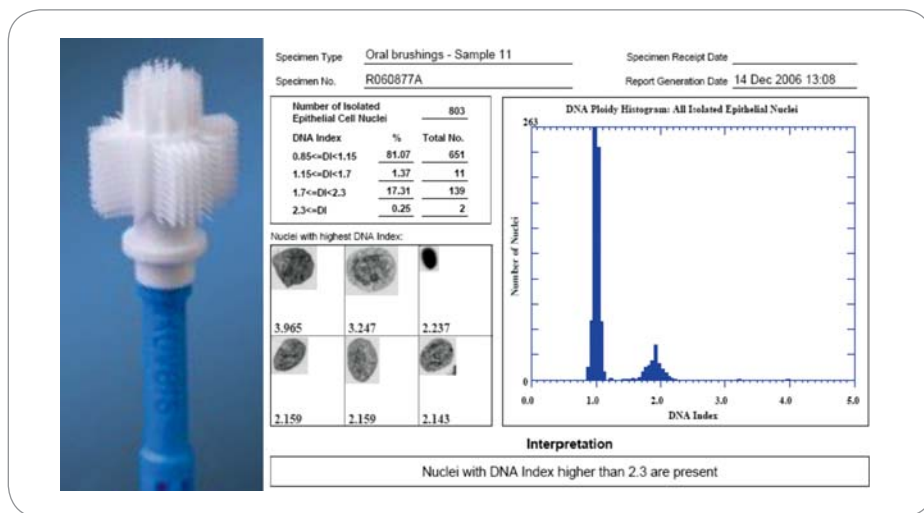
ratio, that is often commensurate with SCCa or dysplasia. A gallery of abnormal cells (**FIGURE 19**), if any, are evaluated by a cytopathologist, and a final test report with color microscopic images is then faxed and mailed to the submitting clinician within two weeks. There are four possible results: negative, positive, atypical and inadequate. Any

positive or atypical result warrants further evaluation, and may require the patient to undergo scalpel biopsy and histopathologic evaluation.

The accuracy of the OralCDx Brush-Test has been reported in several studies with sensitivity and specificity ranging from 71-100 percent and 27-94 percent respectively.<sup>24</sup> A number of

these studies had flaws in methodology and in those studies in which a suspicious lesion was brush tested and then scalpel biopsied at the same time and location, the OralCDx BrushTest demonstrated a sensitivity and specificity above 90 percent. In a recent study where minimally suspicious lesions were brushed and results compared to matched histopathology, the sensitivity and specificity were 96 percent and 100 percent respectively.<sup>28</sup> False positives, generally an “atypical” result, may be generated from some benign inflammatory lesions because cellular atypia is possible in inflamed tissue. False negatives, while rare, can lead to significant diagnostic delays. False negatives may be minimized if the OralCDx BrushTest is used as indicated on small, relatively flat epithelial lesions in which a representative sample of the lesion can be procured by the brush. Markedly keratotic leukoplakias are more difficult for the brush to penetrate the thick keratin and reach the basal cell layer, and scalpel biopsy is preferable. This brush test should not be used on submucosal or exophytic soft tissue lesions such as fibromas or mucocoeles, or on pigmented and vascular lesions. It is also not indicated for obvious cancerous or highly suspicious lesions, as it does not yield a histopathologic diagnosis and therefore could cause an unnecessary delay in definitive diagnosis and treatment.

One other cytopathologic test that is pending approval in the United States but currently available in Canada and Europe is OralAdvance (Perceptronix, Vancouver, Canada). This diagnostic adjunct is also based on collecting a cell sample from the lesion with a brush. The brush head is placed in a fixative and sent to a central laboratory where the sample is placed on a



**FIGURE 20.** OralAdvance test showing a Rovers Oracellex brush and a report. Note the gallery of abnormal nuclei and the second peak showing abnormal DNA content. A scalpel biopsy revealed severe epithelial dysplasia.

slide and the cells undergo nuclear staining and microscopic analysis of DNA content using sophisticated recognition software. A result showing abnormal DNA content (**FIGURE 20**), i.e., cells where there has been a gross genomic change secondary to gene mutations and that deviate from the normal diploid state, is commensurate with dysplasia or carcinoma and may be a predictive marker for malignant transformation.<sup>29</sup> This platform has recently been validated in a small trial enrolling 171 patients with suspicious lesions, showing that the sensitivity and specificity of this platform for detecting high-grade dysplasia and SCCa was 89 percent and 97 percent respectively.<sup>30</sup>

These cytopathologic tests based upon cellular morphologic changes are appealing to both patients and clinicians because they are noninvasive. Research is underway to develop cytopathologic-based platforms that may be able to provide real-time results (i.e., chairside results within minutes).

### Human Papillomavirus Testing

Based on data from the National Health and Nutrition Examination Survey (NHANES) study, the prevalence of oral HPV-16 infection in Americans is estimated to be approximately 1

percent, and incidence rates for HPV-associated oropharyngeal cancers are 2.6 per 100,000.<sup>7</sup> The OraRisk HPV Salivary Diagnostic Test (OralDNA Labs, Eden Prairie, Minn.) is commercially available to clinicians for the purpose of detecting the presence of HPV-16 DNA in the saliva. Its ability as a screening adjunct to detect or predict HPV-16 associated malignancies has not been studied and a positive test merely demonstrates the presence of the virus in the saliva, the significance of which is unclear because little is known about the natural history of oral HPV-16 infection in terms of factors that predict either clearance or persistence of HPV-16 infection or, indeed, malignant transformation. Most HPV-associated oral cancers involve the oropharynx, principally the lymphoid tissues (i.e., palatine and lingual tonsils), so a positive test would likely trigger the need for careful evaluation of the oropharynx (including the base of tongue). Oral health care providers are not trained, nor equipped, to perform a pharyngoscopy, thus indicating a referral to an otolaryngologist. However, visual inspection of the oropharynx, or even a “pap-smear” equivalent cytopathologic sweep of the

tonsillar tissues may not be sufficient to detect a small primary cancer because HPV-16 seems to favor the depths of the tonsillar crypts.<sup>31</sup> Studies exploring the utility of ultrasonography are ongoing.

There is currently no evidence to support opportunistic screening by oral health care providers for HPV-16 (i.e., screening at new patient or recall visits). However, for patients who ask to be tested or who have received a positive result from another clinician, it is important for clinicians to be able to discuss the meaning of such results, educate them about risk factors for HPV transmission (i.e., sexual contact), and, in the absence of signs and symptoms for oral or oropharyngeal cancer, consider follow-up testing within a six-month period. In addition, there are a number of laboratory-based studies to determine the presence of HPV in biopsied tissue samples from OPMLs, although the value of adding such studies to conventional histopathology has not been determined.

### Emerging Adjunctive Techniques

In the era of genomics and proteomics, a search of the medical literature will reveal a plethora of papers describing putative biomarkers for oral cancer and precancer.<sup>32</sup> Unlike some cancers where a single gene mutation can cause cancer, the mutational landscape of head and neck SCCa is complex<sup>33</sup> and each cancer is the result of a variable blend of mutations in the context of variable patient factors. This has led to the testing of combinations of biomarkers that are diagnostic or predictive for oral cancer and validation studies are underway. Other emerging technologies include visualization-based adjuncts such as optical spectroscopy and real-time histology using high-resolution microendoscopy that could abrogate the need for routine biopsies.

### Conclusion

The prognosis for many other human cancers has greatly improved over the last decade. However, the five-year survival rate for oral and pharyngeal cancers has not kept pace and shown significant improvement. Oral health care providers in general practice are at the frontline and can make a real impact by performing comprehensive extraoral and intraoral exams on each patient and appropriately using the various adjunctive techniques described in this paper to help assess the degree of suspicion of any mucosal abnormalities identified. Continuing education in the diagnosis and management of mucosal diseases can facilitate the use of these adjuncts. The gold standard for definitive diagnosis of oral lesions remains scalpel biopsy with microscopic examination, although there is promise of noninvasive, real-time diagnostic techniques on the horizon. ■■■■

### REFERENCES

1. American Cancer Society. *Cancer Facts and Figures*. Atlanta: American Cancer Society, 2013.
2. California Department of Public Health, *California Cancer Facts and Figures, 2012*. Oakland, Calif.: American Cancer Society, California Division, 2011.
3. Howlader N, Noone AM, Krapcho M, et al. *SEER Cancer Statistics Review, 1975-2009*. Bethesda, Md.: National Cancer Institute, 2012.
4. Warnakulasuriya S. Causes of oral cancer—an appraisal of controversies. *Brit Dent J* 2009;207(10):471-5.
5. D'Souza G, Kreimer AR, Viscidi R, et al. Case-control study of human papillomavirus and oropharyngeal cancer. *New Engl J Med* 2007;356(19):1944-56.
6. Lingen M. Low etiologic fraction for high-risk human papillomavirus in oral cavity squamous cell carcinomas. *Oral Oncol* 2012.
7. Gillison ML, Broutian T, Pickard RKL, et al. Prevalence of oral HPV infection in the United States, 2009-2010. *JAMA* 2012;307(7):693-703.
8. Napier SS, Speight PM. Natural history of potentially malignant oral lesions and conditions: an overview of the literature. *J Oral Pathol Med* 2008;37(1):1-10.
9. Rethman MP, Carpenter W, Cohen EEW, et al. Evidence-based clinical recommendations regarding screening for oral squamous cell carcinomas. *J Am Dent Assoc* 2010;141(5):509-20.
10. PRWeb California Dental Association Recommends Oral Cancer Screening. [www.prweb.com/releases/2012/4/prweb9408532.htm](http://www.prweb.com/releases/2012/4/prweb9408532.htm); 2012.
11. Chainani-Wu N, Epstein J, Touger-Decker R. Diet and prevention of oral cancer: strategies for clinical practice. *J Am Dent Assoc* 2011;142(2):166-9.
12. Chapter 7: The head and neck. In: Bickley LS, Szilagyi PG, editors. *Bates' guide to physical examination and history-taking*. 11th ed. Philadelphia: Lippincott Williams and Wilkins; 2013. p. 205-291.
13. Gregoire V, Lee N. Chapter 120: Radiation therapy and management of the cervical lymph nodes and malignant skull base tumors. In: Flint PW, et al., editors. *Cummings otolaryngology—head and neck surgery*. 5th ed. Philadelphia: Mosby; 2010. p. 1683-701.
14. Lydiatt DD. Cancer of the oral cavity and medical malpractice. *Laryngoscope* 2002;112(5):816-9.
15. Warnakulasuriya S, Johnson NW, van der Waal I. Nomenclature and classification of potentially malignant disorders of the oral mucosa. *J Oral Pathol Med* 2007;36(10):575-80.
16. Lam DK, Schmidt BL. Orofacial pain onset predicts transition to head and neck cancer. *Pain* 2011;152(5):1206-9.
17. Bagan JV, Jimenez-Soriano Y, Diaz-Fernandez JM, et al. Malignant transformation of proliferative verrucous leukoplakia to oral squamous cell carcinoma: a series of 55 cases. *Oral Oncol* 2011;47(8):732-5.
18. Poh CF, Lane P, MacAulay C, Zhang L, Rosin MP. The Application of Tissue Autofluorescence in Detection and Management of Oral Cancer and Premalignant Lesions. In: Rosenthal E, Zinn KR, editors. *Optical Imaging of Cancer*. New York Dordrecht Heidelberg London: Springer; 2010. p. 110-18.
19. Lane PM, Gilhuly T, Whitehead P, et al. Simple device for the direct visualization of oral-cavity tissue fluorescence. *J Biomed Opt* 2006;11(2):024006.
20. Mehrotra R, Singh M, Thomas S, et al. A cross-sectional study evaluating chemiluminescence and autofluorescence in the detection of clinically innocuous precancerous and cancerous oral lesions. [Erratum appears in *J Am Dent Assoc* 2010 Apr;141(4):388]. *J Am Dent Assoc* 2010;141(2):151-6.
21. Awan KH, Morgan PR, Warnakulasuriya S. Evaluation of an autofluorescence based imaging system (VELscope) in the detection of oral potentially malignant disorders and benign keratoses. *Oral Oncol* 2011;47(4):274-7.
22. Laronde DM, William PM, Ng S, et al. Abstract B27: Influence of fluorescence visualization on screening decisions in the general dental office. *Cancer Prevention Research* 2011;4(10 Suppl).
23. Truelove EL, Dean D, Maltby S, et al. Narrow band (light) imaging of oral mucosa in routine dental patients. Part I: Assessment of value in detection of mucosal changes. *General Dentistry* 2011;59(4):281-9; quiz 90-1, 319-20.
24. Patton LL, Epstein JB, Kerr AR. Adjunctive techniques for oral cancer examination and lesion diagnosis: a systematic review of the literature. *J Am Dent Assoc* 2008;139(7):896-905; quiz 93-4.
25. Cancela-Rodriguez P, Cerero-Lapiedra R, Esparza-Gomez G, Llamas-Martinez S, Warnakulasuriya S. The use of toluidine blue in the detection of premalignant and malignant oral lesions. *J Oral Pathol Med* 2011;40(4):300-4.
26. Rahman F, Tippu SR, Khandelwal S, et al. A study to

## WESTERN PRACTICE SALES | JMCA



Tim Giroux, DDS



Jon Noble, MBA



Mona Chang, DDS



John Cahill, MBA



Ed Cahill, JD

### What separates us from other brokerage firms?

As dentists and business professionals, we understand the unique aspects of dental practice sales and offer more practical knowledge than any other brokerage firm. We bring a critical inside perspective to the table when dealing with buyers and sellers by understanding the different complexities, personalities, strengths and weaknesses of one practice over another.

**We offer unsurpassed exposure -  
Marketing your practice in all of the major journals,  
including Dental Economics.**

**Let us provide a FREE  
"Opinion of Market Value"  
on your Practice\***

\*To be used for your internal purposes only. Not to be confused with a formal business appraisal.

### Testimonials

"The fact that you are a dentist adds a whole new dimension to your abilities as a broker, one which most other brokers cannot come close to"

"Your personal dedication to making everything happen was a unique touch"

"You gave me guidance that only a dentist would think of"

"Your experience & knowledge coupled with your kind personal touch I believe makes you the best in the industry!"

evaluate the efficacy of toluidine blue and cytology in detecting oral cancer and dysplastic lesions. *Quintessence Int* 2012;43(1):51-9.

27. Awan KH, Yang YH, Morgan PR, Warnakulasuriya S. Utility of toluidine blue as a diagnostic adjunct in the detection of potentially malignant disorders of the oral cavity — a clinical and histological assessment. *Oral Dis*; 2012.

28. Mehrotra R, Mishra S, Singh M, Singh M. The efficacy of oral brush biopsy with computer-assisted analysis in identifying precancerous and cancerous lesions. *Head Neck Oncol* 2011;3:39.

29. Bradley G, Odell EW, Raphael S, et al. Abnormal DNA content in oral epithelial dysplasia is associated with increased risk of progression to carcinoma. *Brit J Cancer* 2010;103(9):1432-42.

30. Ng SP, Mann IS, Zed C, Doudkine A, Matisic J. The use of quantitative cytology in identifying high-risk oral lesions in community practice. *Oral Surg Oral Med O* 2012;114(3):358-64.

31. Lingen MW. Brush-based cytology screening in the tonsils and cervix: there is a difference! *Cancer Prevention Research* 2011;4(9):1350-2.

32. Lingen MW, Pinto A, Mendes RA, et al. Genetics/epigenetics of oral premalignancy: current status and future research. *Oral Dis* 2011;17 Suppl 1:7-22.

33. Stransky N, Egloff AM, Tward AD, et al. The mutational landscape of head and neck squamous cell carcinoma. *Science* 2011;333(6046):1157-60.

**THE CORRESPONDING AUTHOR**, A. Ross Kerr, DDS, MSD, can be reached at [ark3@nyu.edu](mailto:ark3@nyu.edu).

[wps@succeed.net](mailto:wps@succeed.net)

[adstransitions.com](http://adstransitions.com)

[westernpracticesales.com](http://westernpracticesales.com)

**800.641.4179**





# Diagnosis and Management of Mucosal Lesions With the Potential for Malignant Transformation

BASSAM ISSA, BDS; RICARDO PADILLA, DDS; AND MICHAEL T. BRENNAN, DDS, MHS

**ABSTRACT** Squamous cell carcinoma is the most common oral cancer of the head and neck region. Up to 50 percent of these cancers have spread by the time of diagnosis; therefore, early diagnosis is vital. Oral lichen planus and epithelial dysplasia are two of the most common types of oral lesions with the potential for malignant transformation. The epidemiology and management of these conditions are discussed in this review.

## AUTHORS

**Bassam Issa, BDS,** obtained a bachelor of dental surgery degree from Jordan University of Science and Technology in Irbid, Jordan. He practices oral medicine and facial pain at Midwest Oral Medicine in Chicago. *Conflict of Interest Disclosure: None reported.*

**Ricardo Padilla, DDS,** obtained a doctor of dental surgery degree from Universidad Francisco in Marroquín. He is a clinical assistant professor in the Department of Oral and Maxillofacial Pathology

at the University of North Carolina in Chapel Hill. *Conflict of Interest Disclosure: None reported.*

**Michael T. Brennan, DDS, MHS,** obtained a doctor of dental surgery degree from the University of Iowa and a master of health science degree in Clinical Research from Duke University. He is associate chairman, Department of Oral Medicine, at Carolinas Medical Center in Charlotte, N.C. *Conflict of Interest Disclosure: None reported.*

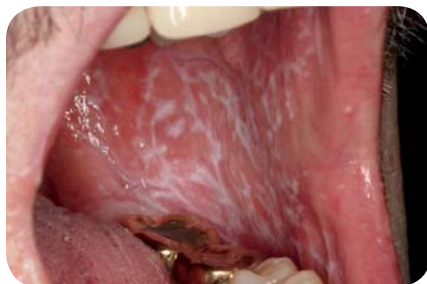Approximately 36,000 new cases of oral cancer are diagnosed in the United States annually.<sup>1</sup> The most common oral cancer is squamous cell carcinoma, representing approximately 90 percent of all oral cancer. Approximately half of cases have spread by the time a diagnosis is made, which leads to a poorer prognosis. Therefore, there is a vital need for an early diagnosis to be made for patients with oral lesions. Two of the most common types of premalignant oral lesions are lichen planus and epithelial dysplasia. This article will describe the epidemiology, diagnosis, malignant transformation and management of these oral conditions.

## Oral Lichen Planus

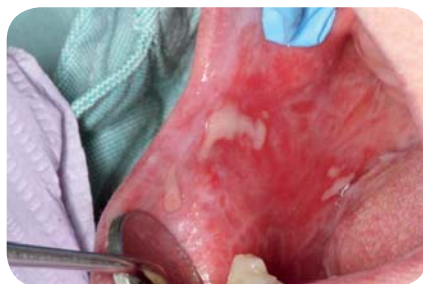### Epidemiology

Oral lichen planus (OLP) is a chronic mucocutaneous disorder that has an immune-mediated etiology.<sup>2</sup> These lesions are more typical in women (2:1) and appear between the ages of 30 and 60. The main etiologic triggers for this condition are unclear. Lichenoid reactions may have a similar appearance to OLP, but an allergen such as a medication or dental material is identified as the causative agent. OLP represents one of the most common immune-mediated disorders encountered in an oral medicine practice, with the prevalence of OLP between 0.5 percent and 2.2 percent of the population in published studies.<sup>2</sup>

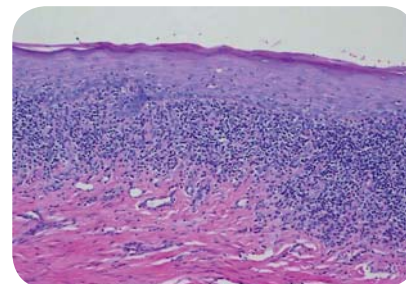




**FIGURE 1.** Reticular-type lichen planus of the left buccal mucosa in a 52-year-old male.



**FIGURE 2.** Biopsy-proven erosive lichen planus of the right buccal mucosa in a 62-year-old female.



**FIGURE 3.** Hematoxylin and eosin stained histological section of a specimen of lichen planus. There is a band-like lymphocytic infiltrate immediately underneath the epithelium exhibiting partial dissolution of the basement membrane and focal migration of lymphocytes into the epithelium. Some of the rete pegs exhibit a wedge or sawtooth-like architecture. No evidence of epithelial dysplasia is seen.

### Clinical Features

Clinically, OLP appears most commonly on the buccal mucosa. It may present clinically as white lines with a reticular pattern (**FIGURE 1**), as a whitish plaque and/or with an ulcerative/erosive pattern (**FIGURE 2**). These forms can coexist in the same patient, although one form might predominate. Many of the mucosal lesions associated with OLP are asymptomatic, but some patients may report discomfort and a burning sensation if they have the ulcerative/erosive forms of this condition. Usually, OLP is found bilaterally, which might be helpful in differentiating it from contact lichenoid reaction. A temporal relationship between the onset of the lesions and the start of a new medication or chemical substance is usually seen with lichenoid drug reactions.

### Diagnosis and Histopathological Features

The clinical features of OLP are occasionally sufficient to make a presumptive clinical diagnosis. However, a biopsy is most often necessary for a definitive diagnosis in order to rule out vesiculoerosive conditions, epithelial dysplasia or squamous cell carcinoma. Moreover, an upper endoscopic examination should be considered when symptoms of dysphagia are present.<sup>3</sup> Histopathologically, OLP is characterized by subepithelial lymphocytic infiltrate, hyperkeratosis, sawtoothed rete ridges, degeneration of the basal cell layer and

absence of dysplasia. Other findings may include apoptotic bodies or Civatte bodies (**FIGURE 3**).<sup>4</sup> Direct immunofluorescence findings may demonstrate fibrinogen deposition and may be helpful to establish the diagnosis and rule out other similar-appearing oral diseases (e.g., systemic lupus erythematosus).

### Malignant Transformation of OLP

Many studies have addressed the transformation rates of OLP into squamous cell carcinoma,<sup>5-7</sup> and this issue is still controversial. Inconsistencies in the incidence of malignant transformation reported by many studies could be related to the misdiagnosis of some lesions, variable time of follow-up, heterogeneity of the study population and exposure to other carcinogens.<sup>8</sup> Other factors may be related to different operational definitions used to diagnose OLP. The diagnostic criteria should be based on the histopathological changes described earlier and the clinical presentation.<sup>9</sup> Even with established histopathologic criteria, different interpretations by pathologists might occur.

The studies performed between 1924 and 2007 showed a frequency of transformation ranging from 0 to 12.5 percent.<sup>10</sup> Studies after 1980, noted in the review by Gonzales-Moles, demonstrate a transformation rate ranging between 0 and 6.4 percent.<sup>10</sup> A recent retrospective study from China reported a transformation rate of 0.96 percent.<sup>11</sup> Common methodological

limitations of these studies include an unclear follow-up period and lack of universally accepted diagnostic criteria. The annual transformation rate ranges between 0.22 percent and 0.36 percent according to three prospective studies with a recall system of patients.<sup>5</sup> Utilizing these annual transformation rates, if 100 patients with lichen planus are followed for 10 years, approximately two to four patients will have a malignant transformation. This is higher than patients without lichen planus.

At least annual follow-up is recommended for OLP because of the potential for malignant transformation.<sup>2</sup> Clinical signs and symptoms of malignant transformation may include induration upon examination, an area that does not respond to therapy, an enlarging lesion, development of a verrucous surface architecture or presence of a fixed lymph node. The presence of these findings would warrant a biopsy to rule out malignant transformation.

### Management

The main goal of the management of OLP is to reduce the pain associated with the lesions. The outcome is usually evaluated subjectively, commonly using a visual analog scale for symptoms. However, a wide range of methods have been used to assess management strategies for OLP.

Four main classes of medical interventions were identified in the literature: topical and systemic corticosteroids, retinoids and calcineurin inhibitors.<sup>2</sup>

- Topical corticosteroids include clobetasol propionate, betamethasone, dexamethasone, fluocinonide and triamcinolone. These agents are considered the first line of treatment and the most commonly used drugs.<sup>12</sup> They are effective when applied directly to the lesion two to three times a day for two to four weeks depending on the agent and concentration used. A challenge with their use is the adherence to the oral mucosa. Topical steroids can be used with or without an oral adhesive base,<sup>13</sup> such as triamcinolone in Orabase. If they are used without adhesive vehicles, prescribing them as a gel rather than an ointment or cream and applying them to previously dried mucosa increases their adhesion. Numerous other formulations are available, but no clear advantages have been identified based on clinical studies.<sup>2</sup> Topical steroids are considered relatively safe, but a potential side effect of their use is the development of a fungal infection. Topical steroids modulate the inflammatory and immune response. In case of multiple widespread lesions, one option for a topical steroid would be dexamethasone oral elixir (0.5 mg/5 mL) used as a mouthwash that can be swished and expectorated, with a frequency of up to three to four times a day.
- If topical steroids do not provide sufficient relief, an injectable corticosteroid, such as triamcinolone 10 mg/mL, can be considered. Systemic corticosteroids are used if the lesion is resistant to topical corticosteroids, there are multiple sites involved or if

the case is severe. Prednisone 0.5-1.0 mg/kg per day is the recommended dose until a response is achieved.<sup>2</sup> Systemic corticosteroids have the potential for more significant side effects, therefore a thorough medical history needs to be taken and the patient's physician should be consulted before use.

- Retinoids, such as tretinoin, have been used for the treatment of OLP, but have been less effective than topical corticosteroids. They are associated with a transient burning sensation.<sup>2</sup>
- Calcineurin inhibitors, such as topical cyclosporine, have shown some effectiveness in the management of OLP. However, cyclosporine rinse was not significantly better than 1 percent triamcinolone paste.<sup>14</sup> Tacrolimus and pimecrolimus are other calcineurin inhibitors. Tacrolimus is more potent than cyclosporine and has a better percutaneous and mucosal absorption. Similar to retinoids, a burning sensation is one of its side effects. The FDA has issued a "black box" warning stating that rare cases of malignancy (e.g., skin and lymphoma) have been reported in patients treated with topical calcineurin inhibitors,<sup>14</sup> and a case report in the literature involves squamous cell carcinoma of the tongue with the use of tacrolimus.<sup>15</sup>

#### *Other Treatment Modalities*

- Phototherapy: Psoralen UltraViolet A Light (PUVA) was shown to have some benefit in one small study of 16 patients treated for oral lichen planus,<sup>16</sup> although there can be logistic limitations with this type of delivery system.
- Laser therapy: An Er:YAG laser was used to treat nonerosive/nonulcerative OLP in a case report of two patients.

Recurrence was noted in one case 15 months after treatment.<sup>17</sup>

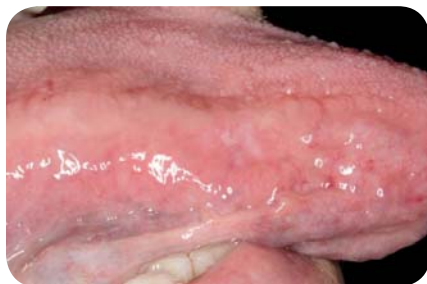- Aloe vera mouth rinse: No significant difference was found between the use of aloe vera rinse and triamcinolone acetonide 0.1 percent.<sup>18</sup>
- Lycopene: In a randomized control study of 30 patients, an 84-percent reduction in burning sensation was reported after the use of lycopene 8 mg/day for eight weeks compared to 67 percent reduction on the placebo group.<sup>19</sup>
- TNF- $\alpha$  inhibitors: Conflicting results have been reported with the use of topical thalidomide. Thalidomide 1 percent paste was found to be as effective as dexamethasone 0.43 percent paste in the management of erosive OLP,<sup>20</sup> but a recent publication by O'Neill and Scully did not support the use of TNF- $\alpha$  inhibitors for the management of OLP.<sup>21</sup>

In summary, the first-line therapy for the management of oral lichen planus is a topical steroid, as previously noted. As the most common side effect of topical steroids in the oral cavity is an oral fungal infection, a preventive antifungal may also be used. If patients do not respond to topical steroids, therapies under the supervision of a trained clinician as described above can be considered.<sup>2</sup>

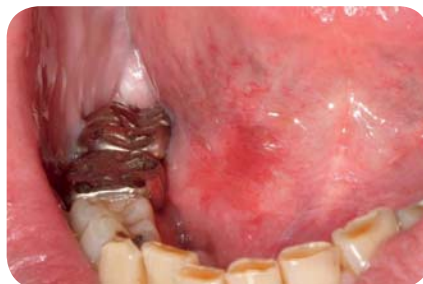#### **Oral Epithelial Dysplasia**

##### *Epidemiology*

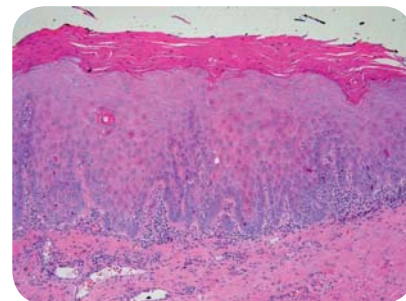
Oral epithelial dysplasia may present as a white, red or a mixed white and red lesion. Leukoplakia is the clinical term used for a white plaque of questionable risk only after exclusion of other diseases or disorders.<sup>22</sup> The estimated prevalence of oral leukoplakia is 2 percent and is more common in men and those who smoke.<sup>23</sup> It is important to note that the definition



**FIGURE 4.** Moderate dysplasia of the right lateral border of the tongue in a 68-year-old male.



**FIGURE 5.** Erythroplakic lesion of the floor of mouth in a 55-year-old male.



**FIGURE 6.** Hematoxylin and eosin stained section of oral mucosa exhibiting hyperparakeratosis and a disturbed pattern of maturation. The epithelium exhibits bulbous rete pegs and acanthosis. The keratinocytes exhibit dyskeratosis, increased number of mitoses, increased nuclear-to-cytoplasmic ratio, and focal nuclear hyperchromatism and pleomorphism. These changes involve the lower third to lower half of the epithelium. The basement membrane is focally effaced. The supporting connective tissues harbor a nonspecific chronic inflammatory cell infiltrate. This represents mild to moderate dysplasia.

of leukoplakia is widely used in the literature and has not been standardized. The etiology is unknown, although there are factors that increase the risk such as tobacco and alcohol use. The role of human papilloma virus is still being fully elucidated.<sup>24</sup> Dysplasia is a histopathologic diagnosis, occurring when the normal epithelium is replaced by keratinocytes that show atypical maturation, and it has a population estimate ranging from 1 to 2.5 percent.<sup>25</sup>

### Clinical Features

Leukoplakia can present on any intraoral site. It usually affects adults and is asymptomatic. The incidence increases with age. It can be divided into a homogenous type which is flat, thin and uniform in color (**FIGURE 4**) and a nonhomogenous type, which has both red and white characteristics (sometimes termed erythroleukoplakia or speckled leukoplakia).<sup>26</sup> Erythroplakia is the clinical term for a “fiery red patch that cannot be characterized clinically or pathologically as any other definable disease” (**FIGURE 5**).<sup>22</sup> These are relatively uncommon and more frequently present as an erythroleukoplakia. Leukoplakia can also have a more verrucous appearance, with a papillary texture and a higher risk of representing a malignant lesion. Many leukoplakias are a mixture of all different patterns. Leukoplakic lesions may show histologic dysplastic changes that extend beyond what was clinically defined as a lesion.<sup>27</sup>

### Diagnosis

Many attempts have been made recently to develop new techniques for the identification of potentially malignant and malignant conditions. Histopathological examination of a biopsy is the most reliable and desirable method. Other adjunctive techniques have been evaluated, including, but not limited to, the brush test, ViziLite, toluidine blue staining and VELscope.<sup>28–30</sup> See “Standard Examination and Adjunctive Techniques for Detection of Oral Premalignant and Malignant Lesions” beginning on page 329 for further discussion of these techniques.

### Histopathological Features

Most leukoplakic lesions when examined microscopically represent hyperkeratosis with or without acanthosis (**FIGURE 6**) and are likely the result of mucosal trauma (mechanical, thermal or chemical). The incidence of histological dysplasia in lesions that clinically are considered leukoplakia ranges between 5 and 25 percent.<sup>27</sup> The World Health Organization (WHO) 2005 classification identifies four histopathological stages, with the criteria used for each stage shown in **TABLE 1**.<sup>31</sup> There exists a histopathologic controversy relative to the spectrum of inflammation in a diagnosis of dysplasia, which can lead to lower inter- and intra-rater reliability of the level of dysplasia, as well as inadvertently classifying lichen planus with dysplastic features. **FIGURE 4** is a hematoxylin and eosin (H&E) stained example of mild to moderate dysplasia.

### Malignant Transformation of Oral Epithelial Dysplasia

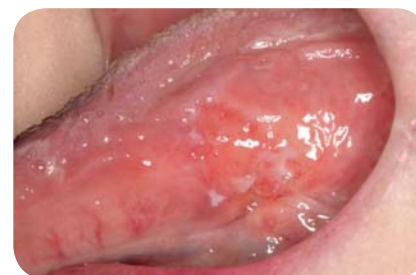The malignant transformation rate of oral epithelial dysplasia is variable (**FIGURE 7**). The annual transformation rate reported from one study from India was 0.3 percent.<sup>32</sup> A more recent study from Europe concluded that the annual transformation rate of oral leukoplakia is approximately 1 percent.<sup>33</sup> In studies between 1976 and 1984, the malignant transformation rate ranged between 0.13 percent and 17 percent.<sup>34</sup> This variation may have been related to different diagnostic criteria, different populations, presence of risk factors and the length of the observation period.

The incidence of malignant progression is higher in nonhomogenous leukoplakias and verrucous leukoplakias. There are some commonly recognized factors that increase the risk of transformation (**TABLE 2**).<sup>26</sup> In addition, several biomarkers, such as loss of heterozygosity (LOH), integrins and matrix metalloproteinases (MMPs), have been identified to increase the transformation rate.<sup>35</sup>

TABLE 1

**Histopathological Stages in Epithelial Premalignant Lesions<sup>31</sup>**

1	Mild dysplasia	The architectural and/or cytological atypia is limited to the lower third of the epithelium.
2	Moderate dysplasia	The architectural and/or cytological atypia extends into the middle third of the epithelium.
3	Severe dysplasia	The architectural and/or cytological atypical changes involve approximately two-thirds of the epithelium, but not the entire thickness.
4	Carcinoma in situ	Full thickness or almost full thickness cytological and/or architectural atypia, but no invasion of the neoplastic keratinocytes through the basement membrane into the supporting connective tissue.

**FIGURE 7.** Squamous cell carcinoma of the left lateral tongue in a 54-year-old female.**Management**

Scrutiny and removal of causative factors is an important approach to managing leukoplakic lesions. In the presence of possible etiologic factors, an arbitrary observation period between two and four weeks seems acceptable to observe a regression after elimination of such factors.<sup>25</sup> Although it might take longer for a lesion to regress, at least partial regression of the lesion after elimination of risk factors is desired. If no regression is observed, or if the compliance of the patient in eliminating risk factors is not complete, histological examination of the tissue is mandatory.

**Surgical Treatment**

It is hypothesized that the surgical removal of oral epithelial dysplasia may prevent the development of a squamous cell carcinoma. This is yet to be proven.<sup>36</sup> Different surgical techniques have been used, such as scalpel, laser and cryosurgery. Each has advantages and disadvantages. Recurrence is not uncommon with these types of lesions and may warrant surgical intervention.

**Medical Treatment**

To date, there is no evidence of effective medical/nonsurgical treatment in preventing the progression of

dysplastic lesions to squamous cell carcinoma.<sup>35</sup> Several agents have been used for the management of oral epithelial dysplasia. These included systemic vitamin A,<sup>37</sup> systemic beta carotene,<sup>38</sup> lycopene<sup>39</sup> and local bleomycin.<sup>40</sup> Two studies demonstrated small benefits for the systemic treatment with lycopene<sup>39</sup> and beta carotene<sup>38</sup> when compared with controls. Generally, the recurrence rates among those who initially responded to the treatment were high, and side effects were reported.<sup>41</sup>

**Conclusion**

Oral lichen planus and oral epithelial dysplasia are potentially malignant disorders. The etiology of both disorders is unknown, but certain risk factors and markers have been identified. The malignant transformation rate is relatively low in OLP, between 0 and 6 percent. The malignant transformation in oral epithelial dysplasia depends on the histopathologic degree of dysplastic changes and presence of known risk factors. Lycopene has shown some benefit for the medical treatment for dysplasia, and surgical excision has a role in the treatment strategy, but may not always stop the progression of oral epithelial dysplasia into carcinoma. ■■■■

TABLE 2

**Risk Factors for Malignant Transformation of Premalignant Oral Epithelial Lesions<sup>26</sup>**

Female gender
Long duration
Nonsmokers
Location: tongue and/or floor of mouth
Size > 200 mm <sup>2</sup>
Nonhomogenous type (erythroleukoplakia)
Presence of <i>Candida albicans</i>
Heavy alcohol consumption
Infection with high-risk HPV

**REFERENCES**

1. American Cancer Society, Cancer facts & figures 2009. American Cancer Society, 2009.
2. Al-Hashimi I, Schifter M, et al. Oral lichen planus and oral lichenoid lesions: diagnostic and therapeutic considerations. *Oral Surg Oral Med Oral Pathol Oral Radiol Endod* 103 Suppl:S25.e1-S25.e12, 2007.
3. Le Cleach L, Chosidow O. Clinical practice. Lichen planus. *N Engl J Med* 366:723-32, 2012.
4. Muller S. Oral manifestations of dermatologic disease: a focus on lichenoid lesions. *Head Neck Pathol* 5:36-40, 2011.
5. Bombeccari GP, Guzzi G, et al. Oral lichen planus and malignant transformation: a longitudinal cohort study. *Oral Surg Oral Med Oral Pathol Oral Radiol Endod*



112:328-34, 2011.

6. van der Meij EH, Mast H, van dW, I. The possible premalignant character of oral lichen planus and oral lichenoid lesions: a prospective five-year follow-up study of 192 patients. *Oral Oncol* 43:742-8, 2007.

7. Eisen D. The clinical features, malignant potential, and systemic associations of oral lichen planus: a study of 723 patients. *J Am Acad Dermatol* 46:207-14, 2002.

8. Carbone M, Arduino PG, et al. Course of oral lichen planus: a retrospective study of 808 northern Italian patients. *Oral Dis* 15:235-43, 2009.

9. Mattsson U, Jontell M, Holmstrup P. Oral lichen planus and malignant transformation: is a recall of patients justified? *Crit Rev Oral Biol Med* 13:390-6, 2002.

10. Gonzalez-Moles MA, Scully C, Gil-Montoya JA. Oral lichen planus: controversies surrounding malignant transformation. *Oral Dis* 14:229-43, 2008.

11. Shen ZY, Liu W, Zhu LK, Feng JQ, Tang GY, Zhou ZT. A retrospective clinicopathological study on oral lichen planus and malignant transformation: Analysis of 518 cases. *Med Oral Patol Oral Cir Bucal* 2012 May 1; Available at: [www.medicinaoral.com/pubmed/medoralv17\\_i6\\_p943.pdf](http://www.medicinaoral.com/pubmed/medoralv17_i6_p943.pdf).

12. Eisen D, Carrozzo M, et al. Number V Oral lichen planus: clinical features and management. *Oral Dis* 11:338-49, 2005.

13. Lozada-Nur F, Miranda C, Maliksi R. Double-blind clinical trial of 0.05% clobetasol propionate (corrected from propionate) ointment in orabase and 0.05% fluocinonide ointment in orabase in the treatment of patients with oral vesiculoerosive diseases. *Oral Surg Oral Med Oral Pathol* 77:598-604, 1994.

14. Gaeta GM, Serpico R, et al. Cyclosporin bioadhesive gel in the topical treatment of erosive oral lichen planus. *Int J Immunopathol Pharmacol* 7:125-32, 1994.

15. Becker JC, Houben R, et al. The carcinogenic potential of tacrolimus ointment beyond immune suppression: a hypothesis creating case report. *BMC Cancer* 6:7, 2006.

16. Lundquist G, Forsgren H, et al. Photochemotherapy of oral lichen planus. A controlled study. *Oral Surg Oral Med Oral Pathol Oral Radiol Endod* 79:554-8, 1995.

17. Fornaini C, Raybaud H, et al. New clinical approach for use of Er:YAG laser in the surgical treatment of oral lichen planus: a report of two cases. *Photomed Laser Surg* 30:234-8, 2012.

18. Mansourian A, Momen-Heravi F, et al. Comparison of aloe vera mouthwash with triamcinolone acetonide 0.1% on oral lichen planus: a randomized double-blinded clinical trial. *Am J Med Sci* 342:447-51, 2011.

19. Saawarn N, Shashikanth MC, et al. Lycopene in the management of oral lichen planus: a placebo-controlled study. *Indian J Dent Res* 22:639-43, 2011.

20. Wu Y, Zhou G, et al. A randomized double-blind, positive-control trial of topical thalidomide in erosive oral lichen planus. *Oral Surg Oral Med Oral Pathol Oral Radiol Endod* 110:188-95, 2010.

21. O'Neill ID, Scully C. Biologics in oral medicine: principles of use and practical considerations. *Oral Dis* 18:525-36, 2012.

22. Warnakulasuriya S, Johnson NW, van dW, I. Nomenclature and classification of potentially malignant disorders of the oral mucosa. *J Oral Pathol Med* 36:575-80, 2007.

23. Petti S. Pooled estimate of world leukoplakia prevalence: a systematic review. *Oral Oncol* 39:770-80, 2003.

24. Syrjanen S, Lodi G, et al. Human papillomaviruses in oral carcinoma and oral potentially malignant disorders: a systematic review. *Oral Dis* 17 Suppl 1:58-72, 2011.

25. Axell T, Pindborg JJ, et al. Oral white lesions with special reference to precancerous and tobacco-related lesions: conclusions of an international symposium held in Uppsala, Sweden, May 18-21 1994. International Collaborative Group on Oral White Lesions. *J Oral Pathol Med* 25:49-54, 1996.

26. van dW, I. Potentially malignant disorders of the oral and oropharyngeal mucosa; terminology, classification and present concepts of management. *Oral Oncol* 45:317-23, 2009.

27. Neville BW, Damm DD et al. Oral and maxillofacial pathology, 3rd ed., Saunders Elsevier, St. Louis, 2009.

28. Maeda K, Suzuki T, et al. Colorimetric analysis of unstained lesions surrounding oral squamous cell carcinomas and oral potentially malignant disorders using iodine. *Int J Oral Maxillofac Surg* 39:486-92, 2010.

29. Awan K, Yang Y, et al. Utility of toluidine blue as a diagnostic adjunct in the detection of potentially malignant disorders of the oral cavity—a clinical and histological assessment. *Oral Dis* 2012.

30. Awan KH, Morgan PR, Warnakulasuriya S. Evaluation of an autofluorescence based imaging system (VELscope) in the detection of oral potentially malignant disorders and benign keratoses. *Oral Oncol* 47:274-7, 2011.

31. Barnes L, Eveson JW et al. Pathology and genetics. Head and neck tumours, World Health Organization classifications of tumours, World Health Organization, 2005.

32. Gupta PC, Mehta FS, et al. Incidence rates of oral cancer and natural history of oral precancerous lesions in a 10-year follow-up study of Indian villagers. *Community Dent Oral Epidemiol* 8:283-333, 1980.

33. Scheifele C, Reichart PA. Is there a natural limit of the transformation rate of oral leukoplakia? *Oral Oncol* 39:470-5, 2003.

34. Amagasa T, Yamashiro M, Uzawa N. Oral premalignant lesions: from a clinical perspective. *Int J Clin Oncol* 16:5-14, 2011.

35. Brennan M, Migliorati CA, et al. Management of oral epithelial dysplasia: a review. *Oral Surg Oral Med Oral Pathol Oral Radiol Endod* 103 Suppl:519-2, 2007.

36. Angadi PV, Savitha JK, et al. Oral field cancerization: current evidence and future perspectives. *Oral Maxillofac Surg* 16:171-80, 2012.

37. Hong WK, Endicott J, et al. 13-cis-retinoic acid in the treatment of oral leukoplakia. *N Engl J Med* 315:1501-5, 1986.

38. Sankaranarayanan R, Mathew B, et al. Chemoprevention of oral leukoplakia with vitamin A and beta carotene: an assessment. *Oral Oncol* 33:231-6, 1997.

39. Singh M, Krishanappa R, et al. Efficacy of oral lycopene in the treatment of oral leukoplakia. *Oral Oncol* 40:591-6, 2004.

40. Epstein JB, Wong FL, et al. Topical bleomycin treatment of oral leukoplakia: a randomized double-blind clinical trial. *Head Neck* 16:539-44, 1994.

41. Lodi G, Porter S. Management of potentially malignant disorders: evidence and critique. *J Oral Pathol Med* 37:63-9, 2008.

**THE CORRESPONDING AUTHOR**, Michael T. Brennan, DDS, MHS, can be reached at [Mike.Brennan@carolinas.org](mailto:Mike.Brennan@carolinas.org).



## Take Advantage of Alberta's Strong Economy

Let's be honest. You didn't become a dentist so you could peruse spreadsheets all day. At Dental Choice, we're offering associate positions and ownership opportunities that let you focus on your strengths as a dentist. Leave the business part to us and we'll help you enjoy a better work/life balance: freeing you up to work hard and to better serve your patients. In addition, Alberta's economy is one of the strongest in Canada with many opportunities.

For more information about joining the Dental Choice team visit us at:

[www.SuccessfulDentists.ca](http://www.SuccessfulDentists.ca)

Positions available in  
Edmonton, Calgary and Airdrie



Twitter: @DentistSuccess  
[Dentists@dentalchoice.ca](mailto:Dentists@dentalchoice.ca)





# Human Papillomavirus: The Fundamentals of HPV for Oral Health Care Providers

KATHARINE CIARROCCA, DMD, MSED; LANA L. JACKSON, MD, PHARM, FACS;  
AND SCOTT S. DE ROSSI, DMD

**ABSTRACT** Human papillomavirus (HPV) has become widely known as the causative agent of cervical cancer and some oropharyngeal cancers. The development of HPV vaccines has further piqued public interest. As a result, dentists will have increasing numbers of patients who will inquire about oral HPV infection and its prevention by means of vaccination. Dental professionals must be informed. This review provides an overview of HPV, its association with HIV and oropharyngeal cancer and information on HPV vaccinations.

## AUTHORS

**Katharine Ciarrocca, DMD, MSED**, is an assistant professor in the Department of Oral Health and Diagnostic Sciences at Georgia Regents University, College of Dental Medicine.  
*Conflict of Interest*  
*Disclosure: None reported.*

**Scott S. De Rossi, DMD**, is an associate professor of Oral Medicine and chairman of Oral Health and Diagnostic Sciences at Georgia Regents University, College of Dental Medicine.  
*Conflict of Interest*  
*Disclosure: None reported.*

**Lana L. Jackson, MD, PHARM, FACS**, is an assistant professor of Otolaryngology/Head and Neck Surgery at Georgia Regents University and director of the interprofessional Head and Neck Cancer Tumor Board.  
*Conflict of Interest*  
*Disclosure: None reported.*

Within the last 10 years, it has become evident that human papillomavirus (HPV) not only causes cervical and anal cancers, but also causes a subset of head and neck squamous cell carcinomas (HNSCCs). This increased awareness has subsequently amplified interest in a more specific knowledge regarding oral HPV infections. Dental patients may inquire about their risk of infection, their risk of developing a malignancy and even if there is potential protection in commonly used HPV vaccines. In addition, salivary diagnostic tests are commercially available for HPV, and dentists need to understand the sensitivity and specificity of those tests to determine clinical utility. Therefore, it is incumbent upon dental professionals

to be educated on the fundamentals of HPV and to be capable of counseling patients appropriately as a comprehensive approach to preventive oral health care.

## The Basics of HPV Acquisition and Diagnosis Classification

Papillomaviruses are small, double-stranded DNA viruses that infect the stratified epithelium (basal cells) of the skin or mucous membranes. The human papillomavirus is a member of the *Papillomavirus* genus of the family of Papovaviridae.<sup>1,2</sup> Human papillomavirus is a DNA virus that can cause lesions anywhere on the cutaneous surface, including the extremities, genitalia and oral mucosa. Lesions involving the oral cavity can be transmitted sexually or by patient nail-biting with periungual warts.

Based on their DNA, more than 120 specific types have been fully cloned and characterized.<sup>2</sup> Furthermore, classification of HPVs as high-risk types and low-risk types is based on epidemiologic data regarding the behavior of the lesions caused by different HPV types.<sup>3</sup> To date, investigators have identified 30 HPV genotypes: 15 high-risk types, three types that probably are high risk and 12 low-risk types.<sup>1-3</sup> Low-risk types of HPV cause benign oral hyperplasias that usually are painless and nonulcerated. High-risk types HPV-16 and HPV-18 are associated with approximately 70 percent of cervical cancers, whereas HPV-16 alone is associated with about 85-95 percent of HPV-positive oropharyngeal cancers.<sup>4,5</sup>

### Acquisition of Oral HPV Infection

Infectious HPV is spread most often via sexual contact; however, it is unclear whether HPV can be casually transmitted to the oral cavity. Oral sex has been hypothesized to be the main transmission mode of HPV infection.<sup>5</sup> Oral HPV infection is uncommon in children, despite reports that it can also be spread through passage through the cervical canal during delivery.<sup>5,6</sup> Autoinoculation is also possible, but very uncommon, as evidenced by lack of concordance of oral and cervical HPV infections.<sup>7</sup>

Several other risk factors have been consistently associated with increased odds of prevalent oral HPV in cross-sectional studies.<sup>6-9</sup> Current smoking and HIV infection are both associated with significantly increased oral HPV prevalence, suggesting that tobacco-related and HIV-related immunosuppression may impact oral HPV natural history.<sup>8</sup> In addition, oral HPV prevalence also appears to increase with older age, which is unusual for a sexually transmitted infection. Speculation on possible causes of this pattern includes decreased oral HPV clearance with older age or age-related changes in the immune system.<sup>8</sup>

### Diagnosis of Oral HPV Infection

Human papillomavirus infection can be identified through various measures, such as the detection of HPV DNA in biopsy specimens, detection of serum antibodies to HPV proteins and the detection of HPV DNA in oral specimens.<sup>9-13</sup> Archival cytology slides can be used for HPV DNA detection with *in situ* hybridization (ISH).<sup>13</sup> Presence of HPV DNA by ISH in metastatic lesions from HNSCC using alcohol-fixed, archival, cytopathological material was studied

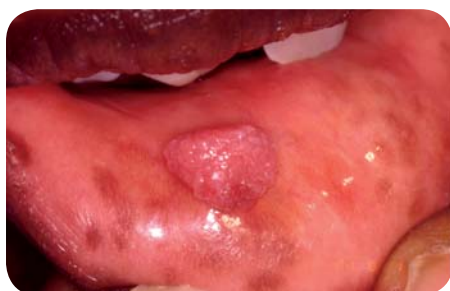**AUTOINOCULATION**  
is also possible, but very  
uncommon, as evidenced by  
lack of concordance of oral and  
cervical HPV infections.

by Umudum et al., and the cytologic features of HPV-positive metastatic lesions of HNSCC were characterized; HPV DNA and origin of metastatic lesions were correlated.<sup>9</sup> The prevalence of HPV DNA in cancer specimens, however, varies greatly based on tumor site and geographic variability in risk factors. Recent studies suggest that HPV is more likely to be detected in oropharyngeal cancers than in oral cancers.<sup>10,11</sup>

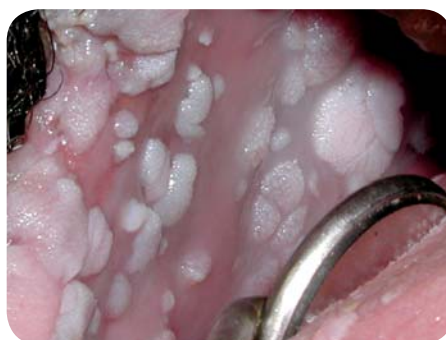Serum antibodies have been used as a marker of cumulative exposure to HPV.<sup>13</sup> Several studies show strong associations between serum HPV and oropharyngeal cancers, and weak associations with oral and laryngeal cancers.<sup>9-13</sup> Studies of seroprevalence of HPV demonstrate exposure to HPV but do not specify the mucosal site of infection. In addition,

seroprevalence likely shows cumulative exposure to HPV, but not all individuals develop an antibody response, and HPV antibodies diminish over time, making the clinical utility of this in predicting cancer risk yet to be determined. Detection of HPV DNA in oral specimens likely indicates current oral HPV infection.<sup>12</sup> However, this begs the question, "Does saliva-based HPV testing establish cancer risk and guide patient management?"

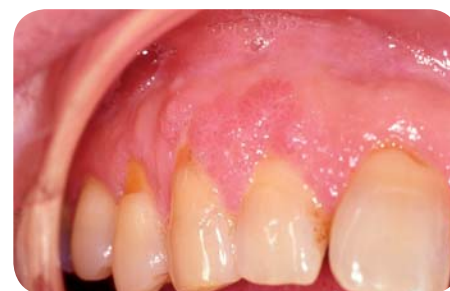It is estimated that 20 million Americans are currently infected with HPV and 6 million new infections occur annually.<sup>3</sup> Fifty percent of sexually active adults will be infected in their lifetime, and 33,000 will develop an HPV-associated malignancy (12,000 will be HNSCC). The rationale and need for screening tests is clear; however, methods for collecting exfoliated cells (e.g., saliva, swab, oral rinse) have not been standardized, and oral rinses cannot determine the origin of HPV infection. It is vital to establish the significance of this relationship between presence of HPV and cancer risk in the oral cavity and oropharynx. This is made difficult as the clinical spectrum of HPV-associated premalignant lesions has not been fully described, and there are no unique clinical features of HPV-associated premalignant lesions. HPV-related HNSCC develops in hard-to-examine locations (e.g., tonsillar crypts) making early clinical detection challenging. How can we identify patients who are at risk for harboring an HPV-associated premalignant lesion of HNSCC? Saliva-based HPV testing has been developed by OralDNA Labs. According to the manufacturer, the test is ideal for patients with traditional risk factors for oral cancer, with signs and symptoms of oral cancer, for those who are sexually active and for those with suspicious lesions.<sup>12</sup> Serious questions



**FIGURE 1.** Squamous papilloma on the lower labial mucosa in a 34-year-old, otherwise healthy, male. (Courtesy of Scott De Rossi, DMD.)



**FIGURE 2.** Focal epithelial hyperplasia on buccal mucosa. (Courtesy of Scott De Rossi, DMD.)



**FIGURE 3.** Condyloma acuminatum on anterior gingiva. (Courtesy of Scott De Rossi, DMD.)

remain regarding this technology: Will my patient develop HNSCC if he or she has a positive test? What should I do for my patient if he or she has a positive test? In order to establish management protocols and to determine the utility of community-based HPV screening, more research is necessary.<sup>12</sup>

## HPV and Oral Mucosa

### Benign Lesions

Low-risk HPV genotypes are often responsible for benign oral mucosal lesions such as ordinary warts (verrucae), condylomas, focal epithelial hyperplasia (FEH) and squamous papillomas. The most common low-risk genotypes are HPV-6 and HPV-11. The skin types HPV-2, HPV-4 and HPV-57 have been found in oral wart lesions.<sup>13,14</sup>

**Squamous papilloma.** Squamous papillomas are the most common benign neoplasm of the oral mucosa with a predilection for the mucosa of the hard and soft palate including the uvula and the vermillion of the lips.<sup>13</sup> A harmless lesion that is neither transmissible nor threatening, the lesion raises concern because of its clinical appearance, which may mimic exophytic carcinoma, verrucous carcinoma or condyloma acuminatum. Oral papillomas can be recognized by their small, fingerlike projections, resulting in an exophytic lesion with a rough or cauliflower-like, verrucous surface (**FIGURE 1**) that is often white. Squamous papilloma lesions are

thought to be induced by HPV-6 or HPV-11.<sup>13</sup> All lesions resembling a squamous papilloma are recommended for excision at the base with a 1-mm margin to the depth of the submucosa, and removal should be considered the cure. Recurrence or appearance of new lesions suggests the possibility of retransmission of a condyloma acuminatum or a carcinoma.

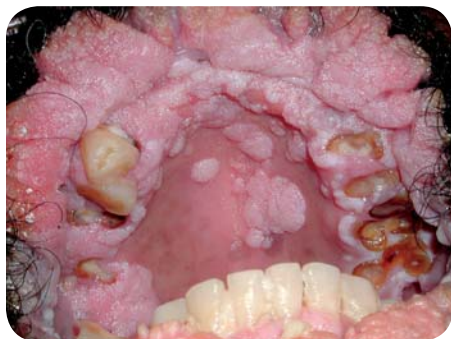**Verruca vulgaris.** Also known as the common wart, verruca vulgaris is the most prevalent HPV skin lesion, but it can also be found in the oral cavity. This lesion is usually associated with HPV-2 and HPV-4.<sup>14</sup> In the oral cavity, verruca vulgaris is most often found on keratinized mucosa, namely the gingiva and palate. Verruca vulgaris lesions are contagious, and autoinoculation does occur. Verruca vulgaris lesions rapidly enlarge (average size < 5 mm) and then remain unchanged, sometimes for several years. Often times, it is difficult to differentiate clinically between a verruca vulgaris lesion and a squamous papilloma; however, the treatment is the same (surgical excision).

**Focal epithelial hyperplasia.** Focal epithelial hyperplasia (FEH), also known as Heck's disease, is a rare, benign lesion associated with HPV-13 and HPV-32 and was originally diagnosed in the Inuit population.<sup>15-17</sup> Factors that have been associated with the disease include communal lifestyle, poor hygiene and poverty. FEH frequently affects children but is increasingly seen in the HIV-positive population, as well.<sup>16,17</sup> This lesion

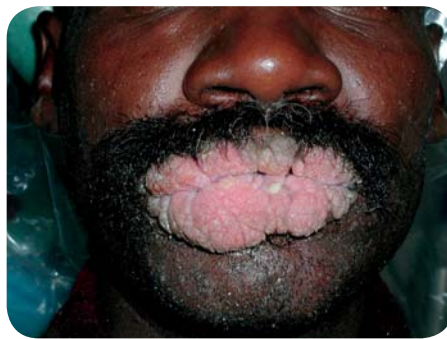
is typically located in the labial, buccal and lingual mucosa and is characterized by multiple soft, circumscribed, sessile nodules that usually resemble the normal mucosal color, but may occasionally appear white and papillary (**FIGURE 2**). The lesions often persist for months or even years and spontaneously resolve with no treatment. The risk of recurrence is minimal.

**Condyloma acuminatum.** Normally, condyloma acuminatum lesions are found in the genital area and are considered a sexually transmitted disease. Oral condylomas do occur, however, and are associated with HPV-2, HPV-6 and HPV-11.<sup>14</sup> Clinically, these lesions are similar in appearance to papillomas but are usually larger and more clustered. In addition, condylomas are known to be more diffuse and deeply rooted than papillomas. These lesions are most commonly found on the labial mucosa, soft palate and lingual frenum. Condylomas in the oral cavity are usually related to oral-genital contact but can rarely occur because of autoinoculation or as a result of maternal transmission (**FIGURE 3**). When these lesions are diagnosed in children, the examining clinician should be aware that their presence may be an indication of sexual abuse, thus necessitating intervention with the proper authorities. Condylomas are difficult to treat, and very often cause scarring and disfigurement. It is best to surgically remove all of the lesions simultaneously to lessen the probability of autoinoculation. Excision with lasers





**FIGURE 4.** Palatal view of aggressive condyloma acuminatum in HIV-positive patient. (Courtesy of Scott De Rossi, DMD.)



**FIGURE 5.** Aggressive condyloma acuminatum in HIV-positive patient. (Courtesy of Scott De Rossi, DMD.)

may lead to spreading of the virus via airborne particles and is not advised. Podofilox (Condylox, Watson Pharma, Parsippany, N.J.), an antimitotic topical agent used to treat genital and anal condylomas, has not been approved by the FDA for oral use but may be effective in treating oral condylomas.

#### HIV and HPV

HPV-related diseases are increased in the oral cavity of HIV-positive individuals. HIV carriers have more frequent infections and a wider variety of HPV types, in addition to an increased frequency of HPV-associated oral lesions (FIGURES 4 AND 5). Additionally, studies have demonstrated an increase in the incidence of oral warts related to HPV infection since the advent of antiretroviral therapy.<sup>16-18</sup> Compared with immunocompetent patients, immunocompromised patients often present with HPV infections that are atypical or more extensive, recurrent and recalcitrant to therapy. While no specific association between warts and highly active retroviral treatment was found, a significant reduction in viral load in the previous six months was related to an increased incidence of oral warts.<sup>16,17</sup> It has been suggested that this phenomenon of increasing incidence of oral warts associated with a decreasing viral load may represent a form of immune reconstitution syndrome.<sup>16-18</sup>

#### HPV and Oropharyngeal Cancer

Cancers of the head and neck arising from the mucosa lining the oral cavity, oropharynx, hypopharynx, larynx, sinonasal tract and nasopharynx represent a considerable burden worldwide, being the fifth most common cancer in 2008.<sup>18,19</sup> Tobacco use and alcohol consumption are known risk factors for many of these cancers,<sup>19,20</sup> but more recently HPV infection has been found to be strongly associated with oropharyngeal cancer.<sup>21</sup>

There are epidemiological differences between HPV-DNA-positive and HPV-DNA-negative head and neck cancers. HPV-DNA-positive cancers are associated with younger age and higher numbers of sexual partners, but are less associated with tobacco smoking as compared with HPV-DNA-negative cancers.<sup>22,23</sup> The proportion of head and neck cancers that are HPV-DNA positive varies considerably. A recent systematic review found that the average HPV-DNA positivity was 35.6 percent for oropharyngeal cancer and 23.5 percent for oral cavity cancer.<sup>24</sup> Nevertheless, this review classified all tongue cancers as oral cavity cancers and did not differentiate between base of tongue (classified anatomically as an oropharyngeal site) and surface and border of tongue (classified anatomically as an oral cavity site).<sup>24</sup> HPV-DNA positivity varies by site and is highest in the tonsil and base of tongue.<sup>25</sup>

This review may have underestimated oropharyngeal cancer HPV-DNA positivity and overestimated oral cavity cancer positivity. This review also showed that there is substantial variation in the proportion of HPV-DNA-positive cancers by country and study; part of this may be due to the different distributions of risk factors other than HPV infection (such as tobacco consumption) as well as to the accuracy of cancer site classification. Although the incidence of head and neck cancers associated with tobacco and alcohol consumption has decreased considerably in the developed world, that of oropharyngeal cancers has increased.<sup>19,26,27</sup> Given the etiological role of HPV in some oropharyngeal cancers, it is possible that the incidence of these cancers may decline after HPV vaccination.<sup>23</sup>

The epidemiology of HNSCC has changed over the past 20 years. As tobacco use, historically the most significant risk factor for HNSCC, has decreased in the United States, the incidence of tobacco-associated but HPV-unrelated HNSCC has also decreased.<sup>26,27</sup> Comparatively, the incidence of HPV-associated oropharyngeal cancers overall is increasing.<sup>28,29</sup> Alcohol and smoking are the primary risk factors for head and neck carcinomas.<sup>19</sup> The fact that 15 percent to 20 percent of patients develop HNSCC in the absence of exposure to these agents or without any obvious predisposing genetic defects strongly suggests the possibility of other risk factors, including the presence of HPV. Although certain subsets of HNSCC have become less prevalent with the decrease in smoking, rates of oropharyngeal cancers — particularly tongue and tonsillar cancers — have risen steadily among men and women aged 20 to 44.<sup>28</sup>

In HNSCC, there are now two definitive subgroups: those associated with HPV and those not associated with HPV. The latter are associated with long-standing use of tobacco and alcohol. However, investigators have shown that tobacco and alcohol use increases the risk not only of developing HPV-independent HNSCCs but also of developing HPV-associated HNSCCs.<sup>21,22</sup> HPV-associated HNSCCs are histologically less differentiated and usually at a higher tumor stage than are HPV-independent HNSCCs.<sup>26</sup>

The possible link between certain HPV types and oral and oropharyngeal carcinomas is of great interest to clinicians. HPV has a clearly defined role in almost all cases of cervical cancer, and the similar morphologic features of genital and oral HPV-associated lesions was one of the early findings that suggested HPV might be involved in oral and laryngeal squamous cell carcinomas. HPV-16 and HPV-18 are the most commonly detected high-risk types. In most studies, HPV DNA has been found in 25 percent to 35 percent of oral carcinomas.<sup>25</sup>

The likelihood of detecting HPV increases with the progression from normal mucosa to premalignant lesions to oral cancer. HPV is two to three times more likely to be observed in precancerous oral mucosa and 4.7 times more likely to be found in oral squamous cell carcinoma than in normal mucosa.<sup>29</sup> HPV may play a more important role in some tumors than in others. For example, HPV-related cancers arise mainly from the tonsils and base of the tongue rather than the ventrolateral tongue, gingivae, cheek, palate and floor of the mouth.<sup>29</sup>

The risk of developing an HPV-associated oropharyngeal carcinoma is

directly related to the number of lifetime sexual partners (oral and vaginal), young age at first sexual activity and a history of same-sex partners.<sup>25</sup> HPV-positive carcinomas are usually detected as later-stage disease with regional lymph node involvement and metastasis as compared to HPV-negative cancers.<sup>30</sup> Yet, despite the later stage at diagnosis, HPV-positive carcinomas of the head and neck have higher survival rates, better response to radiation therapy and chemotherapy, and are less likely to progress or recur.<sup>21,22,25</sup>

### THE TOPICAL USE of cidofovir appears to cause significant shrinkage and resolution of gingival HPV recalcitrant to traditional therapies.

Although HPV status may prompt less aggressive treatment strategies, no clinical trials have been published to date that confirm that modifying cancer therapy based on HPV status can improve patients' outcomes.

#### Treatment and Prevention

Current treatment of HPV infections depends on the area involved and the extent of the lesions, but can include surgical excision, laser ablation, cryosurgery, immunostimulants (e.g., interferon) and application of caustic agents (e.g., podophyllotoxin, retinoic acid). With HPV recurrence, however, these various treatments often fail. Even if success is achieved, recurrences are common. Over the last few years, new and exciting information has been

elucidated regarding novel pharmacologic approaches in the treatment of viral diseases.<sup>31-37</sup> Cidofovir, a nucleoside analog to deoxycytidine monophosphate, is effective against a number of DNA viruses including recurrent herpes viruses, Kaposi sarcoma, molluscum contagiosum and HPV-related skin lesions. The topical use of cidofovir appears to cause significant shrinkage and resolution of gingival HPV recalcitrant to traditional therapies.<sup>31</sup>

Currently in the United States, two commercially available prophylactic HPV vaccines are available: a bivalent (HPV-16 and HPV-18) vaccine (Cervarix, GlaxoSmithKline, Brentford, Middlesex, England) and a quadrivalent (HPV-6, HPV-11, HPV-16 and HPV-18) vaccine (Gardasil, Merck, Whitehouse Station, N.J.). The quadrivalent vaccine was first licensed in 2006 for use in females ages 9-26 for the prevention of cervical, vaginal and vulvar cancers.<sup>32</sup> In 2009, the license was expanded to include males in this age range because clinical trial data demonstrated the vaccine's efficacy in preventing genital warts in both genders.<sup>32</sup> Research as of late has demonstrated the vaccine to provide effective prevention against anal precancers, therefore expanding the vaccine's clinical indications to include anal cancer prevention.<sup>33,34</sup> In addition, clinical trials of this vaccine have revealed very high vaccine efficacy (> 98 percent) for the prevention of anal, cervical, vaginal and vulvar precancers among vaccine-type-naïve individuals.<sup>35,36</sup> As would be expected, efficacy is lower (50 to 78 percent) when analyses also include individuals already infected with vaccine-type HPV at the time of vaccination.<sup>36</sup>

The second HPV vaccine, Cervarix, is a bivalent vaccine that provides protection against HPV-16 and HPV-18. This vaccine was licensed for use

in the U.S. in 2009 for the prevention of cervical cancers.<sup>37</sup> Genital warts protection is not conferred from this vaccine because it does not contain low-risk HPV types associated with this disease. At the moment, however, the accepted indications for the bivalent vaccine are only cervical cancer and its precursors.

HPV vaccines have a clear role in preventing many anogenital cancers and conditions related to HPV infection. Overall, the high efficacy of the vaccines and excellent safety profile suggest that these vaccines will provide major health benefits to the population. More data needs to be established on the effectiveness of these vaccines against HPV-related head and neck cancer. In addition, further research needs to be performed to evaluate the long-term efficacy of the vaccine against both anogenital and nonanogenital endpoints. When this information is available, it is likely that an even greater benefit from these vaccines will be realized.

It is unclear how effective traditional visual and tactile examinations are in screening for oropharyngeal cancers. Oropharyngeal cancers are likely to be less visible and share many symptoms with benign conditions such as tonsillitis and pharyngitis. Oral health care providers need to perform comprehensive oral and head and neck examinations including lymph node examination and be on alert for symptoms that may suggest a malignancy, such as dysphagia, otalgia, unexplained weight loss and hemoptysis. Currently, there is no evidence that detection of high-risk HPV is useful to predict the development of oropharyngeal cancer or disease in the oral cavity accurately.

## Conclusion

HPV has gained much interest recently among the dental community because of its accepted association with cervical cancer, the morphologic similarity of cervical warts to oral warts and the development of effective vaccination against anogenital HPV disease. Oral HPV infections have not been studied to the degree of those of the genital tract, although the evidence of association between certain tumors and HPV infection today is indisputable. Oncogenic HPVs are associated with oral malignancies, but its prevalence varies widely in different studies. Oral HPV infections need to be studied and investigated thoroughly so the resulting information can help to direct oral health professionals for future cancer prevention programs, including oral HPV vaccination for oral HPV infections. ■■■■

## REFERENCES

1. de Villiers EM, Fauquet C, Broker TR, Bernard HU, zur Hausen H. Classification of papillomaviruses. *Virology* 2004; 324 (1): 17-27.
2. Bernard HU, Burk RD, Chen Z, VAN Doorslaer K, Hausen H, de Villiers EM. Classification of papillomaviruses based on 189 PV types and proposal of taxonomic amendments. *Virology* 2010; 301 (1): 70-79.
3. Rautava J, Syrjänen S. Human papillomavirus infections in the oral mucosa. *JADA* 142(8) August 2011: 903-914.
4. Chaudhary AK, Singh M, Sundaram S, Mehrotra R. Role of human papillomavirus and its detection in potentially malignant and malignant head and neck lesions: Updated review. *Head Neck Oncol* 2009;1:22.
5. D'Souza G, Agrawal YJH, et al. Oral sexual behaviors associated with prevalent oral human papillomavirus (HPV) infection. *J Infect Dis* 2009;199:1-7.
6. Saini R, Khim TP, Rahman SA, et al. High-risk human papillomavirus in the oral cavity of women with cervical cancer, and their children. *Viol J* 2010;7:131.
7. Termine N, Giovannelli L, Matranga D, et al. Oral human papillomavirus infection in women with cervical HPV infection: new data from an Italian cohort and a metanalysis of the literature. *Oral Oncol* 2011;47:244-250.
8. D'Souza G, Fakhry C, Sugar EA, et al. Six-month natural history of oral versus cervical human papillomavirus infection. *Int J Cancer* 2007;121:143-150.
9. Umudum H, Rezanko T, Dag F, Dogruluk T. Human papillomavirus genome detection by in situ hybridization in fine-needle aspirates of metastatic lesions from head and neck squamous cell carcinomas. *Cancer* 2005; 105 (3): 171-177.
10. D'Souza G, Kreimer AR, Viscidi R, et al. Case-control study of human papillomavirus and oropharyngeal cancer. *New Engl J Med* 2007;356:1944-1956.
11. Fakhry C, D'Souza G, Sugar E, et al. Relationship between prevalent oral and cervical human papillomavirus infections in human immunodeficiency virus-positive and -negative women. *J Clin Microbiol* 2006;44:4479-4485.
12. OralDNA Labs www.oraldna.com.
13. Carneiro T, Marinho SA, Verli FD, Mesquita ATM, Lima NL, Miranda JL (2009). Oral squamous papilloma: clinical, histologic and immunohistochemical analyses. *J Oral Sci*, 51(3): 367-372.
14. Kumaraswamy KL, Vidhya M. Human papilloma virus and oral infections: An update. *J Can Res Ther* 2011;7:120-7.
15. Durso BC, Pinto JM, Jorge J Jr, de Almeida OP. Extensive focal epithelial hyperplasia: case report. *J Can Dent Assoc* 2005; 71(10):769-71.
16. Fakhry C, Sugar E, D'Souza G, et al. Two-week versus six-month sampling interval in a short-term natural history study of oral HPV infection in an HIV-positive cohort. *PLoS One* 2010;5:e11918.
17. Kreimer AR, Alberg AJ, Daniel R, et al. Oral human papillomavirus infection in adults is associated with sexual behavior and HIV serostatus. *J Infect Dis* 2004;189:686-698.
18. Marur S, D'Souza G, Westra WH, et al. HPV-associated head and neck cancer: a virus-related cancer epidemic. *Lancet Oncol* 2010;11(8):781-789.
19. Lubin JH, Gaudet MM, Olshan AF, Kelsey K, Boffetta P, Brennan P, et al. Body mass index, cigarette smoking, and alcohol consumption and cancers of the oral cavity, pharynx, and larynx: modeling odds ratios in pooled case-control data. *Am J Epidemiol* 2010; 171(12): 1250-1261.
20. Pierce JP, Messer K, White MM, et al. Prevalence of heavy smoking in California and the United States, 1965-2007. *JAMA* 2011;305:1106-1112.
21. Gillison ML, Koch WM, Capone RB, et al. Evidence for a causal association between human papillomavirus and a subset of head and neck cancers. *J Natl Cancer Inst* 2000;92:709-720.
22. Gillison ML, Chaturvedi AK, Lowy DR. HPV prophylactic vaccines and the potential prevention of noncervical cancers in both men and women. *Cancer* 2008;113:3036-3046.
23. Heck JE, Berthiller J, Vaccarella S, et al. Sexual behaviours and the risk of head and neck cancers: a pooled analysis in the International Head and Neck Cancer Epidemiology (INHANCE) consortium. *Int J Epidemiol* 2010;39:166-181.
24. Kreimer AR, Clifford GM, Boyle P, et al. Human papillomavirus types in head and neck squamous cell carcinomas worldwide: a systematic review. *Cancer Epidemiol Biomarkers Prev* 2005;14:467-475.
25. Gillison ML, D'Souza G, Westra W, et al. Distinct risk factor profiles for human papillomavirus type 16-positive and human papillomavirus type 16-negative head and neck cancers. *J Natl Cancer Inst* 2008;100:407-420.
26. Chaturvedi A, Engels E, Pfeiffer R, et al. Human papillomavirus (HPV) and rising oropharyngeal cancer incidence and survival in the United States. *J Clin Oncol* 2011;29.
27. Ryerson AB, Peters ES, Coughlin SS, et al. Burden of potentially human papillomavirus-associated cancers of the oropharynx and oral cavity in the US, 1998-2003. *Cancer*

2008;113:2901-2909.

28. Auluck A, Hislop G, Bajdik C, et al. Trends in oropharyngeal and oral cavity cancer incidence of human papillomavirus (HPV)-related and HPV-unrelated sites in a multicultural population: the British Columbia experience. *Cancer* 2010;116:2635-2644.

29. Cleveland CL, Junger ML, Saraiya M, Markowitz LE, Dunne ER, Epstein JB. The connection between human papillomavirus and oropharyngeal squamous cell carcinomas in the United States: implications for dentistry. *JADA* 142(8) August 2011: 915-924.

30. Watson M, Saraiya M, Benard V, Coughlin SS, Flowers L, Cokkinides V, Schwenn M, Huang Y, Giuliano A. Burden of cervical cancer in the United States, 1998-2003. *Cancer* 2008 Nov 15;113(10 Suppl):2855-64.

31. De Rossi SS, Laudenbach J. The management of oral human papillomavirus with topical cidofovir: A case report. *Cutis* 2004; 73:191-193.

32. U.S. Food and Drug Administration, b. Gardasil approved to prevent anal cancer. Available at: [www.fda.gov/NewsEvents/Newsroom/PressAnnouncements/2010/ucm237941.htm](http://www.fda.gov/NewsEvents/Newsroom/PressAnnouncements/2010/ucm237941.htm). Accessed Jan. 2, 2011.

33. Giuliano AR, Palefsky JM, Goldstone S, et al. Efficacy of quadrivalent HPV vaccine against HPV Infection and disease in males. *New Engl J Med* 2011;364:401-411.

34. Centers for Disease Control Prevention (CDC) FDA licensure of quadrivalent human papillomavirus vaccine (HPV4, Gardasil) for use in males and guidance from the Advisory Committee on Immunization Practices (ACIP) *MMWR Morb Mortal Wkly Rep* 2010b;59:630-632.

35. Garland SM, Smith JS. Human papillomavirus vaccines: current status and future prospects. *Drugs* 2010;70:1079-1098.

36. Lu B, Kumar A, Castellsague X, et al. Efficacy and safety of prophylactic vaccines against cervical HPV infection and diseases among women: a systematic review & meta-analysis. *BMC Infect Dis* 2011;11:13.

37. U.S. Food and Drug Administration. FDA News Release: FDA approved new vaccine for prevention of cervical cancer. [www.fda.gov/NewsEvents/Newsroom/PressAnnouncements/2009/ucm187048.htm](http://www.fda.gov/NewsEvents/Newsroom/PressAnnouncements/2009/ucm187048.htm). Accessed Nov. 30, 2009.



**Timothy G. Giroux**  
DDS/Broker

## ASK THE BROKER

### Question:

**I'm thinking about selling my practice and am concerned about keeping it confidential from my staff, patients & local dentists. How do I do that?**

We take great pride in protecting your privacy and keeping your sale confidential. We have all interested buyers sign a detailed Confidentiality Agreement before releasing any pertinent information. Every email from our office containing pertinent information has a bold warning that restates the importance of confidentiality and warns the recipient about contacting the doctor, office or sharing any information with anyone. Our office staff is very diligent in stressing how the process works. The brokers also reiterate not only the confidentiality process but also the expectations and conduct of the buyer in their exploration and research of the practice.

Fortunately, it is very rare that the "cat gets out of the bag". Sometimes a seller's office will receive a notice from a PPO company stating that a new doctor will be practicing at that location! In those instances, the Seller was close to announcing to the staff anyway. We still prefer to do that on our own terms. There are times when a buyer just ignores our admonition and calls the office or stops in to ask questions. We generally remove those buyers from our Data Base of active prospects after a thorough reprimand. Fortunately, most buyers are professional and it does not happen often.

I am often surprised how many sellers try to sell their practices on their own by revealing it to their dental supply representative or dental lab personnel. This is the surest way to announce to the entire dental community in the area that the practice is on the market. Most of the dental supply reps and lab personnel have stronger relationships with the dental staff than they do with the dentists. Once the word is out in the dental staff community, who knows how many more staff or patients may find out about the potential office sale.

There are some occasions when the selling doctor wishes to inform his staff about his plans early on in the process. Depending on the relationship with the staff, this can sometimes make the broker's job easier.

**Maintaining good relationships with your staff is crucial. Once the staff suspects the doctor is selling, generally it is best to inform the staff about the decision rather than denying the inevitable. An experienced broker can help the doctor decide the best course of action based on the doctor's individual needs.**

**Timothy G. Giroux, DDS** is currently the Owner & Broker at **Western Practice Sales** ([westernpracticesales.com](http://westernpracticesales.com)) and a member of the nationally recognized dental organization, ADS Transitions. You may contact **Dr Giroux** at: [wps@succeed.net](mailto:wps@succeed.net) or 800.641.4179



# Specializing in the Selling and Appraising of Dental Practices



**CALIFORNIA  
PRACTICE SALES INC.**

Serving California Since 1974

**"Your local Southern  
California Broker"**

Phone: (714) 639-2775

(800) 697-5656

Fax: (714) 771-1346

Email: jknipf@aol.com

rpalumbo@calpracticesales.com

WWW.CALPRACTICESALES.COM



*John Knipf & Robert Palumbo*

## LOS ANGELES COUNTY

**BURBANK** (Ortho) - 45 yrs gdwill. Consists of 2 chairs in open bay w/ Pano/Ceph in 1,221 sqft ste. Grossed ~\$292K in 2012. ID #4047.  
**CULVER CITY** - Leasehold & Equip Only! 10 eq op office in a single story bld. In residential area. Heavy traffic flow. ID #4261.  
**GLENDALE** (GP) - Turn-Key office located in 2 story Med/Dent bldg w/ 3 eq ops. Grossed approx. \$392K in 2012. ID# 4293. **SOLD**  
**HUNTINGTON PARK** (GP) Established in 2008. In a 2 story free stranding bldg near residential area. Has 4 eq ops. ID#4295.  
**LONG BEACH** (Ortho) - 46 yrs of goodwill. Located in a 3 story medical bldg. 4 chairs in open bay. In residential area. ID # 4255.  
**LONG BEACH** (Ortho) - Three practices as one entity. Have approx. 300 active patients. Has over 50 yrs of goodwill. ID#4285.  
**N. HOLLYWOOD** (GP/ORTHO) - Over 14 years of goodwill located in Prof. Bldg. Consists of 4 ops. Monthly revenues ~\$32K. ID#4265.  
**TARZANA** (GP) - Fee for service practice w/ over 28 yrs of goodwill. Consists of 8 eq ops and 2 plmbd not eq. ID #4313.  
**SANTA MONICA** (GP) - Fee for service practice located in 4 story med/dent bldg with over 30 years of goodwill. ID #4297  
**W. HOLLYWOOD** (GP) Modern designed office w/ 3 eq ops. 48 yrs of goodwill. 100% cash. Monthly revenues of \$83K/mo. ID #4153

## ORANGE COUNTY

**FOOTHILL RANCH** - Modern contemporary designed office w/ 6 fully eq ops. Established in 2006. ID #4209. **SOLD**  
**HUNTINGTON BEACH** (GP) - Modern designed practice w/ 3 eq ops & 1 plmbd in a 1,280 sqft ste. Grossed \$246K in 2012. ID #4317.  
**HUNTINGTON BEACH** (GP) Located in a 2 story prof bldg w/ 3 eq fully eq ops, Dentrux software in a 1,650 sqft ste. ID # 4327.  
**LAKE FOREST** (GP) - Turn key practice w/ 3 spacious eq ops, 1 plmbd not eq in a 1,200 sq ft ste. Busy shopping center. ID #4123.  
**MISSION VIEGO** (GP) - Well designed turn-key practice w/ 3 eq op & 3 plmbd is located in a prestigious shopping center. ID #4303.  
**ORANGE** - Leasehold & Some Equip! Modern designed office w/ 4 plumbed operatories, not eq. in a single story prof. bldg. ID # 4299.  
**RANCHO STA MARGARITA** (GP) State of the art office in 2 story plaza center. Has 7 fully eq ops. NET \$242K. ID #4187.  
**TUSTIN** - Leasehold & Equip Only! Beautiful state-of-the-art off. Great for GP or Spec. 5 eq ops/3 plmbd not eq for expansion. ID #4225.

## RIVERSIDE / SAN BERNARDINO COUNTIES

**APPLE VALLEY** (GP) - Established in 2007 this modern designed office is in a busy shopping center. Net of \$384K. ID #4271.  
**BARSTOW** (GP) - Long established office w/ 4 eq ops in a single story bldg. Easy freeway access. Fee for service. ID #4241  
**FONTANA** (PEDO) - State-of-the-Art office w/ 2 fully eq ops & 3 chairs in open Bay. 15% Insurance & 85% Denti-cal. ID #4301.  
**LA QUINTA** - Price Reduced. Leasehold & Equip Only! Located in strip shopping center W/ 3 eq. ops, 1,000 sq. ft. ste. ID#4063  
**MURRIETA** (GP) - Beautiful office w/ 3 eq ops surrounded by major anchor tenants. Some Capitation. 4 day/wk office. ID #4247  
**SUN CITY** (GP) - Long established office w/ 2 eq ops, 1 plumbed not eq room for expansion in a 4 suite medical/dental bldg. ID #4287

## SAN DIEGO COUNTY

**ENCINITAS** (GP) - Corner location w/ excellent signage and street visibility. Consists of 2 eq ops. Fee for service. ID # 4315.  
**RAMONA** (GP) - Established in 1979 and located in single strip mall. Busy area. Fee for service. Consists of 3 eq op. ID #4305.  
**SAN MARCOS** - Leasehold & Equip Only! Modern designed office. Established in 2007. Consists of 2 eq ops in 800sqft ste. **SOLD**  
**SAN DIEGO** (GP) - In free standing bldg w/ private prkng. Consists of 5 ops w/ Dentrux software. Monthly revenues of ~\$40K. ID #4279.

## VENTURA & SANTA BARBARA COUNTY

**SANTA BARBARA** (GP) - Well established practice in busy shopping center w/ 3 eq ops in a 1,220 sq ft suite. ID #4311.

<http://www.calpracticesales.com/blog>

*Call us about Debt Consolidation & Retirement Planning*  
**VISIT OUR WEBSITE WWW.CALPRACTICESALES.COM**  
**CA DRE#00491323**

John Knipf  
President

*John W Knipf* (Neff)

Also serving you: Robert Palumbo, Executive V. P. /Partner, Alice C. King, V.P.,  
Greg Beamer, V.P., Tina Ochoa, V.P., & Maria Silva, V.P.

## How to Place a Free Classified Ad

The *Journal* has changed its classified advertising policy for CDA members to place free classified ads online and publish in the *Journal*. Only CDA members can place classified ads. Non-CDA members can place display ads.

All classified ads must be submitted through [cda.org/classifieds](http://cda.org/classifieds). Fill out the blank fields provided, including whether the ad is to appear online only or online and in the *Journal*. Click "post" to submit your ad in its final form. The ad will post immediately on [cda.org](http://cda.org) and will remain for 90 days. Space permitting, your ad will run one time in the next issue of the *Journal* following the posting of your online ad. After 90 days, you will need to repost your ad if you wish to continue running it online.

Classified ads for publication in the *Journal* must be submitted by the fifth of every month, prior to the month of publication. Example: Jan. 5 at 5 p.m. is the deadline for the February issue of the *Journal*. If the fifth falls on a weekend or holiday, then the deadline will be 5 p.m. the following workday. After the deadline closes, classified ads for the *Journal* will not be accepted, altered or canceled. Deadlines are firm.

Classified advertisements categories are: Equipment for Sale, Offices for Sale, Offices for Rent or Lease, Available Positions, Opportunities Wanted, and Practices for Sale.

### How to Place a Display Ad

Non-members are welcome to place display ads. For information on display advertising, please contact Corey Gerhard at 916-554-5304 or [corey.gerhard@cda.org](mailto:corey.gerhard@cda.org).

CDA reserves the right to edit copy and does not assume liability for contents of classified advertising.

## AVAILABLE POSITIONS

**DENTAL ASSISTANT** — Upscale, growing dental practice is looking for part-time, experienced DA/RDA to handle appropriate duties. We have a paperless office so must be quick with computers. Basic knowledge of front desk duties is very helpful. Knowledge of digital X-rays is a plus! Minimum 3 years experience required. Must be friendly, outgoing and energetic. Tuesdays, Thursdays and some Saturdays. Interviews will be on Thursdays and Saturdays between 2:30 and 7 p.m. Please email your resume to [dentextdentalca@yahoo.com](mailto:dentextdentalca@yahoo.com).

**DENTAL ASSISTANT** — Private Huntington Beach office is looking for a Dental Assistant who is cross-trained in both front and back. Front office duties include answering phones, scheduling appointments, verifying insurance, as well as some treatment planning. Salary negotiable depending on experience and knowledge. Must have good work ethic, dependable, friendly and a team player. Fax resume to 714-377-2299.

**DENTAL HYGIENIST** — Experienced Hygienist needed for a specialty dental office located in Culver City. While our offices are very busy, we do not operate like a clinic. We desire to attract and retain a

CONTINUES ON 358

## When Looking to Invest in Professional Dental Space Dental Professionals Choose



# Linda Brown

30 Years of Experience  
Serving the Dental Community  
Proven Record of Performance

- Dental Office Leasing and Sales
- Investment Properties
- Owner/User Properties
- Locations Throughout Southern California

For your next move,  
**Contact Linda Brown:**  
Direct Line: (818) 466-0221  
Fax: (818) 593-3850  
E-mail: [LindaB@TOLD.com](mailto:LindaB@TOLD.com)  
website: [www.TOLD.com](http://www.TOLD.com)  
CA DRE #: 01465757

**TOLD**  
**partners** INC.  
INDUSTRIAL/COMMERCIAL REAL ESTATE  
CA DRE #: 01132455

## CLASSIFIEDS, CONTINUED FROM 357

quality-oriented Hygienist who has excellent communication skills. Offices equipped with 5 operatories, digital x-rays, digital charting and PanoRx. Job Requirements: Must have at least 3 years experience; job is for 1 day a week. Serious applicants who desire long-term employment need only apply. Please submit your resume and recent professional photo via email to [dentexdental@yahoo.com](mailto:dentexdental@yahoo.com).

**DENTIST** — Great opportunity to be part of great growing, very high-tech office. Start as an associate, potential to be partner if it works out. Very busy IV sedation office but you don't need to be certified as IV sedation dentist. Please fax your resume 559.325.0709.

**DENTIST** — Our office has an opening for a General Dentist to join our team. We are looking for someone who is interested in long-term, stable employment. An opportunity to establish a strong, quality patient base with continued advancement and growth is at hand. We are a private family dental office. We see mostly adults and some kids. We accept most PPO

insurances, Liberty (county insurance), and cash patients. We do not accept capitation plans or Medi-Cal. Our office is high tech, comfortable, spacious, and a great environment to work in. Our staff is competent, honest and very friendly. Along with all aspects of general dentistry, applicant must be proficient and comfortable doing routine endo including molars. Difficult cases are fine to refer out. Compensation includes a base pay with percentage threshold bonus pay. Some experience is preferred, but completion of and AEGD or GPR is acceptable. Please send resume and optional picture to put a face to the application for consideration. Thank you for your interest in joining our team. We look forward to hearing from you. Email resumes to [admin@customdental.com](mailto:admin@customdental.com)

**DENTIST** — We are looking for a motivated General Dentist who will join our team as full-time associate. This is a mercury-free, holistic dental practice. Therefore, we are looking for a General Dentist who has the desire and willingness to adapt to our office. We are

looking for someone who is interested in a long-term commitment. To schedule interview please contact office manager Tamara Magradze-Whitney at 408.688.1354 or email at [tamosia14@yahoo.com](mailto:tamosia14@yahoo.com).

**DENTIST** — Need a Dentist who can work on Saturday and Friday if needed. You should know restorative and hygiene. Email resume to [preciousdental@yahoo.com](mailto:preciousdental@yahoo.com).

**DENTIST** — Looking for full-time or part-time Associate Dentist. H-1 visa can be sponsor. Call 209.606.3594 or send email to [dr\\_hitsmodi@yahoo.com](mailto:dr_hitsmodi@yahoo.com)

**DENTIST** — General dentistry located in Korea town is looking for an Associate Dentist with minimum 3 years experience. Please email resume to [sdental101@yahoo.com](mailto:sdental101@yahoo.com) to schedule an interview.

**ORAL SURGEON** — New, fast-growing general practice is in need of an Oral Surgeon to take care of all extractions. Very flexible days and hours, we will work with your schedule and what best works for you. All or most materials needed will be provided by office as well as an assistant, if needed. Please fax your resume to 760.775.3938, and include days and time you are available to work.

**DENTIST** — We are looking for a General Dentist in Monterey/Santa Cruz Co. to join our team 3-4 days per week. You must have at least 3 years post-schooling experience and must be proficient in all phases of general dentistry. Please respond by emailing [bayareadentist2009@gmail.com](mailto:bayareadentist2009@gmail.com).

Our inventory is affordable and can help you budget for upgrading your office, expanding or just starting out.


Northbay Networks is a nationwide provider of dental equipment

Pelton & Crane • Dansereau • ADEC • Midmark

Ph: 925.385.0562  
Fax: 510.903.8971  
[www.northbay-networks.com/dental-inventory.html](http://www.northbay-networks.com/dental-inventory.html)



CONTINUES ON 360



# WESTERN PRACTICE SALES

## 800.641.4179

WPS@SUCCEED.NET | WESTERNPRACTICESALES.COM  
Practice Transitions Made Perfect™

### BAY AREA

**AC-085 SAN FRANCISCO:** Long established. 2<sup>nd</sup> floor. 1,433 sf overlooking Park Presidio. 4 ops. Skylights/large windows **\$189k**

**AC-141 DALY CITY Facility:** Close to Serramonte ShpCtr. 950 sf w/ 3 ops REDUCED! Now \$125k

**AG-125 SAN FRANCISCO:** Relaxed schedule (weekends only) Professional building, major thoroughfare, highly desirable area. 1,000 sf w/2 ops. Plumbed for 1 add'l **\$125k**

**B-9851 SAN RAMON Facility:** This opportunity will not wait! Office ~ 1,700sf w/ 3+ ops **\$219k**

**BC-162 PLEASANT HILL Facility:** Updated office, large windows & views of the outdoors. Open floor plan. 1,852 sf w/6 ops **\$200k**

**BN-130 OAKLAND:** Large successful FFS practice, in a multi-story Prof. Building. ~ 2,200sf w/ 4 ops **\$1.4m**

**BG-150 ORINDA:** Well-loved family-oriented practice in bustling heart of town. 600 sf w 2 ops + 1 **\$315k**

**BG-160 SAN PABLO:** Nicest, safest neighborhood in town! Real Estate may be available in future. Single Story Free-standing bldg. 2,875sf w/ 7 ops +1 **\$345k**

**CC-056 MARIN CO:** Beautiful garden setting. Easy access to Hwy 101. 1200sf w/ 3 ops. Room for 2 add'l **\$350k**

**CC-077 BENICIA:** Highly visible. Within walking distance of downtown. 820 sf w/2 ops **\$125k**

**CC-109 PETALUMA:** Priced for quick sale! Reasonable overhead & below market rent. 2 ops. Plumbed for 3 add'l **\$170k**

**CC-118 VACAVILLE Facility:** Highly visible, easily accessible. Ample parking. Growing city. 859 sf w/3 ops. Suite Lease/Purchase option **\$245k**

**CC-133 SANTA ROSA:** Stable patient base. Well-respected. Location = new patient traffic. Excellent signage/major thoroughfare. 1,291 sf w/3 ops + 1 add'l **\$480k**

**CC-151 SANTA ROSA:** Sonoma Wine Country. Stable patient base, well-respected, relaxed atmosphere, close to Memorial Hospital. 2,262 sf w/ 6 ops **\$875k Real Estate avail.**

**CN-158 PETALUMA:** Predominantly Capitation practice. ~800 sf w/ 2 ops **\$450k**

**D-9091 ATHERTON:** Turnkey operation 969 sf & 3 ops **Call for Details!**

**DC-113 MILPITAS:** Seller retiring! Great location 1,009 sf w/ 3 ops. Plumbed for 1 add'l **\$140k**

**DC-122 CUPERTINO:** Rare Opportunity! Well-respected, FFS/cash practice. 1,075 sf w/ 3 fully equipped ops. Plumbed for 1 add'l **\$889k**

**DC-152 CASTRO VALLEY/HAYWARD:** Room to grow w/marketing & schedule focus. 1,700 sf w/ 4 ops +1 **\$215k**

### BAY AREA CONTINUED

**DG-124 MILPITAS:** Highly visible. Desirable area. 960 sf w/ 2 ops + 1 add'l **\$130k**

**DG-116 SALINAS AREA:** Large, loyal, stable patient base. Popular Retail Center. 1,400 sf w/5ops. State-of-the-art Equipment **\$245k**

**DG-138 MONTEREY:** Centrally located in "New Monterey". Charming office. Excellent street exposure! 1200 sf w/ 4 ops **NOW ONLY \$620k**

**DG-147 SANTA CLARA Facility:** Popular anchor stores/Rtl Shp Ctr. Street-level presence. High foot traffic. 1,500 sf w/ 3 ops + 2 add'l **\$185k**

**DG-156 SAN JOSE:** Hardwood Floors, Glass Doors & plenty of windows! 1,160 sf w/ 3 ops (+2 add'l) **\$165k**

**DN-063 SAN JOSE:** Long-established, Popular Retail Shopping Center. 780 sf w/ 2 ops **\$70k**

**DN-084 PALO ALTO Facility:** Drawing from an educated, upper middle class community. "Move-in" ready! 700 sf w/3 ops **\$125k**

**DN-099 SAN JOSE Facility:** Ultra-modern facility. Well-established. Dental Professional Complex. 1,450 sf w/5 ops **\$99k**

### NORTHERN CALIFORNIA

**E-8641 SACRAMENTO Facility:** 2,100+ sf w/ 3 ops & plumbed for 1 add'l **\$50k**

**EN-114 ANTELOPE Facility:** Great Location! "Move-in-ready" with 4 ops + 1 add'l **\$120k**

**EN-145 ROCKLIN Facility:** Very desirable community! ~1,400sf w/3ops +1 add'l **\$150k**

**F-1013 FORTUNA:** Well respected FFS GP. Loyal stable patient base. 1,000 sf w/ 3 ops **REDUCED! Now only \$150k**

**FN-087 LAKE COUNTY:** Quality practice w/ friendly staff! ~2400 sf w/ 3+ ops **\$775k**

**FN-088 SISKIYOU CO:** Family Friendly Location. ~1300 sf w/ 2 ops **\$85k /Real Estate: TBD**

**GN-058 YUBA CITY:** Known for quality dental care, 1704 sf w/ 4 ops Reduced! **\$359k**

**GN-075 YUBA CITY:** Seller Will Consider Reasonable Offer! ~3,000 sf w/ 8ops **\$250k**

**GN-103 CHICO:** Successful, highly esteemed practice! ~3500 sf w/ 8 ops + 2 add'l **\$850k**

**GN-134 REDDING:** Stellar reputation, quality care and location! ~2,264sf w/4 ops. **\$500k**

**GG-140 OROVILLE:** Multi-Generational w/ "Small-Town" feel. 1200sf w/4ops **\$248k**

**GN-149 YREKA:** Quality FFS, Warm & Caring. ~900sf w/ 3 ops **\$200k/Real Estate \$110k**

**HN-059 LASSEN CO:** Quality, well-established, family-oriented. 1600 sf w/3 ops **\$120k**

**HG-159 S. LAKE TAHOE:** Retail Shopping Complex w/ spectacular views of the lake from each Op. 2,000 sf w/ 5 ops **\$590k**

### CENTRAL VALLEY

**I-9721 STOCKTON:** Prof. complex . 1,450 sf w/ 3 ops & plumbed for 1 add'l **\$75k**

**IG-067 STOCKTON:** Fully computerized, paperless, digitalized. 5000 sf w/ 10 ops **\$475k**

**IG-081 TURLOCK Facility:** Close to heart of town and public transportation. Highly visible intersection. 1512 sf w/ 5 ops. **Oppty to Buy Condo Also! Practice: \$50k**

**IN-135 GREATER MERCED:** Major thoroughfare/ Prof Corridor. 1,300 sf w/ 3 ops **PRICE REDUCED! NOW ONLY \$350k**

**J-1000 TULARE:** Highly visible location! ~1650 sf w/ 4 ops **\$465k /Real Estate: \$249k**

**J-1001 LINDSEY:** All American City! Conveniently located ~3380 sf w/ 5 ops **\$220k**

**JG-136 FRESNO Facility & Real Estate:** Highly visible, free-standing Professional building on major thoroughfare. 5000 sf w/ 9 ops **\$475k**

**JG-137 FRESNO:** Own the Building too! Stable Patient Base! ~3500 sf w/ 5 ops **\$465k/ Real Estate \$350k**

**JN-157 FRESNO:** Comprehensive care and comfort . ~1470 sf w/ 3 ops. **\$200k**

### SPECIALTY PRACTICES

**AC-119 MILL VALLEY Prosthodontics:** Near downtown. Recently remodeled! State-of-the-art equipment including: digital charting and x-ray. 1,100 sf w/ 3 ops. Plumbed for 4<sup>th</sup> **\$450k**

**AG-096 PACIFICA Orthodontics:** Solid referral base. Perfect opportunity for merger/secondary office. 1,400 sf w/5 chairs **\$178k**

**CG-105 VACAVILLE Orthodontics:** Strong, loyal, wide-spread referral base. 30+ pats/day. 5-6 new starts/mo. 2,000 sf - 4 chairs/bays **\$280k**

**EG-131 ROSEVILLE/AUBURN Orthodontics:** 2 practices within ½ hour of each other! Call for all the details on both locations! **\$175k**

**GN-117 SACRAMENTO/N. VALLEY Endodontics:** Highly esteemed, Fee-for-Service. ~2000 sf w/3ops **\$310k**

**I-7861 CENTRAL VALLEY Orthodontics:** 2000 sf, open bay w/ 8 chairs. Fee-for-Service. 60-70 patients/day. Professional Plaza **\$370k**

**I-9461 CENTRAL VALLEY Orthodontics:** ~ 1650 sf w/5 chairs/bays & plumbed for 2 add'l **\$180k**







Considering selling  
your practice?

**You do the dentistry  
(or perhaps the golfing?)  
while we handle the  
sale process.**

We have been  
handling dentists'  
practices **with care**  
since 1997.

**It's what we do!**

*"Awesome team, awesome service, awesome expertise. . . all aspects of the transaction were expeditiously and professionally handled, and I was able to travel during the whole sale process!"*

D. Craig Fitch, DDS

Dental Practice: Sales - Acquisitions - Mergers - Valuations

**Practices recently available in:**

- New! ♦ Carmel Mountain Area ♦ LA Civic Center Area  
♦ N San Diego County (Pending) ♦ NE Las Vegas, NV (Pending)  
♦ Orange County Ortho (Pending) ♦ Reno, NV  
♦ Downtown LA (Pending) ♦ NW Las Vegas, NV  
♦ San Joaquin Valley (Pending)

**PRACTICE  
TRANSITION**  
realizing the possibilities **PARTNERS**



Russell Okihara, D.M.D.  
CA Representative



Robert Stanbery  
Owner

Visit our website to view  
our current listings.

**888.789.1085**

**www.practicetransitions.com**

CLASSIFIEDS, CONTINUED FROM 358

**DENTIST** — We are inviting board-eligible or certified Endodontists to come and help us maintain and grow our strong endo program in our multispecialty offices in San Jose and the surrounding area. Please email bayareadentist2009@gmail.com or call 408.656.4567.

**DENTIST** — Access Dental has openings for experienced Dentists in the Central Valley (Modesto and Stockton) and Northern California (Redding). Qualified applicants seeking full-time positions will be considered. On-call positions are also available. A number of our practices are newly constructed and offer beautiful, esthetic environments in which to practice. Additionally, our offices are equipped with the newest technology and equipment, including electronic medical records, digital radiography and intraoral cameras. In our practices we welcome patients of all ages, but because a significant amount of our patients are children, it is necessary for interested candidates to have experience with and enjoy treating children as well as adults in a fast-paced atmosphere. Access Dental offers relocation assistance, competitive wages, a great benefits package and a chance to work with a devoted team of people who take a visionary approach to group dental practices. We offer superior administrative support in areas such as human resources, information technology, marketing, training and supply procurement. We are a company that prioritizes quality dental care and exceeding customer service expectations. Ask about potential relocation assistance. Duties and responsibilities:

CONTINUES ON 362



**Dr. Dennis Hoover**  
Western Regional Manager  
& Corporate Broker  
CA R.E. Lic. #01233804  
NV R.E. Lic. #0053890 • NV B.O. Lic. #0000301



**Dr. Thomas Wagner**  
Transitions Consultant  
CA R.E. Lic. #01418359



**Jim Engel**  
Transitions Consultant  
CA R.E. Lic. #01898522



**Thanh Tran**  
Transitions Consultant  
CA R.E. Lic. #01863784



**Mario Molina**  
Transitions Consultant  
CA R.E. Lic. #01423762

## “DENTAL PRACTICE BROKERAGE”

**Making your transition a reality.**

More information is available on our website regarding practices listed in other states, articles, upcoming seminars and more.

**VISIT OUR WEBSITE AT:  
WWW.PPTSALES.COM**

**Practice Sales • Mergers  
Partnerships • Appraisals  
Patient Record Sales**

- **BISHOP:** For Sale-General Dentistry Practice & Building. After 29 years in the same location this retiring dentist is selling both his practice and building. Collections were \$1,000,243 in 2011 with \$387,000 adjusted net income. There are 6 days of hygiene in this 5 op., 1,800 sq. ft. building. 100% financing available for both building and practice. Owner has reduced price below valuation price. #14390
- **CHICO:** For Sale-General Dentistry Practice. Owner retiring: 2012 Collections of \$1,385,222 with 7-8 days of hygiene. This excellent, well-established practice in free-standing building has 1,800+ active patients with an average of 15 new patients per month. Equipment includes new Digital Cone Beam X-ray, Digital X-rays, Lasers, and Dentrix software. Buyer can purchase or lease building. Don't miss out on this excellent practice. Owner will consider an associate leading to purchase of practice. #14392
- **FRESNO:** For Sale-General Dentistry Practice: \$935K in collections in 2011, w/adjusted net income of \$337K. Office is 2,300 sq. ft. and is located in north Fresno in a highly visible professional office complex on a main thoroughfare. There are 6 equipped operatories, owner reports average age of equipment is 4 years. Practice has been operating in present location for over 20 years. Eaglesoft software, owner is retiring. #CA502
- **GRASS VALLEY:** For Sale-General Dentistry Practice. Gross Receipts of \$491K with an adjusted net income of \$130K. Overhead 73%. Office leased 1,555 sq. ft., 4 equipped operatories, 5 available. Laser, Intra-oral Camera, Cerac, & Eaglesoft Software. Owner would like to retire. #14379
- **GRASS VALLEY:** For Sale-General Dentistry Practice. Owner retiring, 2012 GR of \$442,736 on 3 day week. 6 Ops, 3 days hygiene, Dentrix software, Pano, Laser, Intra-oral Camera, long time cash practice. Approximately 1,950 SF office condominium available to purchase. #14372
- **GREATER SACRAMENTO:** For Sale - Associate to Owner Opportunity: 2012 Gross Receipts of \$879,000. Well-appointed 1,400 sq. ft. office with 5 ops, Intra-oral Cameras, Laser, Cerec, 4 days hygiene, Softdent software. Associate to work two days a week in 2013 & 2014 then purchase practice. Equipment is about 5 years old. Owner to work back 2 days per week for 2 years after purchase. #CA525
- **HAWAII (MAUI):** For Sale-General dentistry practice. Gross Receipts of \$636K. Office has four equipped operatories in 1198 sq.ft. Pano, Laser, I.O. Camera, Fiber Optics, 2 ½ days of hygiene. Owner retiring: Don't miss this opportunity to live and work in paradise. #20101
- **LANCASTER:** For Sale-General Dentistry Practice. This 4 operator office is located in 2,360 sq. ft. on the second floor of an attractive Medical-Dental office building. Gross receipts were \$676,000 with a \$174K adjusted net income. Dentist is retiring after 39 years. 4 days of hygiene. Additional operatories could be added to existing space. Great location. Asking price has been significantly lowered! #14376
- **LAS VEGAS:** For Sale-General Dentistry Practice. This 4 operator practice is in a great location in a high-end professional building with a view of the city of Las Vegas. It is equipped with an Intra-oral camera, Pano, Laser, and Dentrix software. There are 2 days of hygiene. The staff is well trained to efficiently run this low overhead office with great potential for further growth, 2011 gross receipts were \$727K with adj. net income of \$331K. Doctor moving out of state. PRICE REDUCED! Available for immediate sale. #NV500
- **MERCED:** For Sale-General Dentistry Practice. This is a tastefully done, 4 op., 1,550 sq. ft. office with 4 and 1/2 days of hygiene/week. All equipment is less than 10 years old and includes 2 Lasers, Intra-oral Camera, Panorgraphic X-ray, Digital X-rays, and Dentrix Software. Molar endo and involved oral surgery cases referred out. Basic general (non-amalgam) type dentistry. 2011 gross was \$878,000 with 4 weeks out as a result of a medical issue. 2010 collections were \$956,000. Excellent location. Seller retiring. PRICE REDUCED! Available for immediate sale. #CA512
- **MILLBRAE:** For Sale-General Dentistry Practice. This beautiful, well-established office is located on the main thoroughfare of the North Peninsula, offering great exposure that generates 25-30 new patients per month. 5 treatment rooms (6th plumbed) in approx. 1,500 sq. ft. equipped with Digital Pan, Digital Imaging and Intra-Oral Camera. 2011 gross receipts of \$651,000 with \$230,000 adjusted net income. Owner is retiring. Don't delay, this won't last long! #14395
- **NORTH BAY AREA:** For Sale-ENDODONTIC Practice: This beautiful Wine Country office has 4 treatment rooms in well-appointed 1,600 sq. ft., digital imaging, Intra-Oral Camera, and Datacon/Schick software. Office has been in same location for over 20 years with a very strong referral base. Great, long-term staff will ensure a smooth transition. Owner is retiring but is willing to stay during transition. #CA517
- **RIDGECREST:** For Sale - General Dentistry Practice and Dental Building: This 4 operator office is located in 1,536 SF office building. Owner has worked in same location for 32 years and is now retiring. This small practice grossed about \$175K in 2012. Pictures of the building are available upon request. Lots of Potential. #CA523
- **SACRAMENTO:** For Sale-General Dentistry Practice. Owner moving out of state. 2011 GR \$130,373. 830 SF office with 2 equipped ops. Practice has been in same location since 1981. This is an opportunity for anyone looking to start a practice or open a satellite office with a small investment. #CA522
- **SACRAMENTO:** For Sale-General Dentistry Practice. Gross Receipts \$546K with adjusted net income of \$159K. Office is 2,400 sq ft with 7 operatories. Practice has been operating in the same location for the past 50 years. Pano, Softdent software. Owner to retire. #14374
- **SAN RAMON:** For Sale-FACILITY SALE. Great San Ramon location in professional complex: equipment, leaseholds & furnishings only. 1,400 sq. ft. with 4 equip. treatment rooms (2 additional plumbed), Pano X-ray, Computer Server & Workstations w/Dentrix, Intra-oral Camera & wired for digital. Priced to sell in an upscale community that's home to Chevron, AT&T, Robert Half International, Accenture and Safeway Stores. #CA511
- **SAN JOSE:** For Sale-FACILITY ONLY: Beautiful Blossom Valley Professional location near Oakridge Mill and Whole Foods Market. Three fully equipped ops in approx. 1,200 sq. ft. including Digital sensor, Eaglesoft software, and full computer network. Avoid the expense of leasehold improvements and equipment with this ready-to-move-in office. Owner relocating just in time to start your own dreams. #CA515
- **TURLOCK:** For Sale-General Dentistry Practice: Doctor's gross receipts in 2012 were over \$950,000 with only 54% overhead or \$443,777 adjusted net income. There are 8 days of hygiene. Intra-oral camera, Panoramic X-ray, Digital X-rays, and Dentrix software. Owner is retiring. #CA506

### CALIFORNIA / NEVADA REGIONAL OFFICE

#### **HENRY SCHEIN PPT INC.** California Regional Corporate Office

##### **DR. DENNIS HOOVER, Broker**

Office: (800) 519-3458 Office (209) 545-2491

Fax (209) 545-0824 Email: [dennis.hoover@henryschein.com](mailto:dennis.hoover@henryschein.com)

5831 Stoddard Road, Ste. 804 Modesto, CA 95356

#### **Henry Schein PPT Inc., Real Estate Agents** and Transitions Consultants

Dr. Tom Wagner (916) 812-3255 N. Calif.

Jim Engel (925) 330-2207 S.F./Bay Area

Mario Molina (323) 974-4592 S. Calif.

Thanh Tran (949) 533-8308 S. Calif.

## CLASSIFIEDS, CONTINUED FROM 360

Perform general dentistry services to patients of all ages, which includes the diagnosis and treatment of diseases, injuries and malformations of teeth, gums and related oral structures. Job requirements: DDS or DMD degree, licensed in California. 2-plus years experience as a licensed dentist with demonstrated experience treating children. Commitment to quality patient care, excellent customer service and to educating patients on dental health. A positive attitude and ability to be a team player who brings a sense of excitement and fun to the practice. For immediate consideration, please submit your resume to [jessica@premierlife.com](mailto:jessica@premierlife.com).

**DENTAL PRACTICE MANAGER** — We are seeking a highly dependable, detail oriented, well-organized Practice Manager who can work independently and supervise employees. Must have dental and management experience. Knowledge of Dentrix software and excellent written and communication skills are required. Candidate must have excellent phone and people skills. Candidate should be reliable, exhibit a high level of professionalism and a strong work ethic. Minimum of 10 years dental front office experience required, including billing and knowledge of various insurances. If you are looking to be part of a great dental team focused on

providing the best service and care to patients, please email your resume to [dralishmara@yahoo.com](mailto:dralishmara@yahoo.com).

**FRONT OFFICE/TREATMENT**

**COORDINATOR** — Our fee-for-service dental office is seeking a motivated, outgoing, personable and professional Front Office/Treatment Coordinator to join our team. If you like seeing one patient at a time and doing quality treatment, then this is the place for you. We provide high-end, quality dentistry in a calm, relaxed atmosphere. The latest state-of-the-art equipment and an organized office environment makes this the perfect place for one lucky individual. We are looking for an experienced, outgoing individual potentially with some sales or customer service experience for 4 days a week. Must be people oriented, positive attitude and experienced in quality customer service. The right candidate is enthusiastic, caring and energetic with great communication and listening skills. Along with being a front office coordinator, you will be responsible for promoting the office, creating opportunities for patients to have the best care, assisting patients with financial options and providing education pertaining to their dental insurance benefits. Candidates must be computer competent and know how to use Dentrix. We look forward to receiving your resume should you meet the requirements. Please email resumes to [doc@tcsdental.com](mailto:doc@tcsdental.com).

## OPPORTUNITIES WANTED

**PERIODONTIST** — In-your-office for the greater San Francisco Bay Area. Have mobile equipment and supplies to place implants, ridge and sinus grafting, periodontal surgery, third molar extractions, etc. Extensive private practice and teaching experience having placed thousands of implants and grafts. Send email to: [mobileimplants@hotmail.com](mailto:mobileimplants@hotmail.com).

CONTINUES ON 364

# PARAGON

## DENTAL PRACTICE TRANSITIONS

We are pleased to introduce our  
transition consultant for California:

**Trish Farrell**

[trish@paragon.us.com](mailto:trish@paragon.us.com)

866.898.1867

Please expect a visit and/or phone call from  
your local PARAGON transition consultant



Call 866.898.1867 or visit [paragon.us.com](http://paragon.us.com) to sign up for our free newsletter



# CARROLL & COMPANY

Complete Evaluation of Dental Practices & All Aspects of Buying and Selling Transactions

**"MATCHING THE RIGHT DENTIST  
TO THE RIGHT PRACTICE"**



*Serving you: Mike Carroll &  
Pamela Carroll-Gardiner*

## **3092 SF FACILITY**

1,600 sq. ft. street-level dental facility in Marina/Cow Hollow neighborhood across from Presidio with excellent visibility and signage for foot traffic plus easy diagonal parking in front of building. Move in ready with 4 ops., 2 labs, kitchenette, reception and 2 desk areas plus 2 pvt. offices, 2 bathrooms, 1/2 basement & backyard with deck.

## **3091 MORGAN HILL GP**

Well-established GP in prime Southern Santa Clara County location. Gorgeous 1,500 square foot state-of-the-art office with 4 operatories. Ideal turn-key operation. Asking \$195K.

## **3090 PACIFICA GP**

Seller retiring from well est., well-run, coast side practice. Located a block from the beach with rolling hillsides in a charming community just 20 minutes from SF. Approx. 1,400 active pts., 4 doctor-days/wk, 6 hygiene days/wk. & 13-15 new pts./month. Avg. GR for past 3 years \$473K. Seller willing to help for smooth transition. Asking \$313K.

## **3099 LOS GATOS GP**

Well-est. general, restorative & cosmetic practice available in very desirable neighborhood. Gorgeous 1,530 sq. ft. office in single story dental complex w/4 ops. Parking is plentiful & easy freeway access. 2012 GR \$750K+ with 3 doctor-days and 2.5 days of hygiene. Asking \$580K.

## **3995 SAN CARLOS**

Seller well-known for quality patient care retiring from established practice with loyal patient base, in highly desirable neighborhood. 2012 GR 750K+ Asking \$515K.

## **3085 MODESTO GP**

General, family practitioner now retiring. Offering well-est. successful, state-of-the-art practice in approx. 2,800 sq. ft. facility w/7 fully-equipped ops. Owner willing to help in transition. Estimated 2,500+ active pts. 5 year avg. GR \$1.4M w/net of approx. \$500K & just 3.5 doctor days & 10 hyg. days/wk. This practice is for an established dentist or 2 dentists w/experience & who will appreciate a high quality practice. Asking \$895K.

## **3093 SAN JOSE FACILITY**

Avoid the expensive cost of leasehold improvements and equipment! Central Blossom Valley location ready for a start-up practice or 2nd office. Three fully equipped treatment rooms in approximately 1200 sq. ft. Photos and complete inventory of furnishings and fixtures available. Owner is relocating.

## **3089 GILROY GP**

Seller retiring from well-est. high quality practice w/approx. 1,200 active pts. 2011 GR \$513K+ w/3.5 doctor days/wk. 5 fully-equipped ops in 1,440 sq. ft. modern facility. Seasoned and dedicated staff providing a relaxed atmosphere to loyal pt. base. Asking \$350K.

## **3082 SONOMA COUNTY GP**

Well-established, family-oriented practice in charming community located in the hub of Sonoma County. Approx. 14 new pts./month. Approx. 1,500 active pts. 2011 GR \$552K+. Asking \$384K.

## **3094 NORTH BAY PERIO**

North Bay Perio now available. Seller retiring from well-est. practice with seasoned staff and active referral base. 1,300 sq. ft. very nice office with 4 fully- equipped operatories. 2012 GR \$450K+ with just 3 1/2 doctor days and 5 days of hygiene per week. Great upside potential since owner does few implants. Asking \$271K.



### **Contact Us:**

Carroll & Company  
2055 Woodside Road, Ste 160  
Redwood City, CA 94061

### **Phone:**

650.403.1010

### **Email:**

dental@carrollandco.info

### **Website:**

www.carrollandco.info

CA DRE #00777682



## CLASSIFIEDS, CONTINUED FROM 362

## OFFICES FOR RENT/LEASE

**OFFICE FOR RENT OR LEASE —** Dental office for lease on busy Whittier Blvd. in La Habra and the adjacent neighborhoods of Whittier, Hacienda Heights, La Habra Heights, La Mirada and Fullerton. Great visibility and signage with plenty of gated parking in the back for patients. Great location, right across from La Habra High School. 1,200 sq. ft. already permitted for dental office and plumbed. Can expand to next unit (if still available) for 2,400 sq. ft. Full-front windows on high-traffic

Whittier Blvd., cross between Hacienda Road and Idaho. Landlord will upgrade the exterior building. Asking rental rate is \$1.50/sq. ft. This is a must-see space/location. Call Lukas at 714.782.8991 or leave a message at 714.562.0402.


**OFFICE FOR RENT OR LEASE —** North Bechelli Professional Offices. Prosthodontist needed in Northern California (currently no prosthodontist north of Sacramento.) Office available in recognized dental complex in Redding. Terms for lease will be favorable for starting a new practice. Contact evenings: 530.550.0312 or cell 530.917.0403.

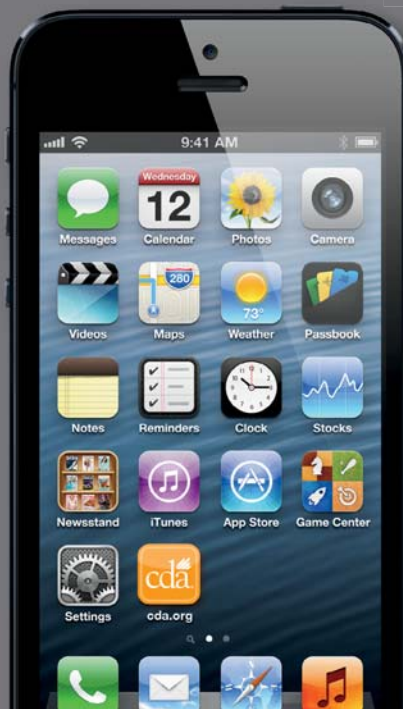**OFFICE FOR RENT OR LEASE —** Great opportunity to sublease 2 operatories in our spacious 5-op office. Great location just off the 5 Freeway in Irvine. The office is in a three-story medical building. The operatories are plumbed and ready to add your chairs, your patients, units and X-ray heads. There is plenty of room for your supplies. We have a spacious front desk area and beautiful reception area. Great for someone looking to cut overhead. Email russellcannondds@earthlink.net. Check out our office at [www.DrRussellCannon.com](http://www.DrRussellCannon.com). Please call us at 949-552-7874.

CONTINUES ON 366

# One tap to everything CDA.



Now, content that's updated daily on the new **cda.org** is just a touch away when you create a CDA shortcut on your smartphone or tablet's home screen. Think of it as an easy shortcut to all things CDA, especially breaking news and updates. Using your smartphone or tablet, visit CDA's website and select your browser's bookmark option. Choose the "add to home screen" option and, voilà, an icon that resembles an app will appear on your home screen. And just like that, you're one quick tap away. 





# Professional Practice Sales

Specialists in the Sale and Appraisal of Dental Practices  
*Serving California Dentists since 1966*  
How much is your practice worth??  
*Selling or Buying, Call PPS today!*

**Practices  
Wanted**

**NORTHERN CALIFORNIA**  
**(415) 899-8580 – (800) 422-2818**  
**Raymond and Edna Irving**  
**Ray@PPSsellsDDS.com**  
**www.PPSsellsDDS.com**  
**California DRE License 1422122**

**SOUTHERN CALIFORNIA**  
**(714) 832-0230 – (800) 695-2732**  
**Thomas Fitterer and Dean George**  
**PPSincnet@aol.com**  
**www.PPSDental.com**  
**California DRE License 346937**

- 6008 MENDOCINO COAST – FORT BRAGG** Cultural haven offers attractive lifestyle. 2012 collected \$750,000. 4-days of Hygiene. Digital radiography. Computers in ops.
- 6029 NORTHEAST CALIFORNIA – ALTURAS** Trade in smog and congestion for soaring mountains and close-knit communities. 2012 collected \$514,000 on 3-day week. 3+ days of Hygiene. Strong Recall. Great staff. Beautiful office. 3-ops with Adec delivery systems. Be busy, be happy and take vacations. No worries here.
- 6030 SANTA ROSA AREA - OCCIDENTAL** 2012 collected \$850,000. Strong profit 4 days of Hygiene per week. Digital x-rays. Building option. **SOLD**
- 6034 SAN LEANDRO AREA** Did \$650,000 in 2011. Owner reduced time in 2012. Collected \$450,000. 5-ops. Nice Hygiene schedule. Great blue collar practice.
- 6035 SAN FRANCISCO'S EAST BAY – ORTHO** Part-time practice collected \$425,000 in 2012. Very desirable location.
- 6037 SAN FRANCISCO'S UNION SQUARE** Optimum opportunity for Dentist seeking high-end downtown practice. 5-days of Hygiene. Collected \$750,000+ with Available Profits of \$325,000+. Great views. **SOLD**
- 6038 FREMONT** On part-time schedule due to other responsibilities, collects \$300,000 per year. 2-days of Hygiene.
- 6039 LAKE TAHOE – CALIFORNIA SIDE** Long established. 2012 collected \$515,000 with 2-months off. Realized Profits of \$230,000+. Attractive 3-op office.
- 6040 SANTA ROSA** Sleeping Giant. Beautiful 4-Op office is paperless, digital and employs laser technology. Collected \$480,000 in 2012. Should have done more! Prior year did \$625,000. Package includes 1,500 sq.ft. condo which shall create a facility cost which shall be cheaper than rent.
- 6041 PLEASANT HILL** Collected \$365,000 with Profits of \$142,000 in 2012. Owner slowing down. Previous 3-years averaged collections of \$415,000 and Profits of \$180,000.
- 6042 BERKELEY** 2012 produced \$1.3 Million and collected \$1.23 Million. Available Profits totaled \$465,000. Owner works just 3-days a week. 6-days of Hygiene per week. Very strong foundation.
- 6043 EL SOBRANTE** 3-day practice collected \$170,00 in 2012. 3-ops.
- 6044 MODESTO** Great location in area with new development occurring nearby. Collected \$380,000 last year. Very attractive office.

- ARVIN – LAMONT** Grossing \$20-to-\$40,000/mth on 2-days. 5-Ops. HMO shall pay for building & practice. FP for Building & Practice \$350,000.
- ANAHEIM** NW Disneyland. Part time. 2 days week. Hi identity corner. 1,800 sq.ft. 5 ops. Low rent. Gr \$200,000. Previously opened 4 DDS days. Owner has no time to cover practice. FP \$150,000.
- ANAHEIM HILLS** Solo Group member wanted. Hi identity, hi tech share beautiful space.
- APPLE VALLEY** Hi identity shopping center practice. Gr \$650,000. Seller very conservative. Part time DDS says full time DDS will do Million. FP \$550,000.
- BAKERSFIELD – SMALL TOWN MINUTES AWAY** Modern practice. Gr \$20 to-\$40/mth. Bargain.
- BALDWIN PARK** Hi Identity free-standing building . 3 ops with conservative Lady DDS. Gr \$200,000+. Located next to large Medical Complex. FP \$185,000.
- CARLSBAD** Est 30+ yrs, free standing bldg, 12 ops. Absentee run Gr \$700,000. Hi identity building. FP \$585,000.
- GARDEN GROVE** Gr \$450,000. Korean patients. Well est shopping center. FP \$330,000. Bargain. Ask Why!
- HEMET** Hi Identity Western Dental-like location. HMO office. Owner works 2-days. 4,000 sq ft & approx \$4000 rent. Includes approx \$100K in ortho. Gr approx \$700K. Previously \$1+ Million when Owner was focused. With good marketing plan this is a \$1.5 opportunity. FP \$550,000.
- INDIO** 4,600 sq.ft. building. First practice in Indio. Across from City Hall. 2 op ready to expand.
- LAMONT- ARVIN** Part time Gr \$40K on 2-days. Free-standing condo next to McDonalds. 3000 sq ft office, 5 ops with living area. FP with Real Estate \$385,000 or Make Offer.
- LANCASTER** Est 50 years, hi identity central location, low overhead. Gr \$480K by part time Owner. Seller can work back. 5-ops. Manager says Full Time Doc will do a Million.
- LAS VEGAS - SMALL TOWN** State of Art. \$600K invested. PT does \$660K. Work 4-to-5 days, do \$1 Million.
- LAVERNE 210/57 FREEWAY** Senior Seller will assist in 5-year buy-out. Gr in excess of \$1 Million. Enough room for 2-DDS. Many options here.
- MONTCLAIR** Newly constructed 6 op hi identity office. Extension of practice Tom Fitterer sold 2-times in 40 years. Will be Million dollar office in 5 yrs.
- ONTARIO SHOPPING CENTER** Near 60 Fry. 5 ops in Stater Brothers Center. Bargain \$250,000.
- ORANGE** Grosses \$30-to-40K/month FP \$285,000.
- PALMDALE** Bargain. 4-ops, hi identity shopping center. FP \$195,000.
- RANCHO CUCAMONGA EMERGENCY** Health dictates sale! Includes Mgr who can bring 50-to-80 NPs/mth. Hi identity shopping center next to 210 Freeway. Full price \$880,000.
- REDLANDS** GP Grossing \$15K/month. Condo office low overhead.
- RESEDA SF VALLEY AREA** Hi Identity location. 70 NP/mth. Growing rapidly. Grossed \$600K in 2011, with current projections \$1,000,000 this year.
- SAN DIEGO BEACH CITY** Gr \$800,000. Absentee DDS lives far away. Owner-operator will gross \$1 Million first yr. Beautiful deco architecture. Hi identity bldg available or rent.
- SANTA PAULA AT FILLMORE** Hi identity location. Gr \$400K+. Like new. 5 ops plumbed, 3 equipped. Steady growth. Beautiful office.
- SUPER SAN FERNANDO VALLEY** Established 30 years.
- TEMECULA - HEMET** HMO. Gr \$600,000 part time. 8 ops fantastic location. Million Dollar corner. FP \$565,000.
- TORRANCE** Established 37 yrs. Gorgeous office. 3 ops. Gr \$240K. FP \$195,000.
- YUCCA VALLEY** Hi identity (huge sign). 600 sq. ft., 2 ops on .44 acres zoned for additional home plus apts. FP \$110,000.

**\*\*FOUNDERS OF PRACTICE SALES\*\***

115+ years of combined expertise and experience!  
3,000+ Sales - - 10,000+ Appraisals

**\*\*CONFIDENTIAL\*\***

PPS Representatives do not give our business name when returning your calls.

**SELL YOUR ORANGE COUNTY OR LA PRACTICE  
GROSSING \$500K AND ASK PPS FOR A PRACTICE  
NETTING \$500K OR MORE.**

**\*\*BUYERS AND SELLERS SAY\*\* – “We have dealt with other firms - we like YOUR professional expertise.  
We will recommend YOU to all our colleagues. Thank you.”**



## PRACTICE SALES AND LEASING

**Thank You for Visiting Us at the Anaheim CDA**



**Paul Maimone**  
Broker/Owner

**ANTELOPE VALLEY** – (7) op comput. G.P. in a free standing bldg. Newer eqt., digital X-rays. Annual Gross Collect \$1.5M. Cash/Ins/PPO pts. 20-30 new pts/mos. (50) yrs. of Goodwill.

**BAKERSFIELD #21** – (10) op comput. G.P. & Bldg. on main St. (3) ops fully eqt'd. (3) ops part eqt'd & (4) plumbed. Store front w exposure. Collects ~\$500K/yr. Cash/Ins/PPO. **PENDING**

**BAKERSFIELD #25** – 4 op comput. G.P. & free stand. duplex bldg. for sale. Located on a main thoroughfare. Cash/Ins/PPO pts. (3) days/wk of hygiene. Gross Collections \$400K/yr. **NEW**

**BAKERSFIELD #26** – 3,500 sq ft free stand. duplex bldg. w a (5) op fully equipped turnkey dental office. Located on a main thoroughfare w monument signage. Move in condition. **NEW**

**BALDWIN HILLS** – Leaseholds w some eqt'd & approx. 200 active pts. (3) op starter G.P. located in a prof. bldg. Very low overhead & very affordable sale price. Mixed pts. **NEW**

**CAMARILLO #3** – (3) op comput. G.P. located in a large strip ctr. w signage. On a main thoroughfare. (2) ops eqt'd third plumbed. Cash/Ins/PPO. 2012 Gross Collect \$131K p.t. **NEW**

**CENTRAL VALLEY/So. FRESNO COUNTY** – (3) op comput. G.P. in smaller town w ltd. competition. Newer eqt. Networked & digital. Dentrix & Dexis. Gross Collect \$40K+/mos.

**HACINEDA HTS #1** – (2) op G.P. Located in a shop. ctr. Collect \$140K/yr. p.t. **SOLD**

**RESEDA #6** – (3) op comput G.P. located in a prof. bldg. Gross Collect. ~\$140K/yr p.t. Cash/Ins/PPO pts. Digital X-rays & Dentrix. Great starter or 2nd office. **SOLD**

**SAN FERNANDO VALLEY ORTHO PRACTICE** – **UPCOMING** Check Back Soon.

**SAN JOAQUIN VALLEY** – G.P. & Bldg. in small town w ltd. competition. (4) op comput. office. Cash/Ins/PPO. Annual Gross Collect \$500K+. Low overhead. Seller retiring. **REDUCED**

**SANTA BARBARA #3** – (3) op comput. G.P. in a prof/med/dental bldg. Cash/Ins/PPO. 8-10 new pts/mos. Gross Collect. \$250K+ on a (4) day wk. Digital X-ray. Seller retiring. **SOLD**

**So. PASADENA – EMERGENCY SALE! SELLER PASSED AWAY!** (5) op comput. G.P. in a small dental/medical bldg. on a main thoroughfare. Fee for Service cash & Delta Premier pts. 2012 Gross Collect \$1.2M+. (8) days of hygiene/wk. Digital X-rays & central nitrous. **SOLD**

**VISALIA** – (4) op comput. G.P. and triplex bldg. for sale. Gross ~\$20K/mos. p.t. **NEW**

**WESTLAKE VILLAGE** – Gorgeous complete turnkey. No charts. Ready to see pts. **SOLD**

**WEST SAN FERNANDO VALLEY PEDO/ORTHO OFFICE** – Comput. Pedo/Ortho office. (3) op open bay & (1) op quiet room. Pano eqt'd. Digital X-rays. Cash/Ins/PPO small % Denti-Cal. 30+ years of Goodwill. Annual Gross Collect \$600K+. Seller retiring but will assist with transition and/or stay to do Ortho. **NEW**

**UPCOMING PRACTICES:** Agoura, Alhambra, Beverly Hills, Camarillo, Covina, Corona, Glendora, Montebello, Monrovia, Pasadena, SFV, Torrance, Vista, West Covina & Whittier.

**D & M SERVICES:**

- Practice Sales & Appraisals
- Practice & Equipment Financing
- Expert Witness Court Testimony
- Pre - Death and Disability Planning
- Practice Search & Matching Services
- Locate & Negotiate Dental Lease Space
- Medical/Dental Bldg. Sales & Leasing
- Pre - Sale Planning

P.O. Box #6681, WOODLAND HILLS, CA. 91365  
Toll Free 866.425.1877 Outside So. CA or 818.591.1401 Fax: 818.591.1998  
www.dmppractice.com CA DRE Broker License # 01172430

CA Representative for the National Association of Practice Brokers (NAPB)

**CLASSIFIEDS, CONTINUED FROM 364**

**OFFICE FOR RENT OR LEASE —**

Los Angeles dental office built to share Stunning views of Hollywood Hills and downtown L.A. from 17th floor of a 27-story, recently updated, immaculate, multiuse building. Exclusive use of 2 of the 4 operatories, business desk, private office and sterilization area/supply storage. Shared use of waiting room, lab and break room. Densely built residential and business district with plentiful two-hour metered parking. Great location for building a business near Park LaBrea Towers, The Grove and LACMA. Additional photos available with email reply. Call 323.804.0567 or send email to rjelicich@dslextreme.com.

**DENTAL PRACTICES FOR SALE**

**PRACTICES FOR SALE —** Practice is located in rural northeast California. Beautiful recreation area. 5-year-old equipment, newly remodeled office, 4 operatories, pano, Nobel Biocare implant system, and much more. 3 days of hygiene per week. Collected \$746,000 in 2010 on 5 days per week, \$527,000 in 2011 on 3 days per week. Great Christian staff, reasonable rent. Asking \$175,000. Email ddspractice4sale@yahoo.com for more information.

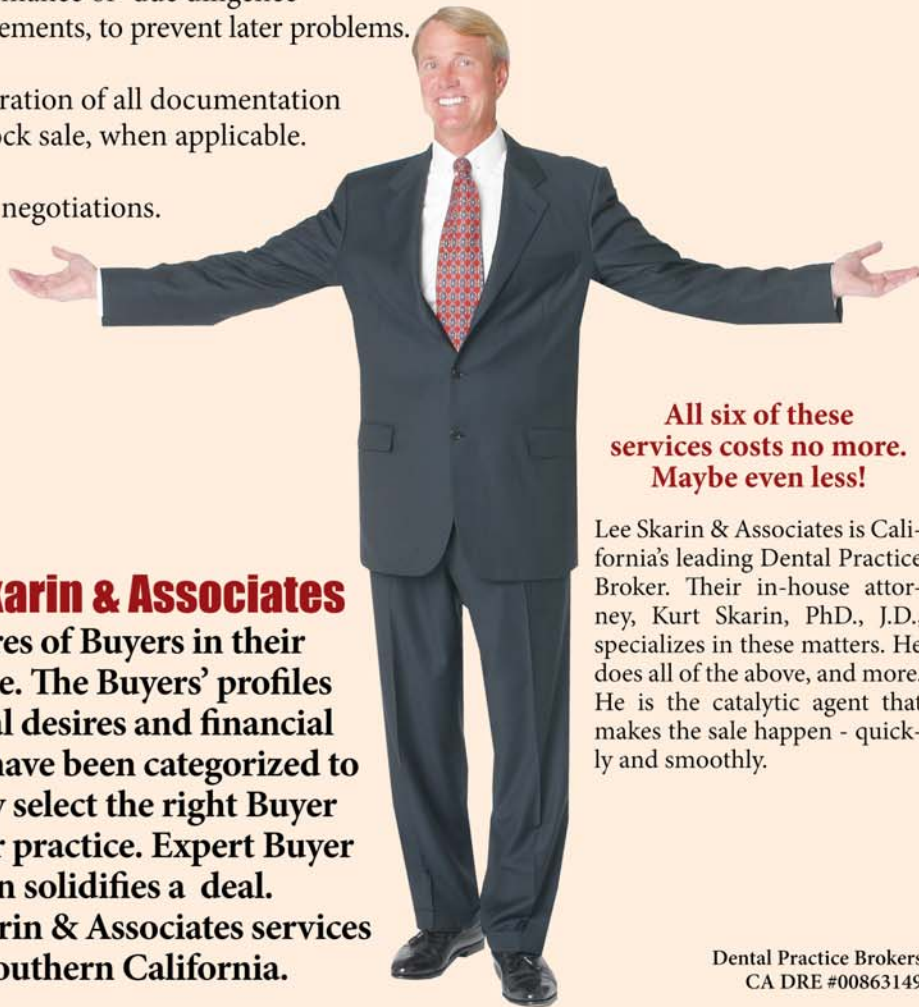
**PRACTICES FOR SALE —** 5 Ops (3 furnished), shopping center, 3 days/week, average 3-year collections is \$572,000. Email caudassoc@aol.com or call broker Steven Caudill for all additional information 951.314.5542.

# SELL YOUR PRACTICE.....

*..... to the right buyer!*

Knowing how, means doing all of the following - with precision:

1. Valid practice appraisal.
2. Contract preparation and negotiations, including critical tax allocation consideration.
3. Bank financing or Seller financing, with proper agreements to adequately protect the Seller and make the deal close - realistically and expeditiously.
4. Performance of "due diligence" requirements, to prevent later problems.
5. Preparation of all documentation for stock sale, when applicable.
6. Lease negotiations.



**Lee Skarin & Associates** has scores of Buyers in their database. The Buyers' profiles personal desires and financial ability have been categorized to expertly select the right Buyer for your practice. Expert Buyer selection solidifies a deal. Lee Skarin & Associates services all of Southern California.

**All six of these services costs no more. Maybe even less!**

Lee Skarin & Associates is California's leading Dental Practice Broker. Their in-house attorney, Kurt Skarin, PhD., J.D., specializes in these matters. He does all of the above, and more. He is the catalytic agent that makes the sale happen - quickly and smoothly.

Dental Practice Brokers  
CA DRE #00863149

*Your calls are invited. Put our thirty years of experience to work for you!*  
Visit our website for current listings: [www.LeeSkarinandAssociates.com](http://www.LeeSkarinandAssociates.com)

# LEE SKARIN & ASSOCIATES INC.



**Offices:**  
**805.777.7707**  
**818.991.6552**  
**800.752.7461**



## ADVERTISER INDEX

California Practice Sales	calpracticesales.net	356
CariFree	carifree.com	325
Carroll & Company Practice Sales	carrollandco.info	363
CDA Membership	cda.org/member	309
CDA Practice Support Center	cdacompass.com	314-315
D&M Practice Sales	dmpractice.com	366
Dental Choice	successfuldentists.ca	348
Implant Direct	implantdirect.com	310
Keller Laboratories	kellerlab.com	371
Lee Skarin & Associates	leeskarinandassociates.com	367
Northbay Networks Inc.	925-385-0562	358
Paragon Dental Practice Transitions	paragon.us.com	362
Practice Transition Partners	practicetransitions.com	360
Professional Practice Sales of the Great West	415-899-8580	365
Professional Practice Transitions	pptsales.com	361
Stratus Dental Group	stratusdental.com/cda	332-333
TDIC	tdicsolutions.com	302
TOLD Partners	told.com	357
Ultradent	ultradent.com	372
Western Practice Sales/John M. Cahill Associates	westernpracticesales.com	342, 355, 359

FOR ADVERTISING INFORMATION, PLEASE CONTACT COREY GERHARD AT 916-554-5304.

DR. BOB, CONTINUED FROM 370

are disposed of for a fee. Car batteries, for example, and used oil from his automobile and his old tires are hauled away at his expense. In his own office, hazardous wastes generated by his patients' needs are hauled away, also at his expense. Never appearing on the dentists' monthly statements are the words:

<i>Sharps Disposal</i>	\$12
<i>Dulls Disposal Carbides</i>	\$15
<i>Diamonds</i>	\$43.50
<i>Disposables Disposal</i>	\$16.95

Second, one of the most lucrative schemes retailers ever palmed off on a gullible public has been operating successfully for ages and once again, that ship has sailed without us. We speak, of course, of the *Extended Warranty or Service Agreement*.

You've just purchased your Kenmore washing machine from Sears; there is no way you will exit the store without being "offered" (see *The Godfather* parts I through IV) a service agreement. The service agreement says, in effect, that although you have purchased this marvelously engineered precision masterpiece of modern day technology from us, it's going to expire, probably the day after the standard warranty ends. The cost of just one out-of-warranty repair visit, say, to replace the interhyperbaric spin cycle configuration module is more than twice the extended warranty fee. So you buy it. There is more pressure to take the service agreement than you would encounter at 40 fathoms without a diving suit.

Never mind that not once has a configuration module failed during the first four years of service even if you had four kids and the interhyperbaric spin cycle thing goes 24/7. But you don't know that. If you should have the moxie to depart the store without surrendering to the salesperson's blandishments, one of their account reps will phone you every three

There is more pressure  
to take the service  
agreement than you would  
encounter at 40 fathoms  
without a diving suit.

months for the rest of your life warning you about the perils of going without the extended warranty. Retailers love the service agreement. So would dentists.

Suppose your fee for full immediate upper and lower prosthesis included the dentures themselves, the insertions and a 20 minute lecture on shrinkage and healing, plus the standard warranty of 10 days or 10 meals, whichever comes first. The extended warranty, or "cash cow" as we would informally come to call it, covers sore spot adjustments up to four the first year, two the second and one on your birthday. It also includes temporary relines and a box of denture adhesive attractively gift boxed. And last, but certainly not least, are two occlusal equilibration visits available upon request even if you haven't the faintest idea of what that means.

This overlooked bonanza would apply equally to crowns, bridges and fillings of every sort. Dentists have always been very careful to avoid guaranteeing anything they do. "It's human tissue," we point out. "Who knows what it's going to do?" Nonsense! What if Sears felt that way about its Craftsman table saws? All that extended warranty/service agreement money would be lost to the provider, foolishly spent by the patient on food or rent or some other frivolous frittering.

If a patient wearing one of our cast partials, or equipped with a mouthful of orthodontic appliances, gets the uneasy

feeling that without the protection of an extended warranty, the whole thing may explode at any moment, then our professional obligation has been met. We've come a long way. Dentists of 50 years ago would never have thought of that.

Eventually dentists could provide service agreements to patients who — if they were lucky — might have no trouble at all. We may poke fun at lawyers and question their activities sometimes, but consider this: Who thought up retainer fees? ■■■■

### We're taking your requests

*If you have a favorite Dr. Bob column you want to see again, email Publications Specialist Andrea LaMattina at [andrea.lamattina@cda.org](mailto:andrea.lamattina@cda.org). We will oblige by reprinting those requested favorites interspersed with any new Dr. Bob submissions.*

# Savoring the Service Agreement



For immediate dentures,  
there is no end, at least not one  
that is mutually recognized by  
both dentist and patient.

➔ Robert E.  
Horseman,  
DDS

ILLUSTRATION  
BY VAL B. MINA

*"Do you — state your name — hereby solemnly swear to take this patient as your own, to have and to hold in sickness and health, through sore spots and relines, in adjustments and remakes from this day forth as long as you both shall live?"*

— EXCERPT FROM THE BIOFORM OATH

Any dentist who has ever performed an immediate denture service for a patient knows the following to be true:

- The patient becomes an *ex officio* member of your family for a minimum of one year. You may not always know where your kids are, but the full immediate patient is always there.
- Sometimes the relationship is forever, or until the dentist mercifully succumbs

to self-inflicted wounds. A frequently used option is the out-of-state move, leaving no forwarding address.

- For most procedures, there is a beginning, a middle and an end. For immediate dentures, *there is no end*, at least not one that is mutually recognized by both dentist and patient.
- The dentist in his naiveté is simultaneously suffused with frustration, despair and anger because he knows that once again professional retailers have made him realize what a chump he has been all these years.

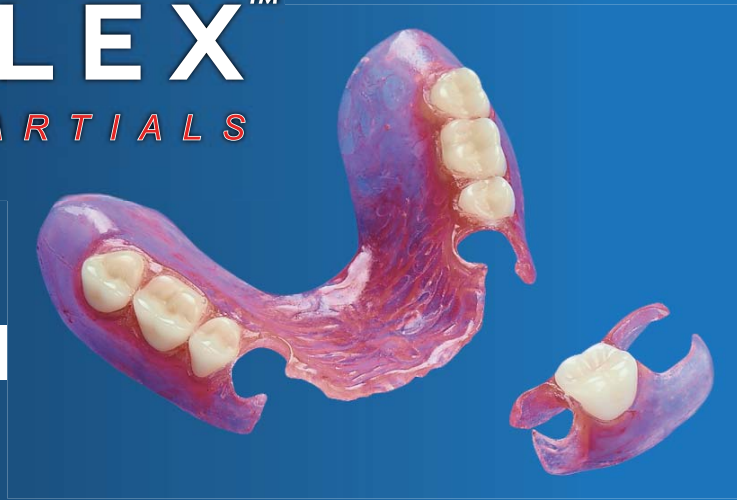First, our dental colleagues discovered that in the real world, hazardous wastes

CONTINUES ON 369

# DURAFLEX<sup>TM</sup>

PARTIALS

the Easier  
Flexible Partial  
*from Keller*



## Why is DuraFlex Easier?

It's made from polyolefin, a thermoplastic polymer that is widely used in medical applications because it is inert, durable, and resistant to many chemical solvents, bases and acids.

- Easier to adjust
- Resistant to stains and odors
- Clinically unbreakable
- Saves chairtime
- Esthetic



• The Keller Difference

CLASSIC  
**\$199**

SELECT  
**\$269**

includes **FREE**  
Sonic Cleaner

BOOMER  
BRIDGE  
**\$169**



Call Today For Your Case Pick-Up!

**800-325-3056**

160 Larkin Williams Industrial Court • Fenton, MO 63026 • [www.kellerlab.com](http://www.kellerlab.com)



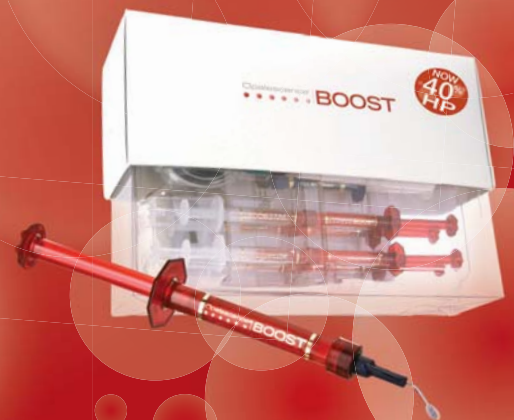

Opalescence® **BOOST**

Be Bright

Opalescence is the smart choice to give your patients the bright, white smiles they've always wanted.

**Because smiles are made to be bright.**



**PROUD USA**  
MANUFACTURER

Ultradent is a proud USA manufacturer. To learn more visit [ultradent.com/USA](http://ultradent.com/USA)



800.552.5512 | [ultradent.com](http://ultradent.com)

©2013 Ultradent Products, Inc. All Rights Reserved.



WHITEN

**ULTRADENT**  
PRODUCTS, INC.  
Improving Oral Health Globally