

3-D Volume Imaging for Dentistry: A New Dimension

Robert A. Danforth, DDS; Ivan Dus, MD, DDS, PhD;
and James Mah, DDS, MS, DMSc

Abstract

The use of computed tomography for dental imaging procedures has increased recently. Use of CT for even seemingly routine diagnosis and treatment procedures suggests that the desire for 3-D imaging is more than a current trend but rather a shift toward a future of dimensional volume imaging. Recognizing this shift, several imaging manufacturers recently have developed 3-D imaging devices specifically for dental purposes using cone-beam computerized tomography. This technology allows for 3-D imaging similar to CT, but at lower equipment cost, simpler image acquisition and lower patient radiation dose. Herein, an overview of these devices is provided such that potential users can be better informed about this emerging technology.



omputed tomography (CT) provides valuable 3-D imaging of the dental and maxillofacial structures for diagnosis and treatment planning. In the past, such imaging has been utilized for complex surgical cases, but widespread use of CT for dental implant imaging has made it more common. Several recent reports have described additional uses of CT imaging for assessment of impacted teeth,^{1,2} root configurations,³ and mandibular condyle evaluation.⁴

CT examination is one of the most valuable medical imaging modalities available. Its use in the U.S. has risen from 5-5.5 million examinations in 1983 to more than 20 million in 1995.⁵ CT examinations comprised about 2 percent of all radiographic examina-



Authors / Robert A. Danforth, DDS, is assistant professor of clinical dentistry at the University of Southern California School of Dentistry, Division of Diagnostic Sciences/Oral Radiology.

Ivan Dus, MD, DDS, PhD, is assistant professor at Loma Linda University School of Dentistry, Department of Orthodontics and has a private practice in Pordenone, Italy.

James Mah, DDS, MS, DMSc, is assistant professor at the USC School of Dentistry, Division of Craniofacial Sciences and Therapeutics.

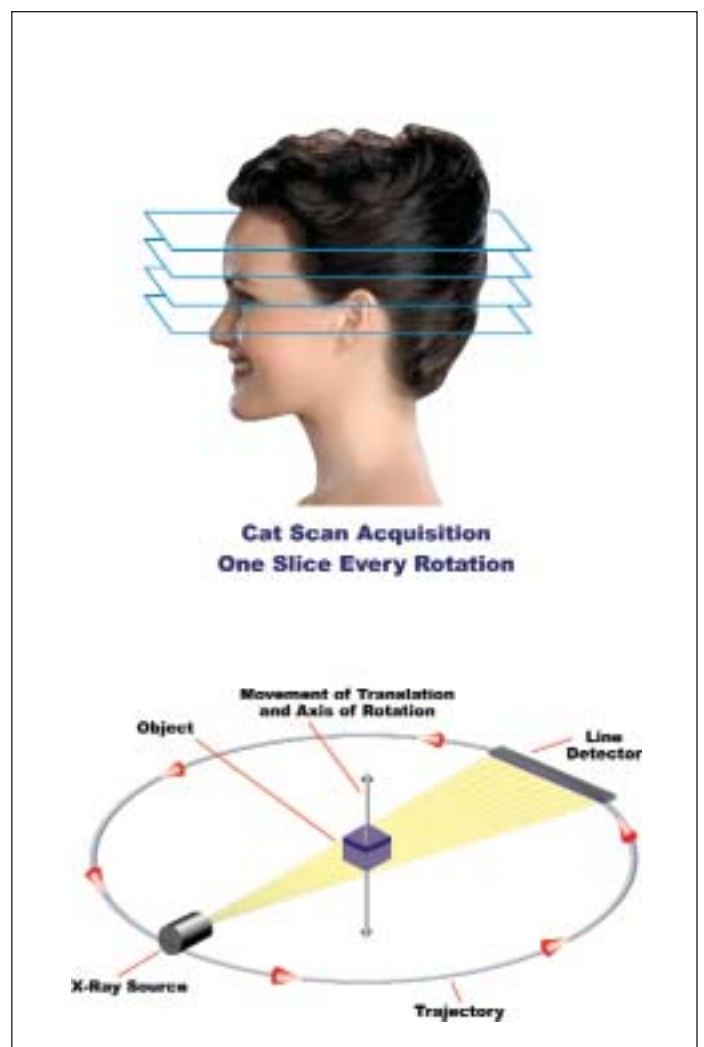



Figure 1a.

Figure 1b.

Figures 1a and b. Differences in image acquisition between cone beam volume tomography (A) and traditional computed tomography (CT) (B).
Courtesy of Dr. Ivan Dus and Dr. Carl Gugino, Aperio Services, Inc. Sarasota, Fla.

tions in 1991 and in 2001 comprised 10 percent to 15 percent of the total.⁵ If this trend in medicine is followed in dentistry, the demand for 3-D dental imaging devices can be expected to follow; hence, the development of 3-D imaging devices specifically for dental and maxillofacial use.

Currently, several machines are ei-

ther commercially available or FDA approval pending. It is important to distinguish these new technologies and devices from traditional medical CT devices as they are not the same. The technology is described as either cone beam computerized tomography (CBCT), or preferred for this report cone beam volumetric tomography (CBVT). The pur-

pose of this article is to provide an introduction to these imaging machines and describe the differences between these and medical CT. CBVT systems developed for dentistry include: Newtom QR 9000 and the upcoming Newtom Plus, (Aperio, Inc., Sarasota, Fla.), 3-D Accuitome, (J. Morita, Tokyo, Japan), MercuRay, (Hitachi, Tokyo, Japan) and

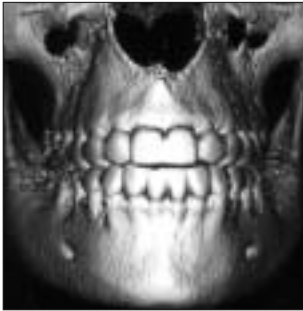

Figure 2a.

Figures 2a and b. Comparison of full maxillofacial-mandibular coverage to a regional volume. A. Courtesy of Dr. James Mah, University of Southern California. B. Courtesy of Dr. Edgar Hirsch, Universität Leipzig, Germany and J. Morita, Irvine.

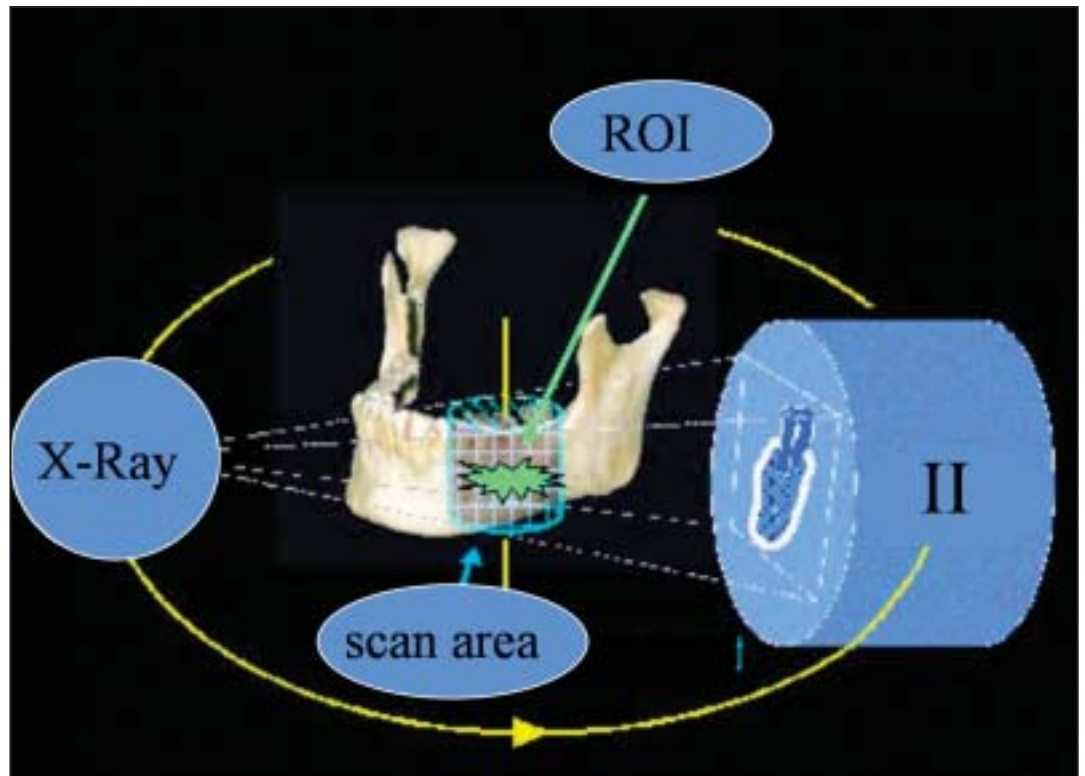


Figure 2b.

the ISI/CAT, (Imaging Science International, Hatfield Penn., and Xoran Technologies, Ann Arbor, Mich.).

Cone Beam Volume Tomography

The two principle differences that distinguish CBVT from traditional CT are the type of imaging source-detector complex and the method of data acquisition. **Figures 1a** and **1b** illustrate the basic difference between these two technologies. The X-ray source for CT is a high-output rotating anode generator while that for CBVT can be a low-energy fixed anode tube similar to that used in dental panoramic machines. CT employs a fan-shaped X-ray beam from its source for imaging and records the data

on solid-state image detectors arranged in a 360-degree array around the patient. CBVT technology uses a cone-shaped X-ray beam with a special image intensifier and a solid-state sensor or an amorphous silicon plate for capturing the image.^{6,7,8,9} Development of this technology dates back to the mid 1970s when it was originally devised as a cost-effective and efficient method for obtaining cross-sectional 3-D imaging for radiotherapy and later angiography.¹⁰⁻¹³

Conventional medical CT devices image patients in a series of axial plane slices that are captured either as individual stacked slices or from a continuous spiral motion over the axial plane. When compared to conventional CT, image capture with spiral motion is

quicker and can be done at a much lower radiation dose.¹⁴ (Although the ICRP warns that this is more so a function of the scan volume, mAs, pitch and slice width.⁵) Conversely, CBVT presently uses one rotation sweep of the patient similar to that for panoramic radiography. Image data can be collected for either a complete dental/maxillofacial volume or limited regional area of interest. Scan times for these vary from 75 to 40 seconds for the complete volume to 17 seconds for the regional. Currently, patient exposure effective dose has been determined only for the Newtom 9000 complete volume system. This can be as low as 50 μ Sv or in a similar range to that for a dental periapical full-mouth series using current tech-

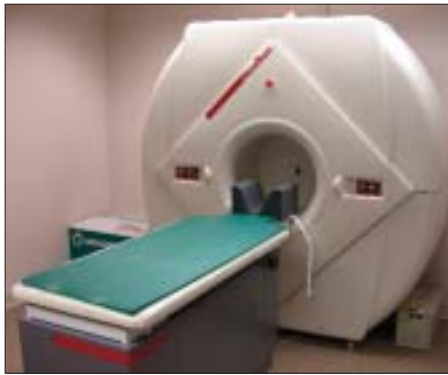

Figure 3a.

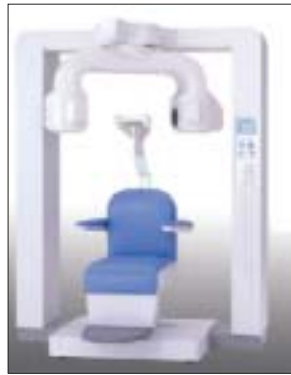

Figure 3b.

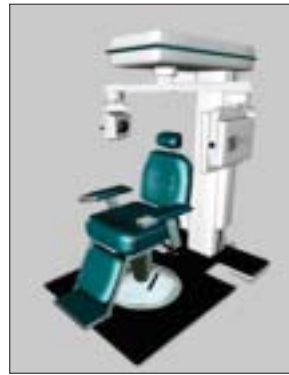

Figure 3c.



Figure 3d.

Figures 3a-d. Models of 3D maxillofacial radiology imaging machines.

A. Courtesy Dr. James Mah, University of Southern California. B. Courtesy of Dr. Edgar Hirsch, Universität Leipzig, Germany and J. Morita, Irvine. C. Courtesy Arun Singh, Imaging Sciences International, Hatfield, Penn., Xoran Technologies, Ann Arbor, Mich. D. Courtesy Tricia Winter, Hitachi Medical Systems America, Inc., Twinsburg, Ohio.

niques.^{15,16} From the perspective of radiation dosimetry, these new developments in specific CTs for dentistry are very much welcomed as radiation dose from medical CT has not decreased in the last decade while radiation dose from other forms of medical radiography has decreased by 30 percent.⁵

Although the concept of 3-D imaging for dental systems is similar to that for the medical CT scanner, the methods and terms used to describe the technology differ. The term 3-D cone beam volumetric tomography better describes the emerging dental and maxillofacial machines. Systems can be categorized as either full volume maxillo-mandibular tomography (Figure 2a) or regional volume tomography (Figure 2b). A full-volume scan encompasses the entire volume of anatomy from approximately the lower orbital rim to just below the inferior border of the mandible while the regional is confined to a portion of one dental quadrant or regional area of interest. Some machines are restricted to either one of the methods while others offer full or regional options. These are shown in

Figures 3a-d. As can be seen, the Newtom QR 9000 images the patient in a supine position with a CT-like opening in the gantry sufficient to accommodate only the head and neck. The other units superficially have a dental panoramic machine appearance with the patient sitting upright. All acquire image data using a single 360-degree imaging rotation around the patient.

Comparative Technology

Table 1 compares specifications for these maxillofacial CBVT machines with traditional CT. As can be seen, all of the maxillofacial CBVT units share common features in regard to X-ray beam, sensor detection, X-ray exposure parameters and method of image acquisition. These are dramatically different than for CT which is designed for more extended areas of coverage. Some differences between the CBVT machines exist. Scan time varies with either the full or regional image volumes. Resolution expressed as mm³ voxel size tends to favor the regional devices. The reported effective exposure dose is associated with dental implant imaging because it is most compa-

able to CT. The figures listed for effective dose were provided from the manufacturer and are not truly comparable due to variables such as different size of imaging volumes and operational settings of the devices. For those machines with such data, it can be seen that effective radiation dose associated with CBVT maxillofacial imaging is greatly reduced from that of CT for similar purposes. Likewise, differences with CT exist in the safety operation of these units. Automatic exposure control adjust the amount of X-ray radiation based upon tissue density to ensure imaging data are properly collected and an emergency stop mechanism terminates the scanning process if inconsistent exposure values are detected during the operation.

A composite of representative image examples are shown in Figures 4a-i. As can be seen, many different image views of the patient are possible. While the common panoramic, implant, and TMJ views are present, Figures 4a-c, it is volumetric reformatting, Figures 4d-i, that demonstrate the new dimension in imaging. Figure 4d reveals a mandibular third molar

Table 1

Comparison of Maxillofacial CBVT Devices

Parameters	Newtom 9000	Newtom Plus	3DX Accuitomo	ISI/CAT	Hitachi MercuRay	MedicalCT
X-ray beam	cone	cone	cone	cone	cone	fan
Sensor detector	area image intensifier CCD	area image intensifier CCD	area image intensifier CCD	area amorphous silicon flat-panel detector	area image intensifier CCD	linear Solid state or gas
Grayscale	8 bit	12 bit	8 bit	12 bit	8 bit	12 bit
Voxel size (mm ³)	0.265	0.07-0.20 (variable)	0.125	0.4 typical 0.2 minimum	0.1	0.3 ¹⁶
X-ray source			direct current	direct current		
anode	fixed	fixed	fixed	fixed	fixed	rotating
kVp range	110 (fixed)	110 (max)	60-80	120	70-100	110-140
mA	10 15 max		1-10	1-3	to 15 max	80-300
Image acquisition	panoramic type single 360° rotations	panoramic type single 360° rotations	panoramic type single 360° rotations	panoramic type single 360° rotations	panoramic type single 360° rotations	axial slices multiple 360° rotations
Patient position	supine	supine	seated	seated	seated	supine
Image area	maxillofacial	maxillofacial	maxillofacial	maxillofacial	maxillofacial	entire body
Dimensions (cm)	13x13 (height x diameter)	22x25 (height x diameter)	3.0x4.0 (height x diameter)	2 versions 11x17 17x17 (height x diameter)	D mode 5.12 P mode 11.7 C mode 15.0 (height only)	varies/exam
Imaging session (sec)	75	30 or less	17	40 or less	9.6	varies/exam
Effective dose* (max_& mand) mSv	.04-.05 ¹⁵	.01-.02	.0074	not available	not available	.289 low ¹⁷ .723 high ¹⁷
Auto exposure control	smart scan yes	smart scan yes	no	not reported	not reported	no
Commercially available	yes	end of 2003/early 2004	yes	projected 2004	not reported	yes

*Effective dose as reported is provided from the manufacturer and is not truly comparable to other devices due to variable such as different size of imaging volumes and operational settings of the devices.

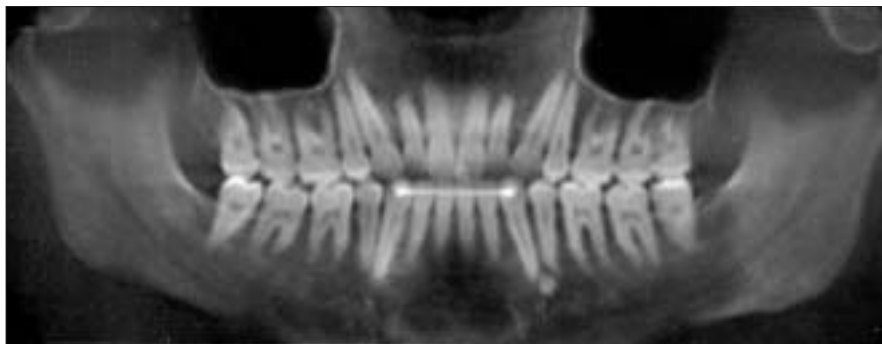


Figure 4a.

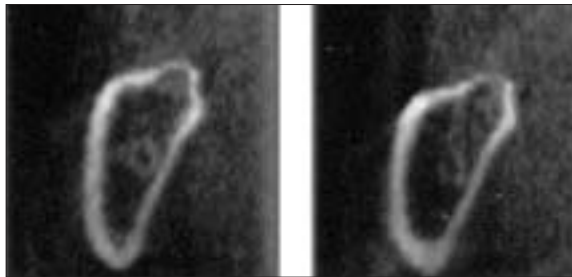


Figure 4b.

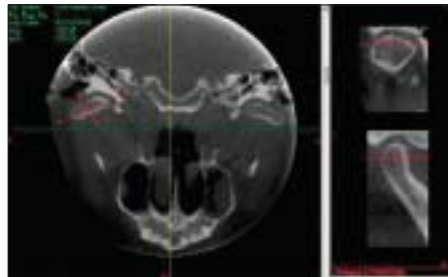


Figure 4c.

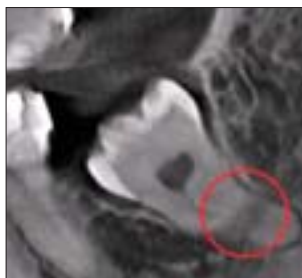

Figure 4d.

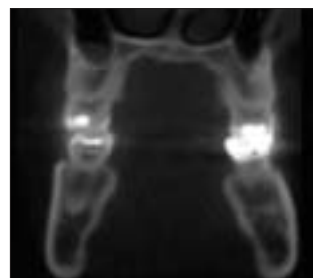

Figure 4e.

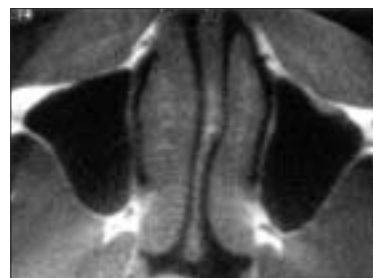

Figure 4f.

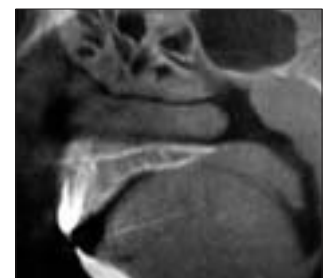


Figure 4g.

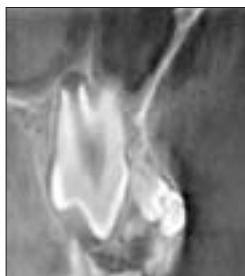

Figure 4h.

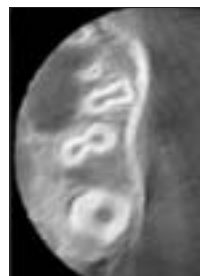

Figure 4i.

and its relationship to the inferior alveolar canal; **Figure 4e** is a cross-sectional arch view; **Figures 4f-g** are representative of the many possible airway images; **Figure 4h** shows a supernumerary tooth; and **Figure 4i** shows root configurations and spatial relationships. Each of these images is but one of many that comprises the 3-D volume for any anatomical area being examined. In addition, computer-generated models can be reconstructed from the initial imaging data. Examples are

Figures 4a-i.

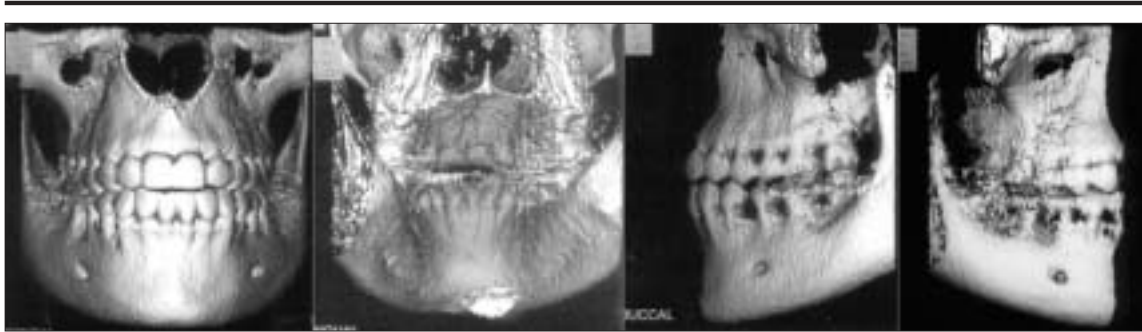Representative examples of volume imaging using maxillofacial CBVT machines. A: Reconstructed panoramic. B: Cross-sectional mandibular nerve canal. C: TMJ images. D: Impacted molar-nerve canal. E: Airway-sinus, nasal fosse. F: Bimaxillary cross-section. G: Airway-sinus, nasal fosse. H: Upper airway, lateral view. I: Supernumerary teeth. J: Root configurations.

Courtesy of Redmond Imaging Center, University of Southern California. Courtesy of Dr. Edgar Hirsch, Universität Leipzig, Germany and J. Morita, Irvine. Courtesy of Arun Singh, Imaging Sciences, Hatfield, Pa., Xoran Technologies, Ann Arbor, Mich.

shown in **Figures 5a-d**. The posterior palatal/lingual view, not readily available with traditional dental radiography, is demonstrated in **Figure 5b**. Views from the posterior are unique to volume imaging and offer the possibility to replace viewing stone models for this function.

Summary

Four CBVT 3-D imaging systems have been recently developed for dentistry. Multiple image views, various measurement analysis, and computer-



Figures 5a-d. Computer-generated models from reconstructed image data.
 Courtesy of Redmond Imaging Center, University of Southern California School of Dentistry.

generated patient models, all of which allow the diagnostician to better visualize in a "spatial plane concept" potential therapeutic procedures before they are actually rendered is perceived as the next progressive step in dental imaging. While primarily intended for dental implant imaging, Figures 4 and 5 show the different aspects of dental diagnosis that could benefit from 3-D imaging.

This progressive step does not mean 3-D imaging will replace traditional radiology. There are some factors to consider when deciding whether or not 3-D imaging should be used. Image resolution for 3-D imaging is less than film. The machines are expensive ranging from \$200,000 to \$300,000 and are generally available only in imaging centers or larger dental practices. This reduces patient access and the cost of the imaging examination is usually greater than for film. Patient radiation dose is lower than for conventional medical CT, but is similar to that for standard dental radiology. This would be an advantage for dental implant patients but not necessarily for others. Not all imaging examinations will be successful. No patient movement is critical for success and patients unable to comply are not candidates for 3-D imaging. Also, there will be a learning

curve for dentists unfamiliar with reading multiple plane images.

Despite these limitations, there is a role for this technology. CBVT imaging can provide a much-needed 3-D perspective in certain cases that require more information than can be obtained from traditional radiography. Examples of applications of CBVT in diagnosis and treatment planning are in dental implant placement, TMJ conditions, jaw tumors, airway analysis, impacted teeth, periodontal or endodontic problems.

This article provides a brief introduction to these emerging machine so that any potential user can be better informed about the differences between these and traditional CT. **CDA**

References / 1. Preda L, La Fianza A et al, The use of spiral computed tomography in the localization of impacted maxillary canines. *Dentomaxillofac Radiol* 26(4):236-41, 1997.
 2. Ericson S, Bjerklind K. The dental follicle in normally and ectopically erupting maxillary canines: a computed tomography study. *Angle Orthod* 71(5):333-42, 2001.
 3. Robinson S, Czerny C et al, Dental CT evaluation of mandibular first premolar root configurations and canal variations. *Oral Surg Oral Med Oral Pathol Oral Radiol Endod* 93:328-32, 2002.
 4. Berna L, and Kansu O. Trifid mandibular condyle: A case report. *Oral Surg Oral Med Oral Pathol Oral Radiol Endod* 95:251-4, 2003.
 5. International Commission on Radiological Protection. Publication 87. Managing Patient Dose in Computed Tomography. Oxford: Pergamon Press. Annals of the ICRP Vol. 30/4, 2001
 6. Mozzo P, Proccacci A et al, A new volumetric CT machine for dental imaging based on the

cone-beam technique: preliminary results. *Eur Radiol* 8:1558-64, 1998.

7. Dus I. Why the Newtom is not a CT scanner. Document report, Aperio, Inc. Oct. 2002.
 8. Yamamoto K, Ueno K, Seo K, Shinohara D. Development of dento-maxillofacial cone-beam X-ray CT system. COAST Foundation Conference: Craniofacial Imaging in the 21st Century. Book of Abstracts, p.18, 2002
 9. <http://www.imagingciences.com/html/products/productFD.htm> Sept. 2003
 10. Harrison RM and Farmer FT. The determination of anatomical cross-sections using a radiotherapy simulator. *Br J Radiol* 51:448-53, 1978.
 11. Arnot RN, Willetts RJ et al, Investigation using an X-ray image intensifier and a TV camera for imaging transverse sections in humans. *Br J Radiol* 57:47-55, 1984.
 12. Cho PS, Johnson RH, and Griffin TW. Cone-beam CT for radiotherapy applications. *Phys Med Biol* 40:1863-83, 1995.
 13. Saint-Felix D, Troussat Y et al, In vivo evaluation of a new system for 3D computerized angiography. *Phys Med Bio* 39:583-95, 1994.
 14. Goaz PW and White SC. *Oral radiology: Principles and Interpretation*, third ed, Mosby, St. Louis 1994, pg. 280.
 15. Hatcher D. Newtom 9000. *AADMRT Newsletter Summer* 2:1, 16-7, 2002.
 16. Mah J, Danforth RA, and et al, Radiation absorbed I maxillofacial imaging with a new dental CT. *Oral Surg Oral Med Oral Pathol Oral Radiol Endod* In press.

17. Arai Y, Tammissalo E, et al, Development of a compact computed tomographic apparatus for dental use. *Dentomaxillofac Radiol* 28:245-8, 1999.

18. Homolka P, Gahleitner A, and et al, Methode zur Abschätzung der effektiven Dosis bei Dental-CT. Konversionsfaktoren und exemplarische Berechnung für ein klinisches Low-Dose-Protokoll. *Fortschr Röntgenstr* 173:558-62, 2001.

To request a printed copy of this article, please contact / Robert A. Danforth, DDS, University of Southern California School of Dentistry, Division of Diagnostic Sciences, 925 W. 34th St., Los Angeles, Calif., 90089-0641.