

Clinically Based Diagnostic Wax-up for Optimal Esthetics: The Diagnostic Mock-up

HAREL SIMON, DMD, AND PASCAL MAGNE, DMD, MSC, PHD

ABSTRACT A diagnostic wax-up can enhance the predictability of treatment by modeling the desired result in wax prior to treatment. It is critical to correlate the wax-up to the patient to avoid a result that appears optimal on the casts but does not correspond to the patient's smile. This article reviews the applications and techniques for clinically based diagnostic wax-up, and focuses on the diagnostic mock-up philosophy as a means to obtain predictable esthetics and function.

AUTHORS

Harel Simon, DMD, is a prosthodontist, clinical associate professor, University of Southern California School of Dentistry, and in private practice in Beverly Hills, Calif.

Pascal Magne, DMD, MSC, PHD, is associate professor, Don and Sybil Harrington Foundation chair in esthetic dentistry, Division of Primary Oral Health Care, University of Southern California School of Dentistry.

ACKNOWLEDGMENTS

The authors would like to acknowledge Takanori Tani, CDT; Masahiro Kitsukawa, CDT; and Take Katayama, CDT, from Dentech International for the laboratory work presented in Figures 1, 5 and 6; and Michel Magne, CDT, for the work presented in Figure 7.

Obtaining a predictable esthetic result is one of the goals of prosthodontic and restorative dental treatment. Esthetic and functional treatment outcomes should be known prior to placement of a definitive restoration. Respecting this principle will prevent major disappointments and unnecessary remakes.¹ A diagnostic wax-up has been advocated to enhance the predictability of the treatment.²⁻⁵

Definition

A diagnostic wax-up is defined by the glossary of prosthodontic terms as a dental diagnostic procedure in which planned restorations are developed in wax on a diagnostic cast to determine optimal clinical and laboratory procedures necessary to achieve the desired esthetics and function.⁶ The result of this pro-

cess, the wax-up, is a 3-D model of teeth built in wax that represent the desired contours of the teeth to be restored.

Applications

The diagnostic wax-up is a tool that can be used for diagnosis and treatment of dentate patients, partially edentulous, and completely edentulous patients using wax or denture teeth set in wax as media.⁷ This tool can provide important diagnostic information that will indicate the need for a specific treatment.^{2,8} It can assist in the selection of proper restoration and determine the need for preprosthetic surgery, periodontal, orthodontic, or endodontic treatment. The wax-up can assist in estimating the amount of restorative space available and point out any need for treatment in the opposing arch to obtain such space. It can help in evaluating the planned occlusal scheme

and indicate which modifications are needed in the remaining dentition.⁹

A well-made diagnostic wax-up can be used as means of communication between the clinician, the technician, and the patient illustrating the tentative plan three-dimensionally and allowing modifications in a reversible way.^{10,11} It can be used as a patient education tool and as means to facilitate acceptance and approval of indicated treatment.^{5,7}

The diagnostic wax-up can also be utilized as a treatment tool. In edentulous spaces, the diagnostic wax-up can be used to form radiographic and surgical implant placement guides. In fixed prosthodontics it can be used to make a tooth preparation guide creating a vacuum-formed template or silicone matrix from the wax-up. This will guide tooth reduction according to the contours prescribed by the wax-up.^{2,8,12-14} This type of matrix can be used subsequently to create a provisional restoration based on the wax-up.^{2,8,12,13} This provisional restoration will be a prototype of the definitive restoration testing the design established by the wax-up.

While a fixed provisional restoration can be used over a period of time to evaluate esthetics and function, a provisional restoration for porcelain veneers has a short life span due to limited retention and is consequently not well suited for that purpose. Furthermore, preparations for porcelain veneers, unlike conventional crowns, should ideally be less than 1 mm thick to preserve as much enamel and remaining tooth structure as possible. Such precision can be achieved when the exact contours of the definitive restoration are known prior to tooth preparation. Therefore, patients undergoing porcelain veneer treatment will require meticulous evaluation prior to the preparation and provisionalization stage.^{15,16}

It is important to differentiate be-

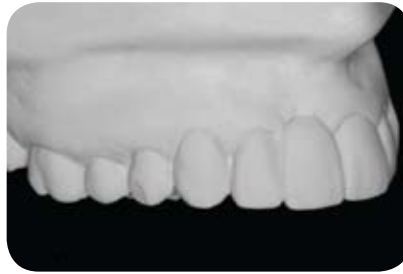


FIGURE 1A. Diagnostic casts demonstrating deficient gingival architecture.

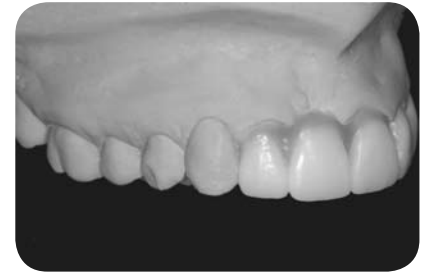


FIGURE 1B. Diagnostic wax-up of teeth and soft tissue demonstrating adequate tooth proportions and illustrating the need for gingival augmentation or gingiva-colored ceramics.

tween a diagnostic wax-up of individual teeth in an arch of properly positioned teeth to one made for an arch of malpositioned teeth. In the first case the teeth to be restored simply need to be shaped in wax while the remaining teeth act as a guide. In the second case, the remaining teeth may be worn down, supraerupted or malpositioned, and in order to design the wax-up of the teeth to be restored, the correct position of the remaining teeth needs to be re-established. In fact, the process of making a diagnostic wax-up in the latter case may indicate that additional treatment needs to be rendered to restore other teeth that interfere with the restorative space, occlusal scheme, or esthetics. This is the most important function of a diagnostic wax-up — it provides diagnostic information that affects the treatment plan.^{2,10}

The diagnostic wax-up generally is being performed by a dental technician who is trained, experienced, and skilled in manipulating wax to form anatomically shaped teeth. However, without seeing the patient and without exact instructions regarding tooth length, width, position and inclination, the diagnostic wax-up becomes guesswork.¹⁷

When clinical guidance is unavailable, technicians use landmarks on the diagnostic casts to guide the waxing. Such landmarks may be the existing occlusal plane and the length and position of the remaining teeth. While this may work in some instances, it may introduce considerable error in other situations.

If the remaining teeth are not in proper positions in relation to the patient's lips or other facial structures, they could act as an incorrect guide. This type of a wax-up may be misleading and of little clinical value. Although it illustrates anatomically correct teeth that appear acceptable on the cast, the teeth may not match the patient and may not represent the desired result that the clinician and the patient expected. If teeth are to be prepared for fixed restorations or implants are to be placed according to this wax-up, the result may be unpredictable.

For previously stated reasons, the dental technician should be involved directly with the patient at the diagnostic phase. A direct dialogue between the patient and the technician, without the clinician as mediator, has been suggested to ensure success.¹⁰ Unfortunately, this approach may not be practical for every clinician or technician and therefore is not widely utilized. It is, therefore, extremely important to obtain as much clinical information as possible prior to the wax-up in order to create a clinically based diagnostic wax-up.

The information should be communicated with the technician to guide the waxing. The following factors would be important to relay to the technician: incisal edge position, midline, teeth length, width, and CEJ position. The potential need for soft tissue augmentation is considered and requested as a gingival tissue wax-up to evaluate the need for gingiva-colored ceramics¹⁸ (FIGURES 1A-B). The desired incisal guidance is documented and

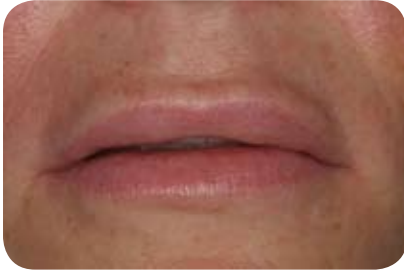

FIGURE 2A. Patient presented with a desire to improve her smile: Rest position.

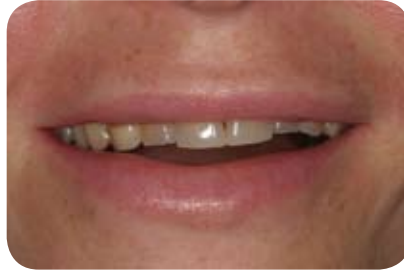

FIGURE 2B. Smile demonstrating inadequate incisal display.

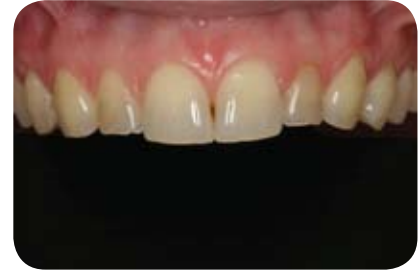

FIGURE 2C. Consequence of excessive tooth wear.

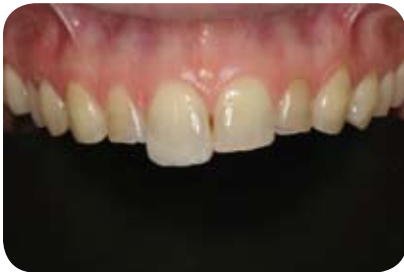

FIGURE 2D. Composite mock up done on the maxillary right central incisor to determine incisal edge position.

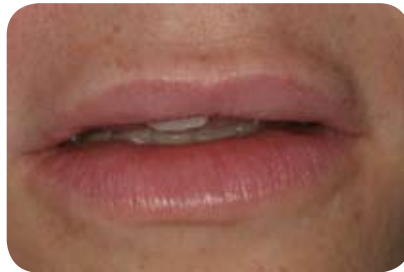

FIGURE 2E. Mock-up evaluated at rest position.

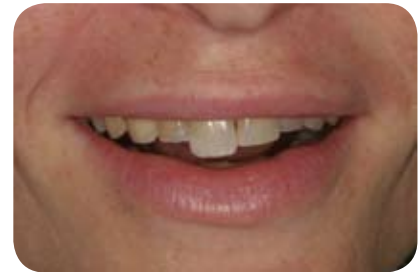

FIGURE 2F. Mock-up at smile.

the correct occlusal scheme is prescribed.

This article will discuss methods to predictably communicate desired teeth contours and positions to be waxed according to information obtained clinically. This will allow the formation of an accurate and clinically valid diagnostic wax-up for a predictable esthetic result.

Obtaining Clinical Information

FREEHAND METHOD

Using this technique, the desired positions of the teeth are communicated in relation to the existing dentition. The technician is instructed to wax the teeth while modifying the length, width, or midline of the existing teeth by a given amount in relation to the existing condition. This method can be practical when only limited alterations to the existing dentition are needed.

DIAGNOSTIC MOCK-UP

A diagnostic mock-up is the clinical equivalent of a laboratory made diagnostic wax-up.¹⁹ In this approach, the

teeth are being modeled intraorally using a tooth-colored material in a reversible way to demonstrate the desired esthetic result. Although a direct intraoral waxing technique using wax over the natural teeth has been documented, the use of tooth-colored resin materials seems to be more practical.²⁰ It is important to select a proper tooth-colored material to avoid any bias, since perception of shape may be influenced by opacity and color. This procedure can be done before or after the diagnostic wax-up.

Types of Diagnostic Mock-ups

PRELIMINARY DIAGNOSTIC MOCK-UP

A preliminary diagnostic mock-up is a powerful tool to obtain clinical information in a simplified way prior to the diagnostic wax-up.^{5,15,16} In this technique, composite resin is used freehand intraorally to contour one or more teeth and evaluate the affect on the patient's appearance. This allows the clinician to visualize the change and see if the tentative teeth contour and position

integrate with the face and lips (FIGURES 2A-F). Different lip positions can be evaluated to confirm an acceptable smile and rest position. Phonetic tests can be performed to evaluate the tentative incisal edge position vertically and buccolingually in relation to the vermillion border of the lower lip in F,V sounds.²¹ At the same time, potential alteration in phonetics can be observed and discussed with the patient as adaptation to the new position will be required.^{15,16}

In many cases, the patient may not be able to perceive the clinician's diagnosis and treatment plan without a visual aid. In those cases, the mock-up would be a critical step in educating the patient without which, treatment would not be performed.

The mock-up procedure is completely reversible and is done without any tooth preparation, without acid etching or bonding to the teeth. The composite is simply placed on the teeth in a freehand technique and contoured to become a guide for the wax-up. If there is any existing composite resin on the teeth, it

should be lightly lubricated to prevent adhesion to the mock-up. The mock-up can be evaluated prior to polymerization and contoured while still malleable, according to feedback obtained clinically. When the desired position has been obtained it is allowed to polymerize.

The procedure may begin by first contouring the central incisor to establish incisal edge position and midline, and obtain patient acceptance. Intentional excessive lengthening or shortening of the mock-up can be done to allow a discerning patient to visualize the difference and feel confident with his or her decision. If esthetic evaluation suggests lengthening of the tooth gingivally, a mock-up of the gingival margin of the tooth can be done to illustrate crown lengthening. This can be done by temporarily extending the composite resin from the teeth onto the tissue to form a new gingival margin (FIGURES 3A-B). On the other hand, if deficient gingival architecture is presented, gingiva-colored composite resin can be used over the teeth to illustrate gingival augmentation procedures or the future need of gingiva-colored ceramics (FIGURES 4A-B).¹⁸ Shortening of the incisal edge position can be illustrated, if necessary, using a black marker to create an illusion of a shorter tooth.⁵

Following this, additional teeth may

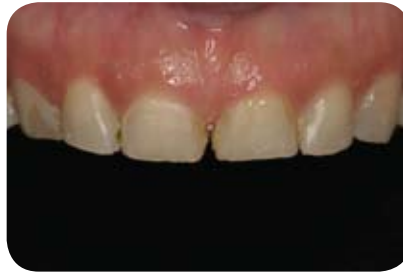

FIGURE 3A. Severe incisal wear combined with supra-eruption that altered the gingival margin position.

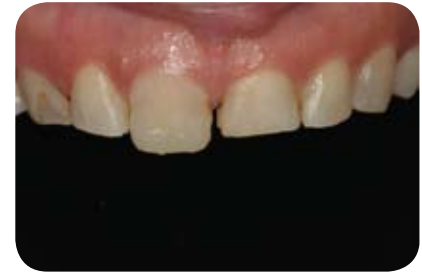

FIGURE 3B. Direct composite resin mock-up of the incisal edge position and gingival margin location allowed the patient to visualize the tentative plan.

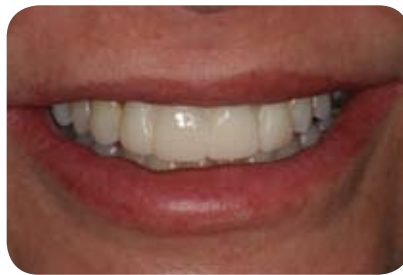

FIGURE 4A. Deficient gingival architecture is evident in a provisional restoration of patient presented in Figure 1a.

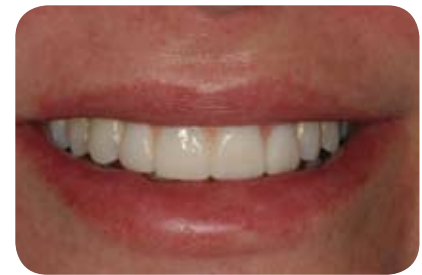

FIGURE 4B. Direct mock-up is made on the provisional with gingiva-colored composite resin and is evaluated at smile to approve a diagnostic wax-up of teeth and gingival tissue presented in Figure 1b. This mock-up enables the clinician and the patient to visualize the use of gingiva-colored ceramics in the definitive prosthesis or discuss the option of soft tissue augmentation.

be included in the mock-up to demonstrate to the patient the proposed changes. Photographs documenting the new incisal edge position at rest and smile in relation to the lips may be taken. Additional photographs capturing the patient's face and profile could assist in matching teeth contours to facial features. These photographs capture essential clinical details and communicate important information that sometimes cannot be verbalized. Impressions with the composite mock-up in place can be made and poured in stone. Upon completion, the composite mock-up

can be easily flaked off the teeth and saved for future reference (FIGURE 5A). The information is gathered and sent to the laboratory. The cast of the arch with the composite mock-up will be used by the technician as a clinically based guide for the diagnostic wax-up (FIGURE 5B).

The technician will create a diagnostic wax-up that follows the teeth that were built in the mock-up and will extend it to the remaining dentition

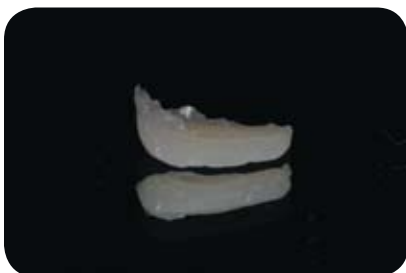

FIGURE 5A. Composite mock-up (from Figure 2) removed intact from the tooth.

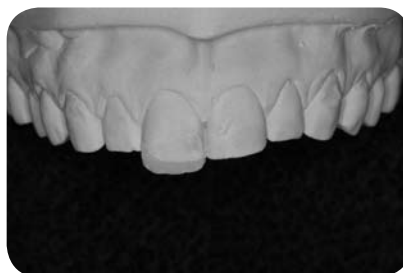

FIGURE 5B. Mock-up placed on the diagnostic cast.

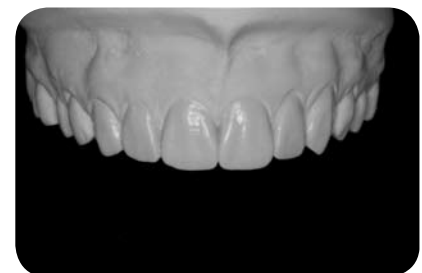

FIGURE 5C. Wax-up is made based on information obtained from diagnostic mock-up.

to be waxed (**FIGURE 5C**). This will be a refined version of the mock-up featuring proper contours, anatomy, and surface texture. Such diagnostic wax-up that is clinically based can be accurately used to diagnose additional conditions and guide the treatment predictably.

SECONDARY DIAGNOSTIC MOCK-UP

An additional diagnostic mock-up procedure has been documented in the literature.^{2,13,15,16,22,23} This mock-up, which is sometimes being referred to as overlay prosthesis, is done after the diagnostic wax-up has been made. It is formed using a silicone matrix made from the diagnostic wax-up (**FIGURE 6A**). The matrix is filled with autopolymerizing resin (**FIGURE 6B**), placed over the unaltered natural teeth and removed upon final polymerization. The resin mock-up typically remains on the teeth as it is mechanically retained in undercuts (**FIGURE 6C-E**).

This procedure reproduces the wax-up onto the natural teeth for immediate clinical evaluation. It tests the final design details of the diagnostic wax-up clinically prior to any teeth preparation. It is an extremely valuable tool to fine-tune the desired configuration and contour of the planned restorations.

If necessary, it can be modified once again with direct composite and communicated with the technician using photographs and casts of the desired results. The procedure can be repeated until the desired result is acceptable to the patient and the restorative team (**FIGURES 6F-N, 7A-J**).

While a mock-up is typically made intraorally over the intact dentition, it can alternatively be made indirectly by the laboratory on an unaltered cast to be evaluated later intraorally by the clinician.^{2,3,17,22,23}

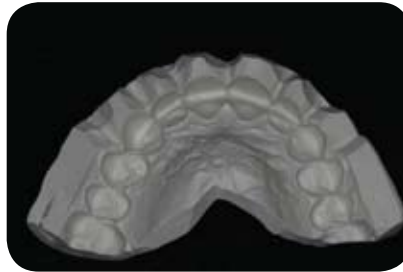


FIGURE 6A. A silicone matrix made from the diagnostic wax-up in Figure 5c is trimmed to facilitate creation of a secondary mock-up.

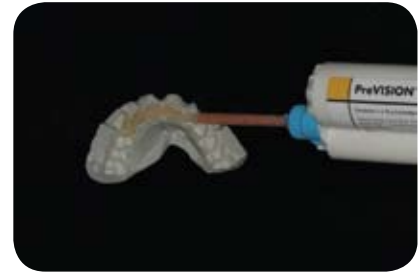


FIGURE 6B. The matrix is filled with autopolymerizing resin and placed over the teeth.

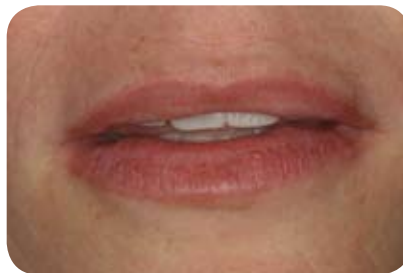

FIGURE 6C. Secondary mock-up in place evaluating the diagnostic wax-up design at rest position.

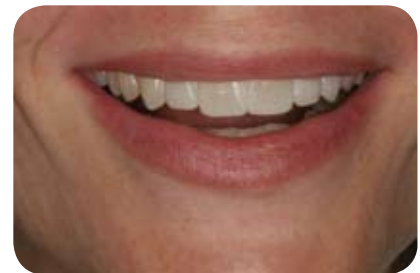

FIGURE 6D. Secondary mock-up at smile. Changes may be made according to clinical feedback.

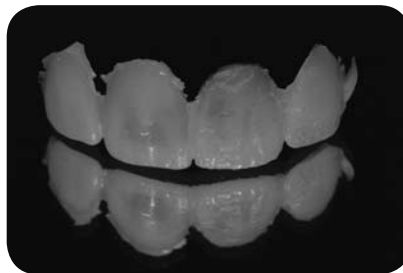


FIGURE 6E. The mock-up is removed upon completion.

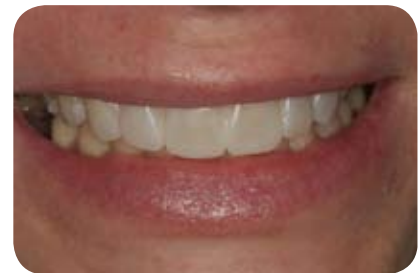

FIGURE 6F. A corrected mock-up is made based on patient's feedback.

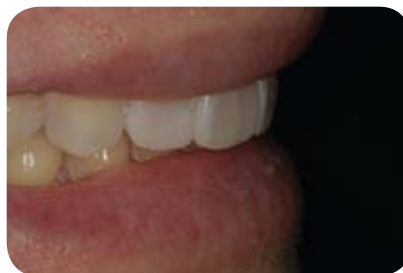

FIGURE 6G. The incisal edge position is evaluated in relation to the lip both esthetically and phonetically.

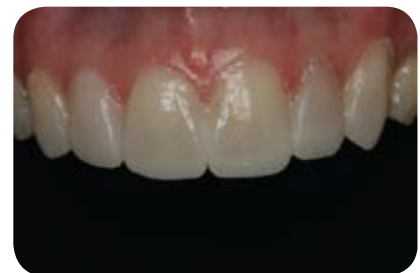

FIGURE 6H. Excess resin has to be removed from the gingival areas if the mock-up is to be used long term.

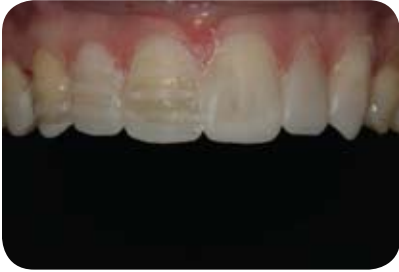

FIGURE 6I. Teeth preparation is done using depth cutting burs on the mock-up which acts as a full contour preparation guide and not on the original, worn tooth contour.

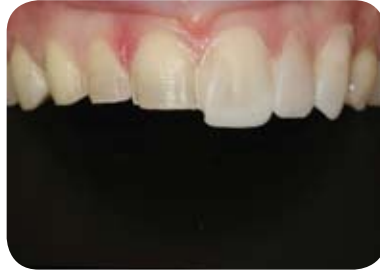

FIGURE 6J. Considerable reduction is done on the mock-up, which results in minimal tooth reduction and preservation of enamel while obtaining optimal preparation depth.

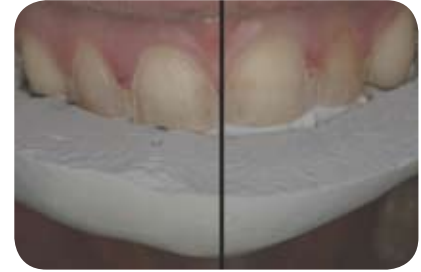

FIGURE 6K. The preparation is verified using a silicone matrix made from the final diagnostic wax-up. Symmetrical trimming of the matrix and consistent viewing angle are essential for accurate evaluation. Notice correct trimming of the matrix with proper viewing angle on the patient's left side compared to incorrect trimming and improper viewing angle on the contra lateral side.

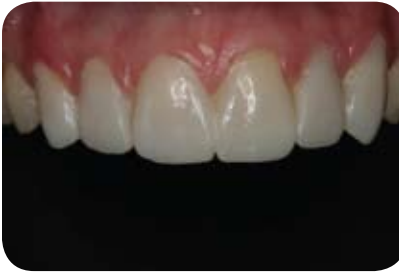

FIGURE 6L. A provisional restoration made using the same silicone template is inserted.

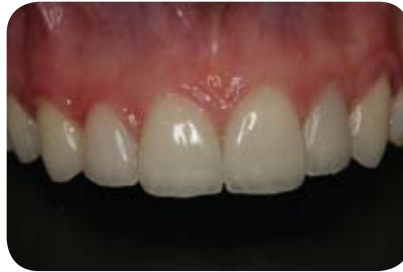

FIGURE 6M. The definitive porcelain veneers follow the diagnostic wax-up made using information obtained clinically with the preliminary and secondary mock-ups.

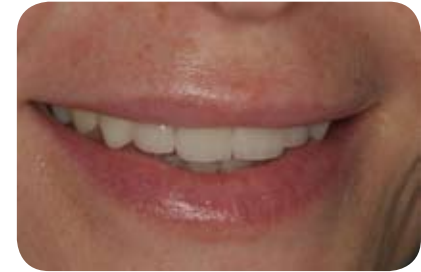

FIGURE 6N. Patient's smile is adapting to the new incisal edge position.

REMOVABLE MOCK-UP PROVISIONAL RESTORATION

If the mock-up is designed to be removed intact, it can be used as a removable overlay prosthesis for the patient to wear over the teeth. This will allow the discerning patient to evaluate the design among friends and family members who may influence the patient's decision. This mock-up provisional is used until final approval of the teeth arrangement is obtained.³

FIXED MOCK-UP PROVISIONAL RESTORATION

Another approach is to use the mock-up as a preliminary fixed provisional restoration. The unaltered teeth are etched and a silicone matrix made from the diagnostic wax-up is used to bond the mock-up to the teeth.^{13,15,16} This preliminary provisional restoration is designed to test the mock-up long term for esthetics and function. This will also allow prelimi-

nary evaluation of the design in a social environment outside the clinical setting.¹⁶

If the mock-up followed a purely additive wax-up (without any tooth reduction) and only spot etching was used to bond it, it can be easily flicked off and the teeth can be polished. This is not the case when the mock-up is based on a subtractive wax-up (tooth reduction needed for wax-up) or when the entire surface of the teeth was etched. It is important to note that in this approach the patient needs to be committed to treatment and proper consent is essential.

Discussion

It is well accepted today that the concepts of modern esthetic dentistry are founded in complete denture prosthodontics. Designing an esthetic smile in both edentulous and dentate patients requires the establishment of teeth positions for proper esthetics and function. According

to prosthodontic principles, by establishing the incisal edge position and midline and following anatomical landmarks such as the retromolar pads to communicate the desired occlusal plane, the entire dentition can be designed on mounted casts in proper esthetic arrangement.^{24,25}

If these principles are to be applied to fixed prosthodontics, an intraoral preliminary diagnostic mock-up of a single central incisor will be adequate to communicate with the technician the incisal edge position and midline and will function like the complete denture wax-rim. Using this information, the technician will be able to predictably wax the entire dentition.

The secondary mock-up will simulate the anterior teeth wax trial placement of complete dentures and once it is approved the work can be continued with a higher level of confidence.

In the event that tooth structure interferes with the diagnostic mock-

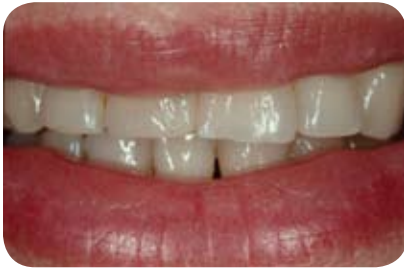

FIGURE 7A. Patient presented with inadequate configuration of incisal edges compared to the lip line and smile.

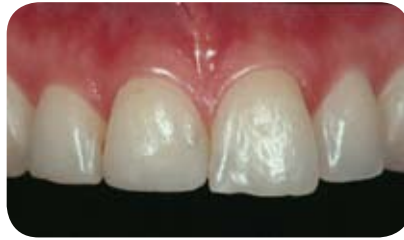

FIGURE 7B. Retracted view demonstrating improper tooth form.

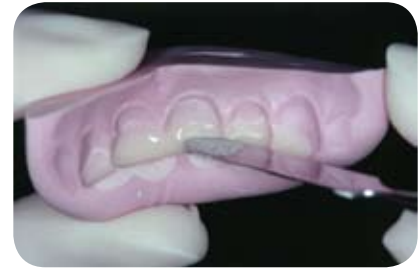

FIGURE 7C. A silicone matrix made from the diagnostic wax-up is filled with autopolymerizing resin and placed on the teeth.

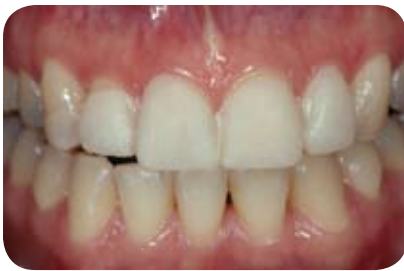

FIGURE 7D. A mock-up is formed upon polymerization of the resin.

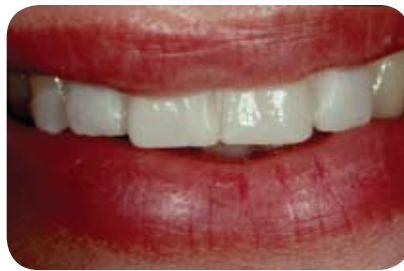

FIGURE 7E. The mock-up tests the design of the wax-up in relation to the lip line and smile. Utilizing patient's feedback from the mock-up, an additional increase in incisal edge is prescribed.

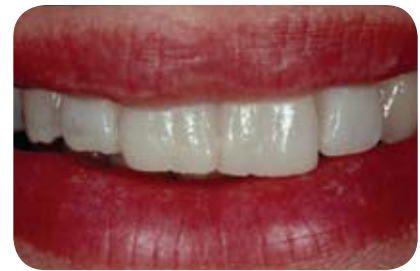

FIGURE 7F. The wax-up was modified and another mock-up is tried in. The mock-up will program the lip line and prepare the soft tissues for the definitive restoration.

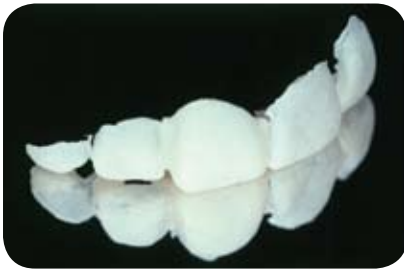

FIGURE 7G. Upon completion, the mock-up is removed.

up, minor tooth modifications may be needed. Care should be taken to obtain a complete patient consent as this is an irreversible diagnostic procedure.

These diagnostic techniques in conjunction with the mock-up provisional restoration concept are especially useful in a treatment plan that involves porcelain veneers. They are designed to address the precision needed in tooth preparation for these restorations and the difficulty in creating and maintaining long-term provisional restorations for porcelain veneers.

Since provisional veneers are typically retained using mechanical reten-

tion or spot bonding techniques, they have limited retention and durability. Given that they cannot be predictably maintained long term, it is unfeasible to evaluate the new design in function over the desired length of time. While some patients need time to accept the new appearance psychologically, in others the phonetics may need to be evaluated for a longer period. Over time, the new form may alter the patient's smile pattern and "de-program" the smile. This change may be unpredictable in magnitude and may require treatment modifications. The new occlusal scheme may need to be monitored in cases that modify the incisal guidance and the envelope of function. The techniques proposed in this article allow this to be done predictably until complete approval of the patient is obtained.

It is important to note that while a removable mock-up provisional is used according to the patient's discretion and may be in function for an unknown period or not at all, the fixed mock-up ensures patient compliance. It is more durable and

may allow a longer trial period and therefore provide a reliable provisionalization.

Porcelain veneers are conservative restorations requiring minimal tooth preparation. However, without accurate guidance related to the definitive restoration contours, the teeth could be under- or overprepared resulting in a compromised result. In order to allow optimal tooth preparation the approved mock-up is used as a preparation guide. The teeth are prepared through the resin mock-up that represents the definitive tooth contours and allows a predictable and uniform reduction.

The various techniques described hereby can be used as stand-alone procedures to obtain a clinically valid diagnostic wax-up. However, when needed, they can be used in conjunction with each other to allow a more predictable result in difficult and demanding cases.

Conclusion

The diagnostic mock-up procedure is a reasonably quick and straightforward pro-

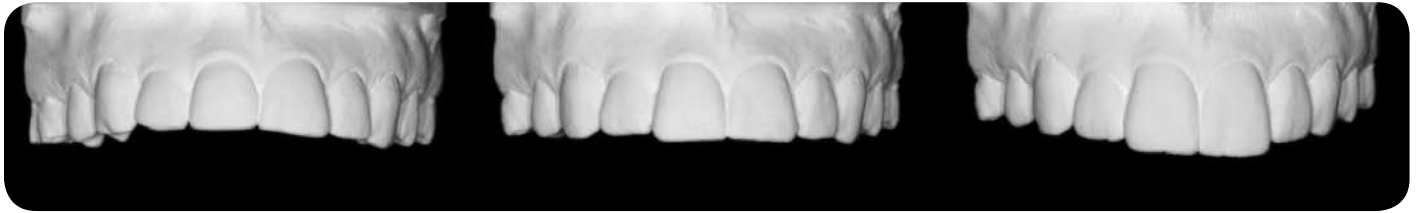


FIGURE 7H. Progression of diagnostic casts, from preoperative casts to initial wax-up and final wax-up demonstrating a total increase in incisal edge of 3 mm.

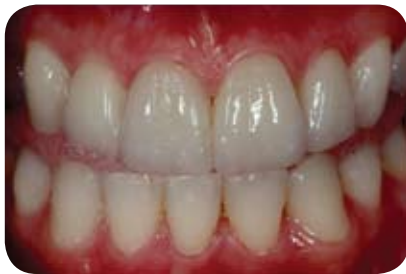

FIGURE 7I. Bonded porcelain restorations reproduce the diagnostic wax-up.

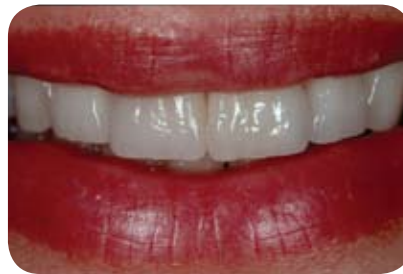

FIGURE 7J. Incisal edges are in harmony with the lower lip ensuring a predictable esthetic result. (Figures 7a-j are reprinted with permission from Magne P, Belser U, *Bonded porcelain restorations in the anterior dentition a biomimetic approach*, first ed. Carol Stream, Ill., Quintessence Publishing Co., pages 221-3, 2002.)

cedure that provides instant clinical feedback prior to the beginning of treatment.

The advantages of this technique are that the desired changes can be visualized clinically, tested with the patient's rest position and smile, as well as evaluated phonetically. In addition, the patient is actively involved in the diagnostic process providing feedback and sharing the responsibility for the final result. The patient will be more likely to accept a result that he or she visualized and co-diagnosed.

Obtaining clinical information to guide the diagnostic wax-up is an important concept. This method will enhance the predictability of the treatment, minimize loss of chairtime, and help to obtain patient acceptance from the beginning of treatment. ■■■■

REFERENCES

- Chiche GJ, Pinault A, *Esthetics of anterior fixed prosthodontics*. Chicago, Quintessence Publishing Co., 1994.
- Preston JD, A systematic approach to the control of esthetic form. *J Prosthet Dent* 35(4):393-402, 1976.
- Magne P, Belser U, *Bonded porcelain restorations in the anterior dentition a biomimetic approach*, first ed. Carol Stream, Ill., Quintessence Publishing Co., 2002.
- Rufenacht CR, *Fundamentals of esthetics*. Chicago: Quintessence Publishing Co., 1990.
- Marzola R, Derbabian K, The science of communicating the art of esthetic dentistry. Part I: Patient-dentist-patient communication. *J Esthet Dent* 12(3):131-8, 2000.
- The glossary of prosthodontic terms. *J Prosthet Dent* 94(1):10-92, 2005.
- Carlyle LW III, Richardson JT, The diagnostic wax-up: an aid in treatment planning. *Tex Dent J* 102(2):10-2, 1985.
- Yuodelis RA, Faucher R, Provisional restorations: An integrated approach to periodontics and restorative dentistry. *Dent Clin North Am* 24(2):285-303, 1980.
- Phillips K, Morgan R, The acrylic occlusal plane guide: A tool for esthetic occlusal reconstruction. *Compend Contin Educ Dent* 22(4):302-4, 306, 2001.
- Magne P, Magne M, Belser U, The diagnostic template: a key element to the comprehensive esthetic treatment concept. *Int J Periodontics Restorative Dent* 16(6):560-9, 1996.
- Kahng LS, Patient-dentist-technician communication within the dental team: Using a colored treatment plan wax-up. *J Esthet Restor Dent* 18(4):185-93; discussion 194-5, 2006.
- Magne P, Magne M, Belser U, Natural and restorative oral esthetics. Part I: Rationale and basic strategies for successful esthetic rehabilitations. *J Esthet Dent* 5(4):161-73, 1993.
- Magne P, Belser UC, Novel porcelain laminate preparation approach driven by a diagnostic mock-up. *J Esthet Restor Dent* 16(1):7-16; discussion 17-8, 2004.
- Doan PD, Goldstein GR, The use of a diagnostic matrix in the management of the severely worn dentition. *J Prosthodont* 16(4):277-81, 2007.
- Gurel G, Bichacho N, Permanent diagnostic provisional restorations for predictable results when redesigning the smile. *Pract Proced Aesthet Dent* 18(5):281-6, 2006.
- Gurel G, Porcelain laminate veneers: Minimal tooth preparation by design. *Dent Clin North Am* 51(2):419-31, ix, 2007.
- Romeo G, Bresciano M, Diagnostic and technical approach to esthetic rehabilitations. *J Esthet Restor Dent* 15(4):204-16, 2003.
- Simon H, Raigrodski AJ, Gingiva-colored ceramics for enhanced esthetics. *Quintessence Dent Technol* 25:155-72, 2002.
- Magne P, Magne M, Use of additive wax-up and direct intraoral mock-up for enamel preservation with porcelain laminate veneers. *Eur J Esthet Dent* 1(1):10-9, 2006.
- Dalvit DL, Parker MH, Cameron SM, Quick chairside diagnostic wax-up. *J Prosthet Dent* 87(5):581-2, 2002.
- Heinlein WD, Anterior teeth: esthetics and function. *J Prosthet Dent* 44(4):389-93, 1980.
- Cho GC, Donovan TE, Chee WW, Clinical experiences with bonded porcelain laminate veneers. *J Calif Dent Assoc* 26(2):121-7, 1998.
- Donovan TE, Cho GC, Diagnostic provisional restorations in restorative dentistry: The blueprint for success. *J Can Dent Assoc* 65(5):272-5, 1999.
- Zarb G, Bolender C, Carlsson G, (eds), *Boucher's prosthodontic treatment for edentulous patients*, 11th edition. St Louis: Mosby, 1997.
- Spear FM, Kocich VG, Mathews DP, Interdisciplinary management of anterior dental esthetics. *J Am Dent Assoc* 137(2):160-9, 2006.

TO REQUEST A PRINTED COPY OF THIS ARTICLE, PLEASE CONTACT
Harel Simon, DMD, 9735 Wilshire Blvd., Suite 200, Beverly Hills, Calif., 90212.