

# Child Abuse: Dentists' Recognition and Involvement

Duane E. Spencer, DDS



Duane E. Spencer, DDS, will present "Forensic Dentistry: A California Perspective" with James Wood, DDS, at CDA's Spring Scientific Session in Anaheim, Calif. The presentation will be held from 2 to 4:30 p.m. Thursday, April 15 in Rooms A/B at the Anaheim Convention Center.

## ABSTRACT

Children in our society are too often maltreated by adults in their lives. These adults may be their parents, caretakers, youth leaders, coaches or perhaps even a health care provider. Children become missing daily in the United States, perhaps running away or being abducted. Occasionally, abductions lead to tragic conclusions. This paper will cover the dental staff's involvement with a physically abused child including documenting suspected injuries, the dentist's responsibility in maintaining good records in case a young patient should go missing, and the role of the forensic dentist with patterned injuries of abusive origin.

## PURPOSE OF PAPER

The purpose of the paper is to again remind dentists and their staffs as to the importance of recognizing possible child abuse with their young patients. Reasons for and methods of documenting physical injuries such as bruising are important for the dentist to understand. The paper also relates the role of the dentist in the forensic field with abusive patterned injuries, reasons for a dentist to refer a young patient to a pediatric dentist rather than subjecting the child to uncomfortable treatment, and the importance of the dentist having good dental records on file for the potential forensic identification of a child.

Child abuse is common in American society. Maltreatment of infants and children has been traced far back in history and, tragically, it is still too prevalent in our "modern" world. Good efforts have been made in the U.S. in recent decades in the areas of child abuse recognition and prevention (**Figure 1**). Many dedicated people today work diligently and tirelessly to educate not only mandated reporters of child abuse but the general public as well. This article will discuss some areas of dental involvement in recognizing child abuse, which should be of interest to those dental staff members who provide dental services to children and teens.

## A Serious Concern

In 2001, three million referrals were made in the U.S. to Child Protective Service (CPS) agencies. Of these, approximately 903,000 children were listed as victims of maltreatment. Nineteen percent were physically abused. This was a victimization rate of 12.4 per 1,000 children in the population. This rate remained fairly constant over the previous five years. About 84 percent of these children were abused by a parent or parents.



**Author** / Duane E. Spencer, DDS, is a pediatric dentist in Walnut Creek, Calif., and a forensic dental consultant to law enforcement agencies and the California Department of Justice.




Figure 1. CDA Journal, 1976.

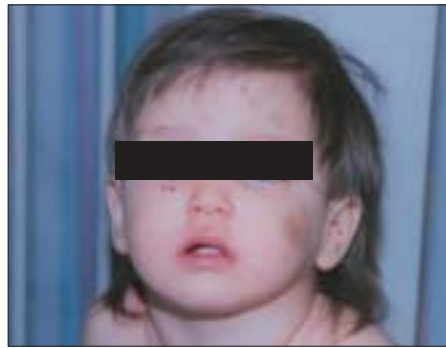

Figure 2. Multiple bruises, abrasions on abused child's face.

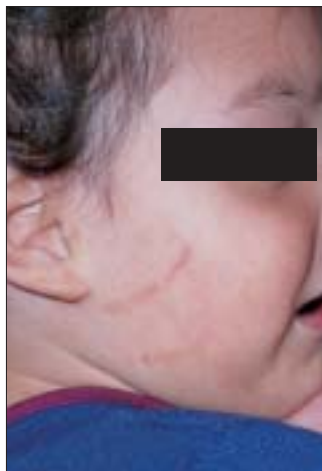

Figure 3. Fingernail marks on child's cheek.

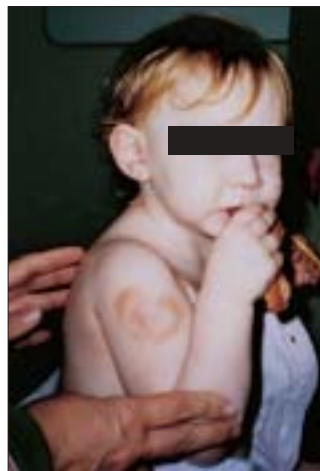

Figure 4. Human bite mark on child's arm.

Approximately 1,300 children died as a result of abuse or neglect in 2001, which is a rate of 1.81 per 100,000 children. Many researchers believe that this number is underreported.<sup>1</sup> Children's Hospital in Oakland, Calif., sees about 1,000 abused children each year. Of these, approximately one-half have been physically abused.<sup>2</sup> One must understand for every suspected abuse referral, there may be scores of unrecognized and unseen cases of abuse and neglect in the area. Child abuse and neglect continue to be a significant concern in America.

### Dental Staff's Involvement

How common is it for a pediatric dental patient (child or teen) to be the victim of abuse or neglect? Should the staff member be recognizing these abused patients? One must remember that child abuse is much more than the physical abuse that we may recognize with our dental patients. (Emotional abuse, verbal abuse, sexual abuse, abuse of children over the Internet.) When the entire scope of abuse is taken into account, it is quite possible that the busy pediatric dental practice will encounter several patients per

week who may have been victims of abuse. The child's abuse certainly may affect his or her behavior in the dental office. This may range from being quiet and withdrawn to acting out and being uncooperative. The dentist is not expected to recognize the child's behavior as being a manifestation of a specific type of abuse nor is the dentist expected to recognize the child victim of sexual or Internet abuse.

The dental staff should be aware that with physical child abuse it has been reported that approximately two-thirds of visible injuries to a child will be located in the region of the head and neck.<sup>3</sup> The dentist must be cognizant of injuries in questionable locations, multiple injuries (Figure 2), injuries that appear to be in different stages of healing and injuries which are not age-appropriate, i.e. facial injuries on the pre-ambulatory child. Be observant for possible patterned injuries such as finger (Figure 3), ligature, burn, or bite marks (Figure 4), or marks possibly caused by a belt, strap or cord. Multiple bruising, loss of hair (hair pulling) or injuries to the ears should raise suspicion. As we were all taught, treating a dental patient involves more than looking inside the mouth. Observe the child's actions, behavior, physical movements and verbal communication and assess if they are appropriately age-related to the patient. Perform a quick visual assessment of the child's face, head, neck, hands and any other *exposed* area of the body. It is not the dentist's responsibility to either lift or remove the patient's clothing to search for physical injuries.

If the dentist suspects physical abuse with a young patient, then he or she should have another dental staff member also witness the injuries and assist in their documentation. A written descrip-

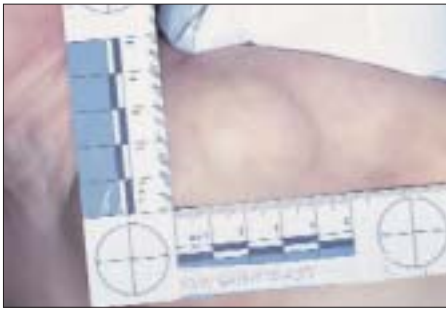


Figure 5. Bite mark on shoulder of seven-week-old child abuse-homicide victim.

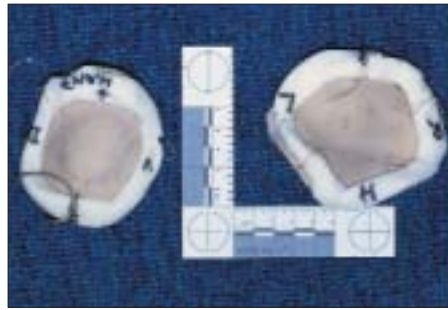


Figure 6. Resected tissue containing bite marks. Shoulder bite mark on right.

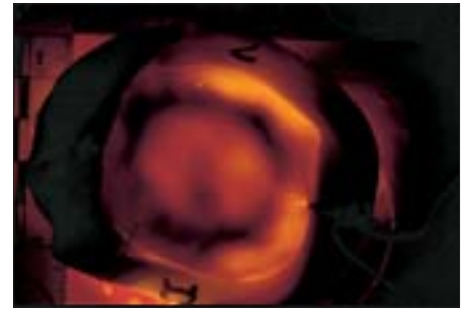


Figure 7. Transillumination of resected bite mark on shoulder.

tion with diagrams can document the locations, shapes, sizes, etc., of injuries. Intra-oral injuries might necessitate the need for dental X-rays. Section 11171(a) of the California Penal Code allows the dentist, or his or her agent, to obtain X-rays of a child without the consent of the parent when the dentist is diagnosing the case as one of possible child abuse and determining the extent of such child abuse.<sup>4</sup> If there are injuries present, such as on the face, on the child that lead the dentist to suspect child abuse, it is recommended that photographs be taken of the injuries. Most dentists have available a clinical camera, either 35mm or digital. A photograph should be taken of the entire face as well as close ups of the individual injuries. The close-up photographs should include some type of scale (ruler) placed near the injury but not covering any part of the injury. X-rays, photographs, etc., should be documented. When reporting the suspected abuse, it is recommended the dentist advise CPS, sheriff, etc., what documentation of injuries the dentist obtained. X-rays or photographs taken in the dental office may be the only evidence available to authorities. It cannot be assured that subsequent photographs will be taken, and if they are, what quality they will be and of what stage of

healing the injuries may have reached.

Some dentists may be concerned about becoming involved in a case of suspected child abuse with one of their patients. It must be emphasized the law mandates that the dentist, as well as an RDH or RDA, report the suspected abuse. The dental staff should be concerned more about the health and well being of the child than of any personal concerns. The dentist need only document the injuries and report the suspected abuse. He or she is not required to investigate the possible abuse nor to try to be a detective. The proper authorities will handle the investigation. Certainly there could be potential for the dentist to be required to testify in future court proceedings (although the author never has had to testify as a pediatric dentist in 38 years of treating children). The dentist must not let a concern of getting involved or testifying prevent him or her from making a report.

### Forensic Odontologist and Child Abuse

Those active in the field of forensic odontology may be called upon to evaluate patterned injuries in child abuse. Usually these injuries will be bite marks inflicted upon the child. The odontologist may have the opportunity to exam-

ine the child, living or deceased. More often the odontologist will be supplied with photographs and asked to give an opinion as to the presence of bite marks, the quality of the marks, and whether an adult or child may have inflicted the marks. Too often the supplied photos are of poor quality, taken at too great a distance from the injury, out of focus or without the presence of a scale (ruler). An experienced odontologist will take quality photographs when he or she has the opportunity to see the child whether in the hospital ER, morgue, etc.

Bite marks on a child's body, unless observed soon after the bite was inflicted, often present as a diffuse bruising of ovoid or elliptical shape with little or no definition of individual teeth.<sup>5</sup> Often, the odontologist can only determine if it is a human bite mark and perhaps if it was inflicted by an adult or young child. It has been the author's forensic experience that just this amount of information can lead the abuser to admit their involvement with the child or can rule out certain individuals who may have had access to the child. Proper photography of patterned injuries (bite marks) in the physician's or dentist's office, the hospital emergency room, or at the police station can greatly aid in the subsequent analysis and potential comparison of the mark(s).



In cases of child abuse-homicide, the forensic odontologist will take photographs of the suspected patterned injuries. If there is any third dimension to an injury, the odontologist will take an impression with a dental impression material in order to have a model of the injury to use for potential comparison to dental models of any suspected biters. It also is recommended that the odontologist resect the tissue involving the bite mark and properly preserve it for later transillumination (**Figures 5 and 6**). Transillumination may yield more detail of the bite pattern and arch sizes (**Figure 7**). This often can tell the odontologist an adult or teenager inflicted the bite on the child, not the young sibling the suspect may try to blame for the abuse.

Good forensic evidence collection with patterned injuries in child abuse can be of great assistance to the law enforcement investigator and the prosecutor. In some cases, the defendant has pleaded guilty just prior to trial or there was a stipulation as to the bite mark evidence rather than having the odontologist testify.

### Referrals: Recognizing One's Limitations

The management and treatment of the dental needs of a child can be extremely challenging. Not all dentists have the personality, patience, experience or training to work with young patients. Most such dentists realize this and refer them to pediatric dentists. Some dentists restrict their pediatric treatment to older, more cooperative children. This is as it should be. Children deserve healthy and happy experiences when receiving dental treatment. Too many adults comment on how their own poor childhood dental experiences led to their current

apprehensions with dental treatment. Over-treatment of children may not only be wrong but might be considered by some an assault on the young patient. Restoring teeth with no caries or which are soon to exfoliate with the goal of increasing office revenue could be considered abusive. The dental health professional should be above rendering such "treatment" and fortunately most are. If the dentist does not have the patience to treat children he or

**Good forensic evidence collection with patterned injuries in child abuse can be of great assistance to the law enforcement investigator and the prosecutor.**

she, should not do so. It is difficult to review cases such as one where a young child received a stainless steel crown but was taken back to the parent in the reception room perspiring, with a flushed face, tears in the eyes and marks on their face and the neck. The dentist should recognize before beginning treatment that the young child might need some type of sedation or general anesthesia. In such cases, referral might be the correct option. Children do not deserve to grow up with bad memories of their pediatric dental experiences.

### The Dentist's Role in Aiding in the Identifications of Missing Children

The media keeps us well informed of cases of children in our communities who go missing or who are abducted. Most parents and grandparents keep close, protective watch on their children in today's society. We all remember too well the tragic cases of young girls such as Polly Klaas, Christina Williams, Xiana Fairchild, and Danielle van Dam. Dental identifications were used with each of these homicide victims. Lately, advertisements in some dental journals tout bite registration wafers to record the bites of young patients in case they should ever go missing. Experience in identifying the burned, decomposed or skeletal remains of children, has been that bite records are not of value. Additionally, a dentist advertising the use of such bite records to attract new patients to his or her practice may border on the unethical. Good written dental records and dental radiographs are vital to an identification effort. These records remain the legal standard for identification by dental means. When they do not exist, for example if a child is too young for X-rays, then DNA analysis can be used successfully for identification. It must be noted however, that DNA analysis is very time consuming and costly, while dental identification can produce a positive identification in a very short time, at a low cost to the investigating agency.

### The Dentist and Child Abuse Prevention

Dentists who treat children or are interested in aiding in the prevention of child abuse and neglect certainly

have several options. The staff can be trained to recognize and report suspected abuse. Attending a presentation on child abuse recognition may be helpful. Another suggestion is to provide literature, posters, handouts, etc. in the reception room to assist in educating parents. Information also is available for spousal and elder abuse. The local child abuse prevention council has a number of resources and training courses for those who want to become a volunteer community educator. Those volunteers speak to local groups such as childcare providers, and pre-school teachers.

### Summary

This article has discussed the prevalence of child abuse; the importance of the dentist recognizing physical abuse and methods of documenting suspected abusive injuries. The forensic odontologist may be called upon to document and analyze patterned abusive injuries. It is important that dentists realize their comfort level and competence in treating children and refer the young patient to a specialist when indicated. The dental office should maintain complete and legible records on their pediatric patients for potential forensic utilization. **CDA**

**To request a printed copy of this article, please contact / Duane E. Spencer, DDS, 1855 San Miguel Drive, Suite 9, Walnut Creek, Calif., 94596-5214.**

- References** / 1. Child Maltreatment 2001 report. The National Child Abuse and Neglect Data System (NCANDS) U.S. Dept. of Human Services.  
2. Crawford James, MD, Children's Hospital Oakland Calif.; Personal communication.  
3. Cameron JM, Johnson HR, Camps FE, The Battered child syndrome. *Med Sci Law* 6:2-21, 1966.  
4. California Department of Justice, *Child Abuse Prevention Handbook* pg. 93, 1993.  
5. Spencer DE, Bite marks in Child Abuse. *Manual of Forensic Odontology* third ed. Printing Specialists, Montpelier, Vt., pg. 178, 1995.