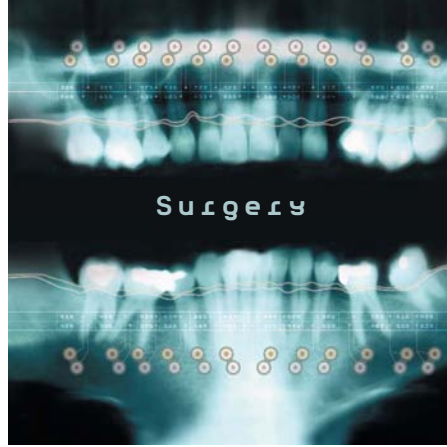

Periodontal Plastic Surgery as an Adjunctive Therapeutic Modality for Esthetic Restorative Dentistry

Kirk L. Pasquinelli, DDS

ABSTRACT

This paper summarizes the field of periodontal plastic surgery and its applicability as an adjunctive treatment modality in the delivery of esthetic restorative dentistry.

Esthetic dental problems are often multifactorial in nature and may not be satisfactorily resolved by restorative treatment alone. An interdisciplinary approach to these situations offers the greatest potential for an outstanding treatment result. The better versed the restorative dentist is in adjunctive therapeutic modalities available from the dental specialties, the greater will be their ability to deliver a superior result. Periodontal plastic surgery may be utilized in the interdisciplinary solution to many esthetic clinical challenges.¹

Periodontal plastic surgery deals with the cosmetic reconstruction, reshaping, or removal of the dentoalveolar tissues.² The procedures common to the field include: root coverage, ridge augmentation, ridge preservation, pre-prosthetic ridge alteration, and esthetic crown lengthening. The ultimate goals of periodontal plastic surgery procedures are to provide the patient with their desired esthetic outcome while maintaining the health of the teeth and periodontium.

Through a series of case reports, the objective of this paper is to help restorative dentists further their knowledge of periodontal plastic surgery as it pertains to the planning and delivery of sound biologic dental therapy that optimizes esthetics.

Root Coverage

Root exposure resulting from apical recession of the marginal tissues may create esthetic concerns for a patient. As the length of the teeth increase, there is loss of gingival symmetry as well as increased sensitivity, susceptibility to caries, and concern over the retention of the teeth (**Figure 1a**). Restorative coverage of the root can reduce sensitivity or treat caries but cannot decrease the length of the clinical crown, restore the lost periodontal support, or prevent future recession by strengthening the periodontium.

The clinical goals of root coverage procedures are to replace the tissues lost due to recession, effect an attachment of the restored tissues to the root of the tooth, reduce thermal and touch sensitivity, prevent future recession, and improve the esthetics of the area.

In 1985, Raetzke and then Langer and Langer, described the use of connective tissue grafts for root coverage.^{3,4} In this technique, palatal connective tissue is transplanted into an envelope-like pouch prepared at the recipient site



Author / Kirk L. Pasquinelli, DDS, is in full-time private practice limited to periodontics and dental implants in downtown San Francisco. He continues to lecture and publish internationally.

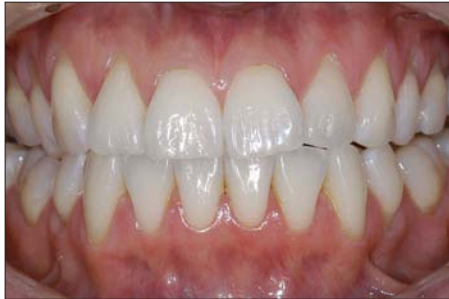

Figure 1a. Patient presents with generalized slight to moderate recession, gingival asymmetry, thin alveolar housing, and lack of attached gingival.

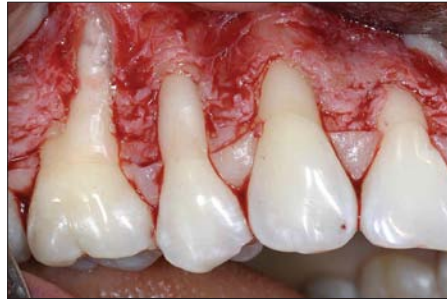

Figure 1b. Split-thickness recipient site preparation with primary flap elevated to create pouch for graft. The roots have been instrumented.

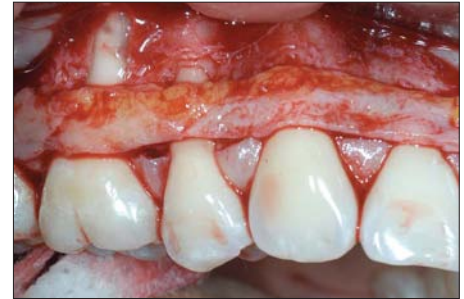

Figure 1c. Prior to closure of the primary flap a connective tissue graft is placed over the roots.

(Figures 1b, c). This pouch provides a dual blood supply to the graft from the superior and inferior connective tissue surfaces in contact with the graft. The retained superior flap also maintains the esthetics of the original tissues and acts as a source for the epithelial cells that migrate over the exposed portion of the connective tissue graft (Figures 1d, e). These grafts are very successful in covering the root and blending with the adjacent tissues for a highly esthetic result (Figures 2a, b).

Improved methods of surgical magnification, illumination, and instrumentation have increased the precision of these procedures. As a result, there is decreased trauma to the tissues allowing for improved outcomes and reduced patient discomfort.⁵

Ideally, these grafts would attach to the root versus forming a pocket created by the new tissue covering the facial of the root. Several authors have shown clinical measurements that are consistent with attachment of the grafted tissue to the previously exposed root surface, and histological case reports have shown new bone and connective tissue attachment on these root surfaces.⁶⁻⁸

Ridge Augmentation and Preservation

Removal of a tooth or implant results in collapse of the alveolus and causes a shift of what had been the free

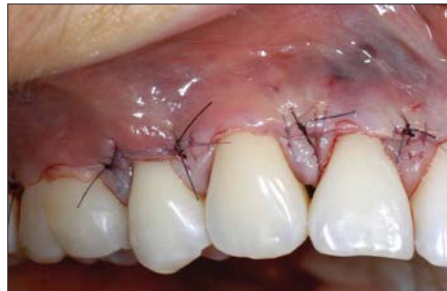

Figure 1d. Primary flap sutured closed over the connective tissue graft with 7-0 sutures.

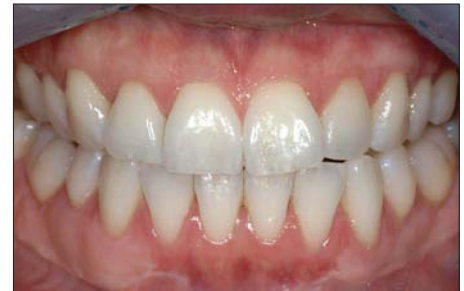

Figure 1e. Seven months' postop. The maxillary recession has been corrected, gingival symmetry has been restored, the gingiva is thicker, and there is an increase in the amount of attached gingiva. The mandibular teeth were simultaneously treated with free gingival grafts.

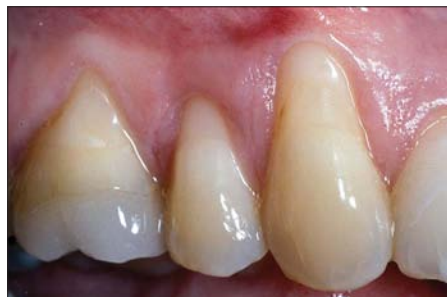

Figure 2a. Patient presents with moderately advanced recession and a lack of attached gingival.

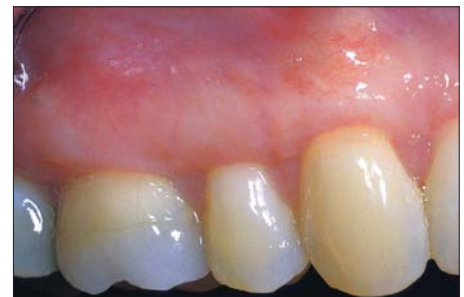

Figure 2b. Two months following a connective tissue graft. There is complete root coverage as well as an increase in the thickness and vertical dimension of the attached gingiva. The grafted tissues blend well with the native tissue.

gingival margin in an apical and lingual direction.^{9,10}

Esthetic restoration of missing teeth with pontics or implants often will require reconstruction of this lost tissue prior to placement of the prosthesis. Ridge augmentation techniques have

been developed that allow predictable replacement of alveolar tissue lost after the removal of teeth. Ridge preservation techniques, performed simultaneously with tooth or implant removal, can prevent the natural collapse of the ridge and will limit the loss of bone and soft tissue.

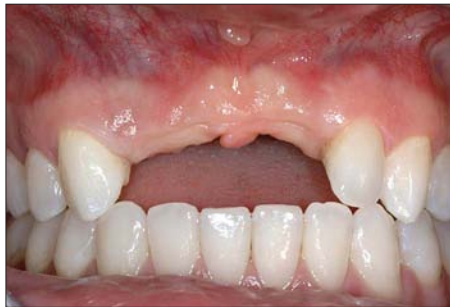

Figure 3a. Patient presents with moderate Class III ridge defect and a failing tooth No. 10 that will need to be removed. Implants are planned for the No. 7 and 10 sites.

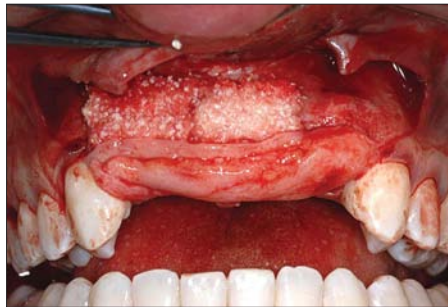


Figure 3b. Tooth No. 10 has been removed and implants placed in the No. 7 and 10 positions. The ridge has been augmented with a combination of bone grafting and laminated connective tissue grafts.

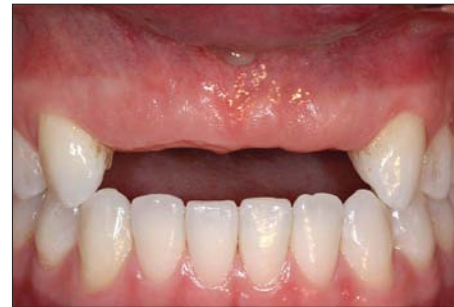

Figure 3c. Six-month postop. At this time, the ridge was assessed as adequate and the patient was referred to the restorative dentist to begin therapy.

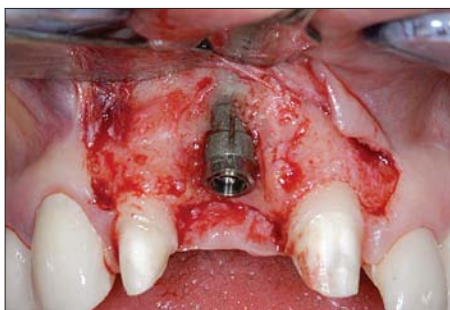


Figure 4a. Failing implant at the No. 8 position. The implant needs to be removed and the ridge reconstructed to prevent collapse.

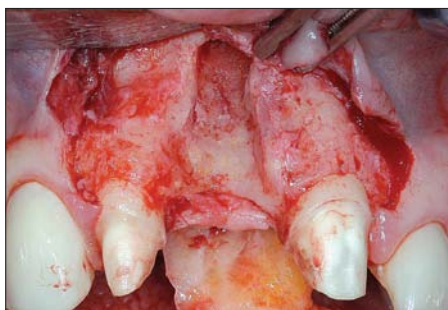

Figure 4b. After removal of the implant, there is substantial loss of the buccal plate. The mesial, distal, and palatal walls of the extraction socket are relatively intact.

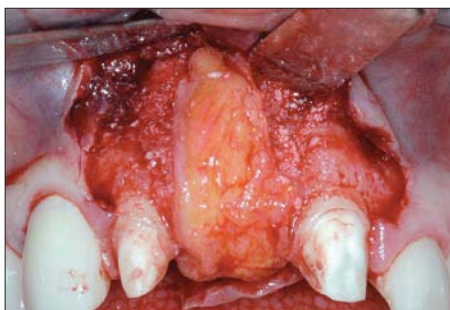

Figure 4c. A slowly resorbable bone graft material has been placed in the socket and covered by a connective tissue graft.

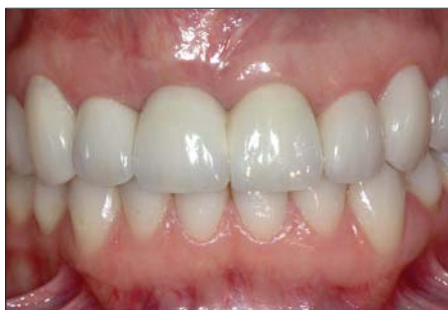

Figure 4d. A fixed partial denture with an ovate pontic at the No. 8 site was utilized to replace the failed implant (Restorative dentistry by Dr. Belinda Gregory-Head).

of connective tissue to restore the missing tissue volume. In some cases, multiple, sequential, ridge augmentations will be required to fill the defect. The final prosthesis can be undertaken four or more months after the last surgical procedure.¹

This technique can also be used to increase the volume of soft tissue around previously placed implants, and it can be helpful in the restoration of papillae adjacent to implants and pontics.

If implants are planned, the amount of bone in the site will determine the type and sequence of any grafting procedures. If there is a deficiency of bone large enough that primary stabilization of an implant is not possible, then the necessary bone volume should be restored first. Once adequate bone volume is established, the soft tissue is assessed for esthetic harmony and augmented as necessary.

Ridge Preservation

Ridge preservation procedures are combined soft tissue and hard tissue grafts of extraction sites done in conjunction with the removal of teeth or implants (Figures 4a-d). The purpose of these procedures is to prevent resorption and collapse of the ridge, thereby reducing the need for subsequent augmentation of a deficient ridge.

Extraction should be done as atraumatically as possible in order to pre-

Ridge Augmentation

Collapsed ridges can be built up in a variety of ways: soft tissue grafts, bone grafts, guided bone regeneration, alveolar distraction osteogenesis, and combinations of these techniques (Figures 3a-c).¹¹⁻¹⁶ The anatomy of the

defect, and the restorative plan, will aid in selection between these available techniques.

If a fixed partial denture is planned, connective tissue grafts can be used to restore the missing tissue volume. Large defects may require several layers

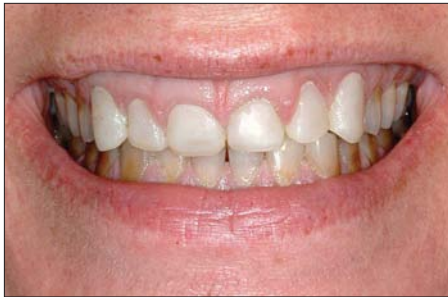

Figure 5a. Patient presents with an asymmetric free gingival margin position, excessive gingival display, failing restorations, and tetracycline staining.

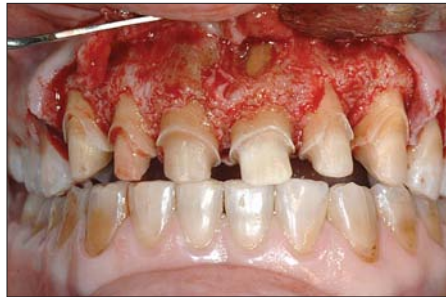

Figure 5b. Flap elevated to show the position of the osseous crest. Bone will need to be removed circumferentially around each tooth to establish adequate room for the dentogingival complex apical to the desired position of the crown margins. Note the apical loss of the buccal plate due to an endodontic lesion on tooth No. 9.

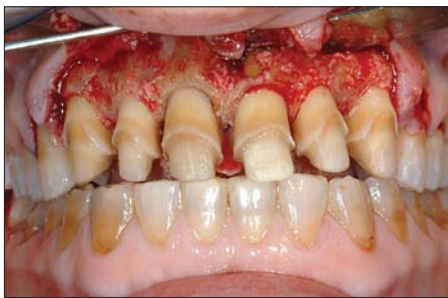

Figure 5c. Osseous surgery has been done to remove enough bone to re-establish the position of the dentogingival complex relative to the projected restorative margins. The lesion on No. 9 was treated with endodontic therapy.

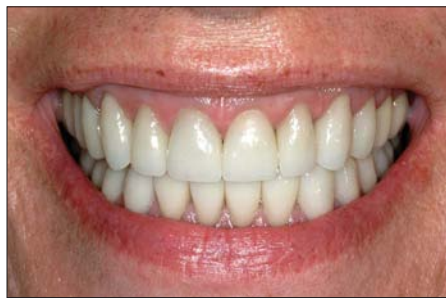

Figure 5d. Post-treatment smile exhibiting gingival symmetry, reduced gingival display, and improved dental esthetics (Restorative dentistry by Drs. Julie Djie and Dan Gustavson).

to a location on the tooth that is esthetically and structurally more favorable while maintaining the health of the tissues.

Periodontal crown lengthening can be accomplished in several ways: gingivectomy, apically positioned flaps, osseous surgery, or a combination of these techniques. The most frequently utilized method, osseous surgery, is used when it is necessary to remove bone to establish the necessary 3 mm between the alveolar crest and the desired position of the free gingival margin (Figures 5b, c). This 3 mm is the distance required for the dentogingival complex. Poor results will be produced if a gingivectomy is used as the sole method of crown lengthening in a situation that requires the removal of bone to make room for the dentogingival complex. When the bone is not removed, the soft tissues will rebound postoperatively to re-establish the dimensions of the dentogingival complex and the final free gingival margin position will be too far coronal on the tooth.

If an intracrevicular margin is planned, the restorative dentist needs to wait until maturation of the attachment and stability of the gingival crevice prior to the final restoration of the case²³ (Figure 5d). The time to stable tissue maturity varies between patients and procedures. Postoperative tissue stability can be ensured by two similar measurements of sulcus depth and free gingival margin position over time. The interval between these measurements should be at least six weeks.

Summary

This paper summarizes the field of periodontal plastic surgery and its applicability as an adjunctive treatment modality in the delivery of esthetic restorative dentistry. CDA

References / 1. Pasquinelli KL, Periodontal Plastic Surgery, *J Calif Dent Assoc* 27 (8):597-610, 1999.
2. Miller PD, Allen EP, The development of

serve as much of the supporting bone and gingival tissues as possible. An osseous graft is then placed in the socket and covered with a connective tissue graft, tissue plug, or barrier membrane.¹⁷⁻¹⁹ At the completion of the procedure, a provisional restoration is placed. Four months later, the tissues are assessed. If there is no need for further augmentation, the final prosthesis is begun.

Crown Lengthening

Patients may present with an excessive or aberrant display of gingival tissues (Figure 5a). Periodontal crown lengthening procedures can modify the supporting apparatus of the teeth

through the judicious surgical removal and reshaping of the soft tissues and/or bone. The desired result is an increase in the length of the clinical crown and a concomitant reduction of gingival exposure. This will effect an improvement in esthetics by altering the ratio of the clinical crown to the marginal tissue in favor of the teeth.

Successful crown lengthening requires an understanding of the biologic width of attachment, the dentogingival complex, and the relationship among the alveolar crest, the position of the free gingival margin, and the tip of the papilla.²⁰⁻²² The goal of crown lengthening surgery is to reposition the dentogingival complex

periodontal plastic surgery, *Periodontol* 2000 11:7-17, 1996.

3. Raetzke PB, Covering localized areas of root exposure employing the "envelope" technique. *J Periodontol* 56:397-402, 1985.

4. Langer B, Langer L, Subepithelial connective tissue graft technique for root coverage. *J Periodontol* 56:715-20, 1985.

5. Shanelec DA, Tibbetts LS, A perspective on the future of periodontal microsurgery. *Periodontol* 2000 11:58-64, 1996.

6. Wennstrom JL, Mucogingival therapy. *Ann Periodontol* 1(1):679-86, 1996.

7. Pasquinelli KL, The histology of new attachment utilizing a thick autogenous soft tissue graft in an area of deep recession: A case report. *Int J Periodont Restorat Dent* 15:248-57, 1995.

8. Cortellini P, Clauser C, Pini Prato GP, Histologic assessment of new attachment following the treatment of a human buccal recession by means of guided tissue regeneration procedure. *J Periodontol* 64:387-91, 1993.

9. Carlson GE, Thilander H, Hedegard G, Histologic changes in the upper alveolar process after extractions with or without insertion of an immediate full denture. *Acta Odontol Scand* 25:1-31, 1967.

10. Schropp L, et al, Bone Healing and Soft Tissue Contour Changes Following Single-Tooth Extraction: A Clinical and Radiographic 12-Month Prospective Study, *Int J Periodont Restorat Dent* 23:313-23, 2003.

11. Langer B, Calagna L. The subepithelial connective tissue graft. A new approach to the enhancement of anterior cosmetics. *Int J Periodont Restorat Dent* 2:22-33, 1982.

12. Seibert JS, Reconstruction of deformed partially edentulous ridges using full thickness onlay grafts, I: Technique and wound healing. *Compend Contin Educ Dent* 4:437-53, 1983.

13. Abrams L, Augmentation of the deformed residual edentulous ridge for fixed prosthesis. *Compend Contin Educ Dent* 1;3:1980.

14. Tolman D, Reconstructive procedures with endosseous implants in grafted bone: A review of the literature. *Int J Oral Maxillofac Implant* 10:275-94, 1995.

15. Mellonig JT, Nevins M, Guided bone regeneration of bone defects associated with implants: An evidence-based outcome assessment. *Int J Periodont Restorat Dent* 15:169-85, 1995.

16. Chin M, The role of distraction osteogenesis in oral and maxillofacial surgery. *J Oral Maxillofac Surg* 56:805-6, 1998.

17. Cohen ES, Ridge enhancement and socket preservation utilizing the subepithelial connective tissue graft: a case report. *Pract Periodont Aesthet Dent* 7:53-8, 1995.

18. Landsberg CJ, Bichacho N, A modified surgical/prosthetic approach for optimal single implant supported crown, Part I: The socket seal surgery. *Pract Periodont Aesthet Dent* 6:11-7, 1994.

19. O'Brien TP, Hinrichs JE, Schaffer EM, The prevention of localized ridge deformities using guided tissue regeneration. *J Periodontol* 65:17-24, 1994.

20. Gargulo AW, Wentz FM, Orban BJ, Dimensions and relations of the dentogingival junction in humans. *J Periodontol* 32:261-7, 1961.

21. Kois JC, Altering gingival levels: The restorative connection, I: Biologic variables. *J Esthet Dent* 6:3-9, 1994.

22. Tarnow DP, Magner AW, Fletcher P, The effect of the distance from the contact point to the crest of bone on the presence or absence of the

interproximal dental papilla. *J Periodontol* 63:995-1004, 1992.

23. Wilson RD, Maynard JG, Intracrevicular restorative dentistry. *Int J Periodont Restorat Dent* 1:35-49, 1981.

To request a printed copy of this article, please contact / Kirk L. Pasquinelli, DDS, San Francisco Periodontics and Dental Implants, 450 Sutter St., Suite 1314, San Francisco, CA 94108.