



Short Tooth Syndrome: Diagnosis, Etiology, and Treatment Management

Stephen J. Chu, DMD, MSD, CDT, MDT;
Susan Karabin, DDS; Saiesha Mistry, DDS

ABSTRACT

The periodontal-restorative team is uniquely positioned to provide the esthetic procedures that today's sophisticated patient population has come to expect. Not only is health and function of great desire but also esthetics is in demand. Armed with periodontal-plastic procedures and technically advanced restorative materials, the periodontal-restorative team can provide these patient needs. The challenge becomes making the correct diagnosis and selecting the appropriate treatment regimen.

Aesthetic dentistry with the associated contemporary paradigms has become endemic in modern day clinical dentistry. Today's esthetic-minded periodontal surgeon is called upon to not only recognize and diagnose esthetic deformities due to a variety of periodontal etiologies, but also employ creative surgical techniques to address these issues. Subtleties in papilla position and gingival architecture in a 3-D spatial relationship, i.e. height, fullness, and shape, become critical parameters for predictability and success especially to the restorative dentist and patient.

Frequently, short teeth are a common "chief complaint" expressed by patients dissatisfied with the appearance of their smile since the teeth are visually disproportionate in size. The diagnostic assessment of the smile is reflective of the amount of gingiva and tooth exposed during smiling.¹ The appearance of short teeth can be due to excessive gingival display (**Figure 1**) and/or a lack of incisal tooth display (**Figure 2**).

This clinical condition can be termed "Short Tooth Syndrome." The etiology associated with each specific condition must be identified separately and elucidated by the clinician since

the treatment planning and management is different for each condition.

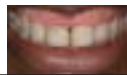
An excessive amount and display of gingiva can result in a "gummy" smile appearance with teeth having a proportion close to unity (length to width ratio equal to 100 percent) or a perfect square. Surgical periodontal treatment, specifically esthetic crown lengthening, becomes imperative in these situations in order to restore the esthetic "frame-



Authors / Stephen J. Chu, DMD, MSD, CDT,MDT, is a clinical associate professor; director of Advanced and International Programs in Aesthetic Dentistry, Division of Prosthodontic and Restorative Sciences, Department of Implant Dentistry at New York University College of Dentistry. He also has a private practice, limited to esthetic and restorative dentistry and is a board-certified dental laboratory technician: ceramics.

Susan Karabin, DDS, is a clinical associate professor and a former director for the Office of Professional Development, Division of Periodontics at Columbia University School of Dental and Oral Surgery. She has a private practice, limited to periodontics and implant dentistry, as well as a diplomate, American Board of Periodontology.

Saiesha Mistry, DDS, is a former clinical teaching associate in Advanced and International Programs in Aesthetic Dentistry, Division of Continuing Dental Education at New York University College of Dentistry. She is in private practice, limited to esthetic and restorative dentistry, Mumbai, India.



SHORT TOOTH

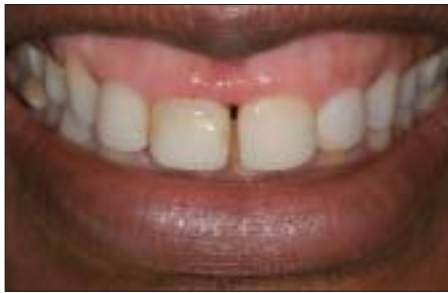

Figure 1. A "gummy" smile due to excessive gingival display leading to the visual perception of short teeth (STS). The smile is unesthetic since the teeth appear to be disproportionate relative to the surrounding gingival tissues as well as excessively square in reference to tooth shape and dimension.

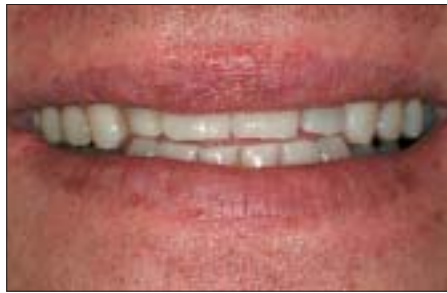

Figure 2. An unesthetic smile due to a lack of incisal edge tooth display leading to the visual perception of short teeth (STS).

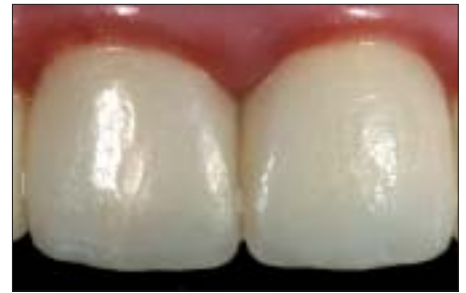

Figure 3. Classic chronic inflammatory response of the gingival tissues that is non-plaque related due to violation of the "biologic width." In an effort to gain retention on short clinical crowns, the preparations of the teeth and the margins of the restorations were extended too far apically and interproximally into the supracrestal connective tissue fibers.

work"; i.e. tooth proportion and "the golden proportion."² Injudicious tissue removal without consideration of biologic parameters can have tremendous negative consequences (Figure 3). Frequently, periodontal surgery is indicated in these case types in order to avoid invasion of the biologic width by restorative procedures.

As previously mentioned, a lack of tooth display or incisal exposure can also give the appearance of short teeth. In this situation, forced or active orthodontic extrusion or restorative treatment can be rendered. As one can see, the diagnoses for each clinical situation can be difficult, varied, and complex.

Tooth eruption involves a complex series of events and has not yet been fully elucidated. However recent investigations have added to our knowledge base on this subject. Active eruption occurs as the tooth elongates through amelogenesis, dentinogenesis and cementogenesis. Osteoclastic activity removes bone in a genetically predetermined path allowing the tooth to enter the oral cavity. A series of elegant investigations have identified the dental follicle as the tissue responsible for active eruption and not the formation of the root.³ The dental follicle eventually becomes the periodontal ligament.⁴ Active eruption is complete when the tooth reaches its

functional occlusion. Passive eruption is a process by which the epithelial attachment of the gingival tissue retracts from the enamel portion of the crown onto the root into adult position just apical to the CEJ allowing for a fibrous connective tissue attachment at the base of the sulcus (the biological width)⁵ (Figure 4). These two processes appear to be controlled by different groups of regulatory genes. Alterations in either of these processes can result in "Short Tooth Syndrome."

This article will identify common periodontal and restorative esthetic deformities responsible for "Short Tooth Syndrome" (STS), their diagnosis and etiologies commensurate with the esthetic and biologic basis of treatment, as well as treatment management.

Short Tooth Syndrome

The following list of clinical scenarios comprises the clinical conditions associated with STS:

- Altered Eruption
 - a – Active
 - b – Passive
- Excessive Incisal Attrition
 - a – Compensatory Eruption
- Delayed Eruption Maxillary Incisors
 - a – Excessive Eruption of Mandibular Incisors
- Vertical Maxillary Excess

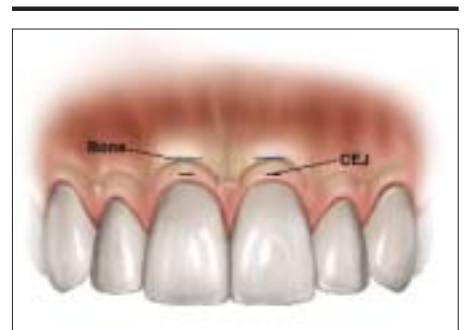
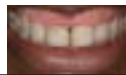

Figure 4. Diagrammatic representation of the normal physiologic position of the osseous crest, free gingival margin, and clinical crown exposure relative to the CEJ.

Altered Eruption (Active and Passive)

Aberrations of physiologic tooth eruption have periodontal and esthetic implications. Figure 4 exemplifies the normal physiologic relationship between the osseous crest, gingival tissues, and the CEJ.

In altered eruption, one finds the gingival margin located excessively incisal to the CEJ, covering a portion of the anatomic crown with soft tissue.^{6,7} Various expressions of altered eruption (active and passive) have been described and classified in Table 1. The diagnostic process includes identifying the classification of the situation to be treated. This enables the clinician to select and execute the appropriate surgical procedure to reveal the anatomic



SHORT TOOTH

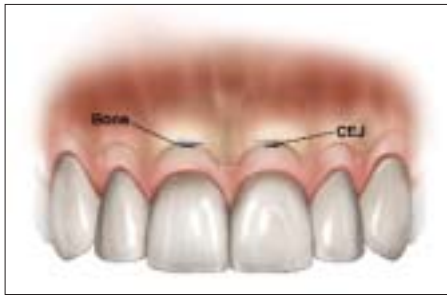

Figure 5. Diagrammatic representation of altered *active* eruption (Type IB). Note the relationship of the CEJ relative to the osseous crest which in this situation is more incisal than the physiologic norm (at the CEJ). The free gingival margin (FGM) is higher on the anatomic crown than normal.

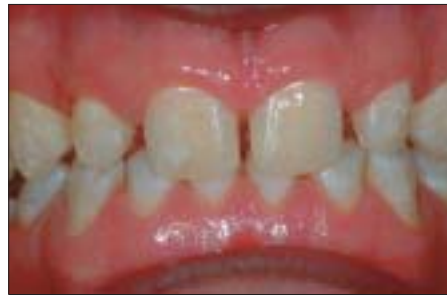

Figure 6. Clinical example of Type IB; altered active eruption case type. Teeth appear short in dimension and there is an adequate zone of attached keratinized gingiva.

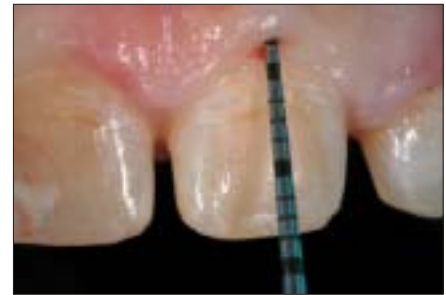

Figure 7. Sounding revealed 4.0 mm from the free gingival margin to the osseous crest. However, sounding was done incorrectly because the probing depth was only 1.0 mm which would mean that the biologic width was 3.0 mm which is 1.0 mm greater than the norm. In thin periodontal biotypes or where there is a thin osseous crest, it is commonly misidentified since the tip of the probe can easily slip off the crest of bone.

crown. This condition has been categorized into type and subcategory. Type denoted the amount of attached gingival and subcategory, the relationship of the osseous crest to the CEJ. Four case types have evolved from this classification system.^{8,9} It is important to delineate that altered '*active*' eruption is reflective of subcategory B, where the osseous crest is at the CEJ (Figures 5 through 9). Altered '*passive*' eruption is indicative of subcategory A, where the osseous crest is *apical* to the CEJ (physiologic norm) Figures 10 through 15. The gingival margin is incisal to the CEJ in all case types and the zone of keratinized attached gingiva is variable.

The esthetic periodontal diagnostic assessment of the smile must establish one of two scenarios:

- Too much gingiva is revealed
- Too little tooth is revealed

Once it is determined that the gingival margin to tooth relationship needs to be modified, evaluation of the periodontium is necessary.

What is commonly referred to as the "gummy smile" is actually excessive gingival display, a condition that can be caused by a variety of factors. Excessive gingival display may be the result of a skeletal deformity, which is due to an overgrowth of the maxilla in the vertical dimension (vertical maxillary excess). This excessive display may also be due to a "short" upper lip or hyperactiv-

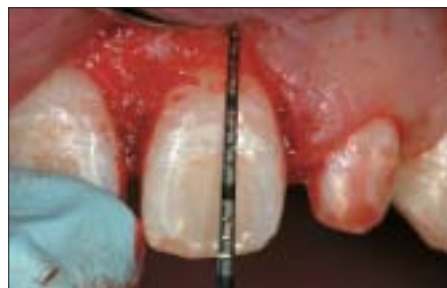

Figure 8. Flap surgery revealed the true position of the osseous crest relative to the CEJ which in this case is at the CEJ. Note that the osseous crest ledge is thin as well as the CEJ quite bulbous leading to an incorrect sounding number of 4.0 mm where a reading of 2.0 should have been registered.

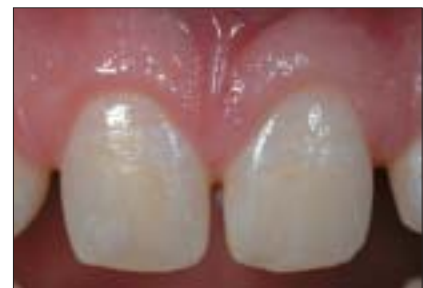

Figure 9. Six months post-healing showing healthy gingival tissues, restoration of proper biologic width, and re-establishment of proper tooth dimensions. Patient is now ready to receive esthetic restorative dentistry. (Surgery courtesy of NYUCD Aesthetic Dentistry Program and Dr. Brian Chadroff.)

Table 1

Classification of Altered Eruption (active and passive)⁹

Type IA

- Osseous crest *apical* to the CEJ (passive)
- Adequate amount of attached gingiva
- Gingival margin incisal to the CEJ

Type IB

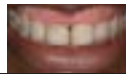Osseous crest at the CEJ (active)
Adequate amount of attached gingiva
Gingival margin incisal to the CEJ

Type IIA

Osseous crest *apical* to the CEJ (passive)
Inadequate amount of keratinized tissue
Gingival margin incisal to the CEJ

Type IIB

Osseous crest at the CEJ (active)
Inadequate amount of keratinized tissue
Gingival margin incisal to the CEJ



SHORT TOOTH

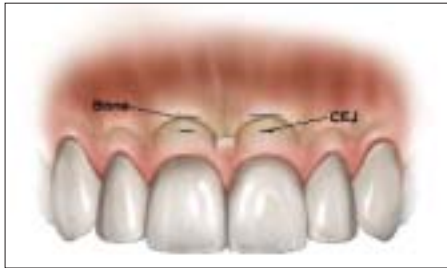

Figure 10. Diagrammatic representation of altered *passive* eruption (Type IA). Note the normal physiologic position of the CEJ relative to the osseous crest. The FGM is higher on the anatomic crown than normal.

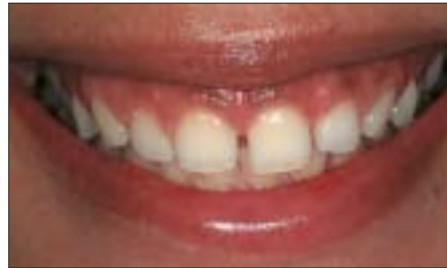

Figure 11. Clinical example altered passive eruption with the associated "gummy" smile.

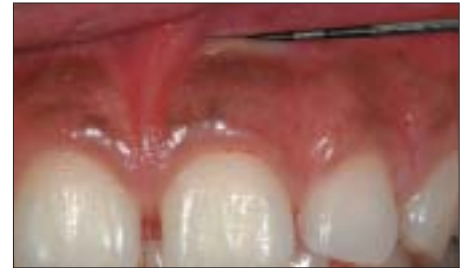

Figure 12. The mucogingival junction (the junction between attached keratinized gingival and mucosal tissue) is identified with a periodontal probe.

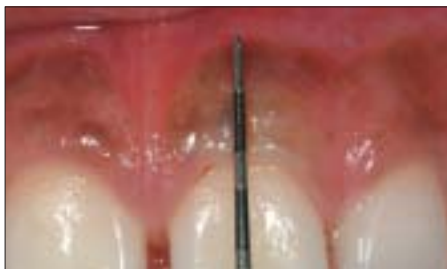

Figure 13. Zone of keratinized tissue is identified and measured with a periodontal probe (7.0 mm in this case).

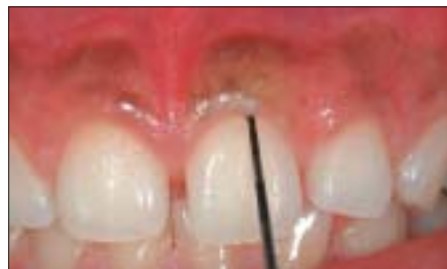

Figure 14. The FGM is more incisal than normal leading to the appearance of a short clinical crown. Pocket depth is measured to be 3.0 mm. The amount of attached keratinized gingival is deduced by subtracting the pocket depth from the zone of keratinized tissue. In this case 7.0 mm - 3.0 mm = 4.0 mm attached keratinized gingival. The average histologic pocket depth is 1.0 mm, which leaves 2.0 mm of free gingival tissue which can be excised without violating the biologic width.

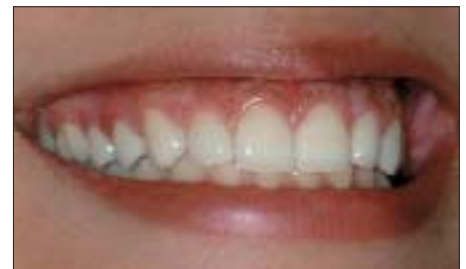

Figure 15. Left lateral smile of patient post-esthetic restorative treatment with ceramic laminate veneers. Proper length of tooth dimension and proportion is restored through gingivectomy and restorative diastema closure. (Surgery courtesy of Dr. Ken Magid and esthetic restorative dentistry by Dr. Saiesha Mistry.)

ity of the obicularis oris muscle.⁶ In addition, the appearance of "too much gum" may be due to physiologically short clinical or anatomic crowns.⁷

The importance of determining the cause of excessive gingival display cannot be overemphasized. If the origin of the excessive gingival display is a skeletal abnormality, then orthognathic surgery and orthodontic procedures should be considered. If the excessive gingival display is a dental deformity then correction of the gingival and osseous architecture is indicated (altered eruption).

The relationship between perioral and intraoral structures is fundamental to dental esthetics. The three structures that compose the smile — the lips, the gingiva, and teeth — must have a harmonious relationship for an acceptable esthetic appearance. During a full smile, the lips determine the amount of both the gingiva and clinical crown that is revealed, and it is the gingiva along with the incisal edge position,

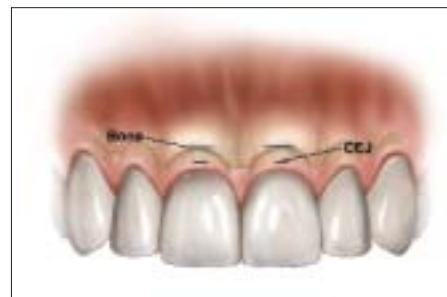

Figure 16. Diagrammatic representation of isolated (central incisors) incisal attrition with compensatory dentoalveolar eruption. Note the normal osseous crest to CEJ relationship yet the more incisal position of the osseous crest of the central incisors relative to the adjacent teeth.

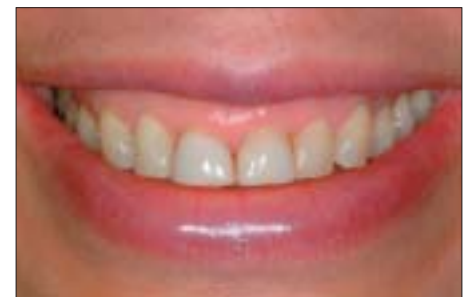

Figure 17. Clinical example during smiling of incisal attrition of the maxillary central incisors with compensatory eruption. Note that the centrals appear too short relative to the adjacent teeth.

that influences the amount of clinical crown that is visible.¹⁰

All of the tissues, soft and hard, follow the contour of the CEJ of the tooth resulting in a normal **parabolic form**. This undulating form is apparent in

the gingival margin, the base of the crevice, the junctional epithelium, the connective tissue attachment and the osseous crest. Appreciation of this relationship is important during tooth preparation procedures. The **finish**



SHORT TOOTH

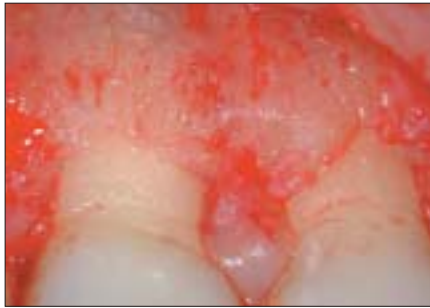

Figure 18. Periodontal flap surgery reveals pattern of bone deposition indicative of tooth eruption. Note the longitudinal or vertical pattern of bone that has been deposited as the tooth erupted after incisal wear.

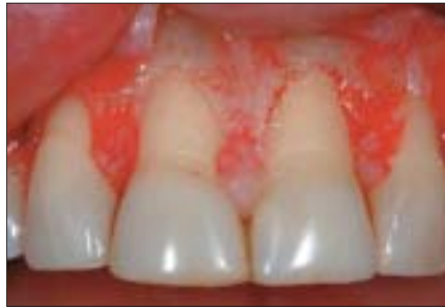

Figure 19. Post-osseous recontouring to re-establish the biologic width and proper tooth dimensions as well as expose adequate tooth structure for esthetic restorative dentistry to be performed.

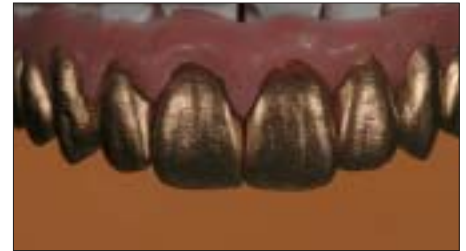

Figure 20. Ceramic laminate veneers are fabricated and contours evaluated with gold powder. (Courtesy of Adam Mielezsko, CDT; MAC Dental Arts, Inc., New York.)

line within the crevice should follow this anatomy otherwise inadvertent invasion of the biologic width can occur.¹¹ (Figure 3.)

Periodontal surgery plays an important role in achieving esthetic outcomes by developing the proper tooth proportion and by placing the gingival margin in a suitable position relative to the lip. Two categories of surgical procedures are utilized, **resection and augmentation**.

In situations where smiling reveals too much tissue or too little tooth, **resective** periodontal procedures are utilized to move the radicular gingival margin apically and at times, the interdental papillae. A variety of procedures are available for this purpose (Table 4). Election of a specific technique is influenced by the relationship of the gingival margin to the underlying osseous crest, the osseous crest relative to the CEJ and the quantity of *attached* keratinized gingiva.

Certain variables must be considered in performing osseous resective surgery when the osseous crest is located at the CEJ (subcategory B). Firstly, the osseous crest is to be established sufficiently apical to the CEJ (2.0 mm minimum) to allow for the formation of the biologic width onto the cementum. The parabolic form of the osseous crest over the radicular surface must mimic the original architecture, that is, thick-flat or thin-scalloped depending upon the periodontal "biotype" present.

Augmentation procedures are em-

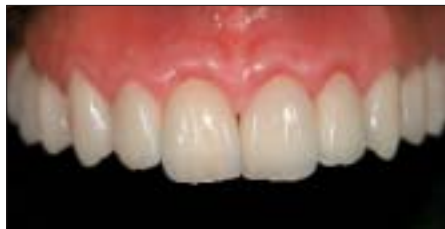

Figure 21. Intraoral view of ceramic veneers three days post-cementation. Note restoration of proper tooth size (length/width dimensions) and proportion (75 percent).

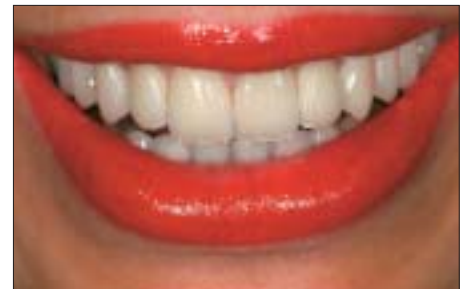

Figure 22. Dentogingival smile analysis showing restoration of proper esthetic parameters tantamount for a successful esthetic outcome. (Surgery courtesy of Dr. Susan Karabin and esthetic restorative dentistry by Dr. Stephen Chu.)

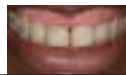
ployed when the clinical or anatomical crown is too long due to mid-facial gingival recession or the zone of attached gingival tissue is insufficient. Bone and tissue grafting and regenerative procedures are used to restore a more physiologic relationship between tooth, bone level, and tissue height.

Incisal Attrition with Compensatory Eruption

Tooth structure loss is physiologic and occurs as a natural consequence of aging and wear (Figures 16, 17). However, several factors including erosion, abrasion and attrition may render tooth structure loss pathologic. In physiological tooth structure loss, vertical dimension is maintained by alveolar bone remodeling; i.e., compensatory tooth eruption resulting in an elongation of the dento-alveolar process (Figures 18 through 22). Despite generalized tooth

surface loss, the freeway space and the resting facial height appear to remain constant due to dentoalveolar compensation¹³ in physiologic attrition due to aging. Similarly, proximal tooth wear is compensated for by compensatory orthodontic tooth movement thereby maintaining tooth to tooth contacts. If isolated pathologic vertical tooth loss has occurred which involves selective teeth, then it is highly likely that compensatory growth has occurred to some degree.¹² In addition, freeway space and vertical dimension of occlusion or VDO, is unaltered in these case types.

If excessive generalized tooth loss affecting occlusal surfaces of the teeth has occurred, then it is highly likely that a reduction in occlusal face height VDO or an increase in freeway space (FWS) has occurred. This diagnosis may be convoluted by forward posturing of the mandible.



SHORT TOOTH

Table 2

Normal physiologic eruption sequence of the permanent dentition¹⁴

Maxilla	Mandible
1st molar	1st molar
Central incisor	central incisor
Lateral incisor	lateral incisor
1st premolar	canine
2nd premolar	1st premolar
Canine	2nd premolar
2nd molar	2nd molar ¹⁴

Table 3

Vertical maxillary excess classification

Degree	Gingival display	Treatment
I	2-4 mm	Orthodontic intrusion only Orthodontics and periodontics Periodontics and restorative therapy
II	4-8 mm	Periodontics and Restorative Therapy Orthognathic Surgery
III	+ 8 mm	Orthognathic Surgery with or without adjunctive periodontal therapy and restorative therapy

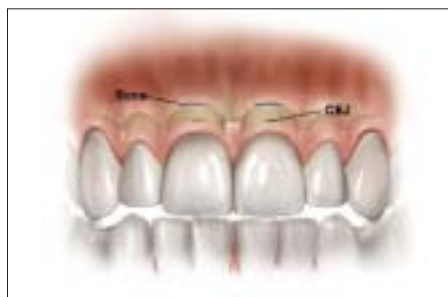

Figure 23. Diagrammatic representation of delayed eruption of the maxillary incisors and excessive eruption of the mandibular incisors. Characteristic is the reverse smile alignment of the anterior teeth and the bi-level occlusal plane and short tooth appearance of the maxillary incisors. Note the normal osseous crest to CEJ relationship. Figure 2 is the clinical smile of such a patient type with STS with lack of incisal tooth display due to delayed eruption of the maxillary incisors (DEMI).

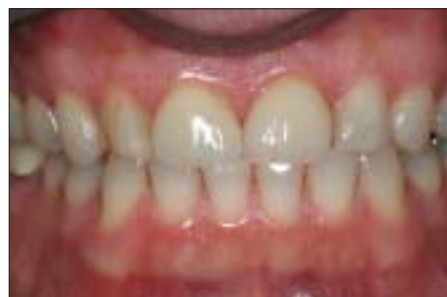

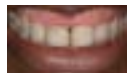Figure 24. Intraoral view of short maxillary anterior teeth due to lack of interocclusal space during eruption. Note the Angle pseudo-Class III relationship.

It has been observed that the FWS remains constant (3.0 mm) in the normal dentition and even in those patients who exhibit significant tooth surface loss, the VDO is unaffected in 80 percent of the cases. This is important with respect to patient assessment. If restoration of worn teeth is being planned then the extent of dentoalveolar compensation would appear to determine the treatment strategy thereby defining the need to carry out measures such as crown lengthening to restore the esthetic clinical crown dimensions. Alternatively, restoration of a patient's dentition may be provided at an increased VDO¹³ if excessive attrition with loss of VDO is identified by an increase in phonetic FWS.

Delayed Eruption of the Maxillary Incisors with Excessive Eruption of the Mandibular Incisors

It is not uncommon that the primary maxillary incisors (A's and B's) can be lost at any early age prior to the final development and eruption of the permanent teeth. Caries and trauma are the most common etiology to early primary tooth loss. Table 2 outlines the normal physiologic eruption sequence for the maxillary and mandibular permanent dentition. Premature loss of the deciduous teeth, when the permanent tooth bud is still deep in the alveolar bone, allows the bone to heal the residual socket in a knife edge contour which further delays the eruption of the permanent tooth.

The delayed eruption of the maxillary anterior dentition frequently allows the mandibular incisors to over-erupt thereby creating an unfavorable esthetic tooth proportion of the anterior teeth (Figures 2, 23). The resultant occlusion tends to be unfavorable as well since a Class III maxillo-mandibular relationship frequently results as the centric occlusion scheme as a consequence of inadequate inte-



SHORT TOOTH

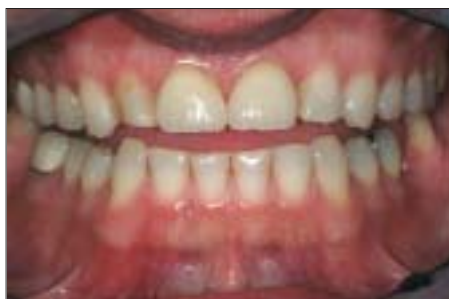

Figure 25. Disarticulated view of the maxillary and mandibular teeth and plane of occlusion. Note the bi-level planes evident between the anterior and posterior teeth for both the maxilla and mandible. The reason why the canines are involved with the mandible anterior plane being more incisal is that the mandibular canines erupt before maxillary canines (Table 2).

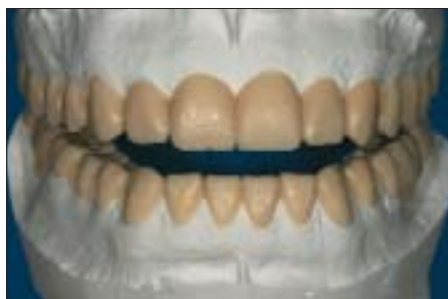

Figure 26. Diagnostic wax up showing corrected occlusal plane through projected esthetic restorative treatment. Note bi-level plane of occlusion is corrected by shortening and retro-inclination of the lower incisors and lengthening of the maxillary incisors. (Courtesy of Jason Kim, CDT; Oral Design, New York.)

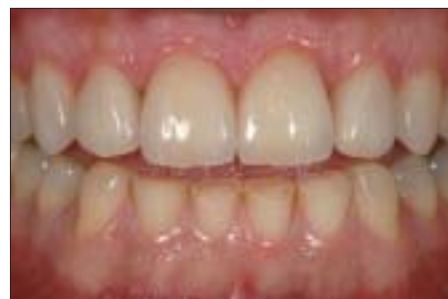

Figure 27. Maxillary anterior dentition is restored with ceramic veneers on Nos. 6,7,10 and 11 and all-ceramic crowns on Nos. 8 and 9. Incisal edges of lower incisors are considerably shortened through selected occlusal adjustment.

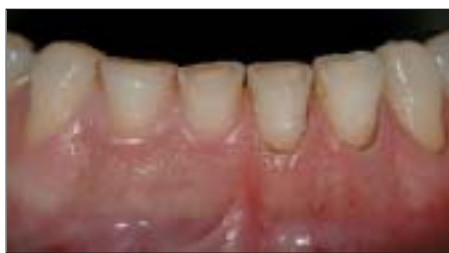

Figure 28. Soft tissue gingivectomy is performed to expose proper crown length. Sounding revealed ampule biologic dimension.

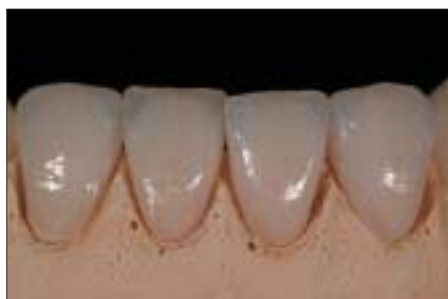

Figure 29. Ceramic laminate veneers are fabricated to restore the lower dentition. Note the internal effects (mamelons) constructed into the ceramic restorations. (Courtesy of Adam Mieszko, CDT; MAC Dental Arts, Inc., New York.)

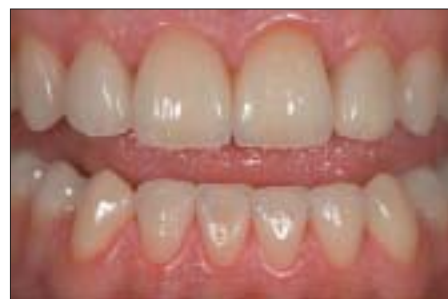

Figure 30. Intraoral view disarticulated showing corrected plane of occlusion with ceramic veneers cemented into place.

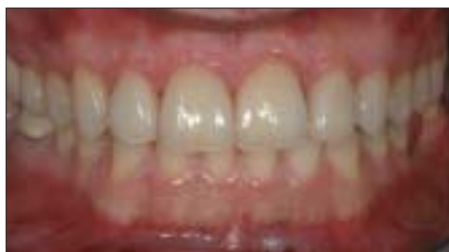

Figure 31. Centric occlusion view showing correction of pseudo-Class III occlusion to a Class I occlusion (Angle Classification).

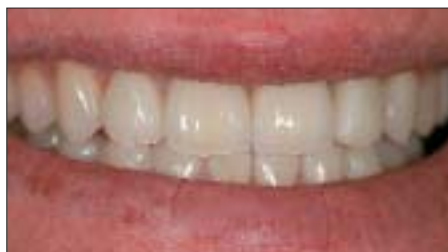

Figure 32. Extraoral smile view showing correction of esthetic parameters through proper diagnosis, case planning, and esthetic restorative dentistry. (Surgery courtesy of Dr. Susan Karabin and esthetic restorative dentistry by Dr. Stephen Chu.)

roccusl space (Figure 24). There is limited interocclusal space to restore the teeth to a more favorable length since the lower incisors are an obstacle due to excessive eruption. The lack of length of the maxillary incisors give the false pretense that there has been a loss or decrease of vertical di-

mension of occlusion. Increasing the VDO in therapeutic correction of the condition would be a mistake since loss of VDO is not the etiology of the delayed eruption case type. Treatment requires orthodontic extrusion of the maxillary sextant and intrusion of the mandibular sextant or in this case,

restoring the maxillary anteriors to the proper length and at the existing VDO by selective incisal reduction of the over-erupted mandibular incisors (Figures 25 through 32). Aggressive correction of the mandibular incisor teeth frequently necessitates crown-lengthening of the dentition in conjunction with restoration with indirect bonded restorations. The crown-lengthening procedure may or may not involve osseous recontouring based upon the amount of over-eruption and incisal reduction required. In addition, elective endodontic therapy may be necessary in severe cases.

Vertical Maxillary Excess

This gummy smile frequently results from a skeletal dysplasia, specifically the hyperplastic growth of the maxillary skeletal base (Figures 33



SHORT TOOTH

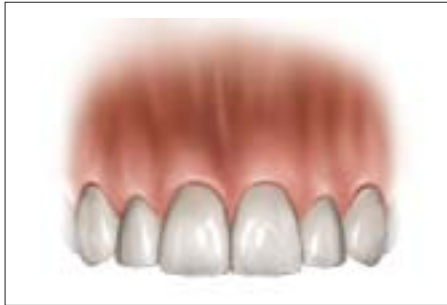

Figure 33. Diagrammatic representation of vertical maxillary excess (VME). The excessive dimension of the maxilla gives the visual appearance that the teeth are too small and short even though they may not be.

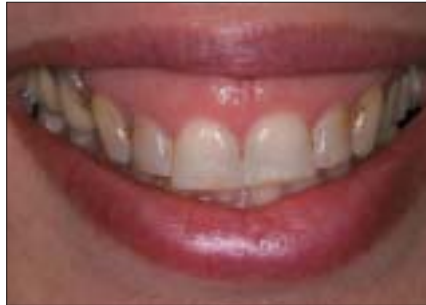

Figure 34. Extraoral full front view of a patient with VME. Note the excessive gingival display at the expense of the hyperplastic development of the maxilla. Teeth appear to be relatively small and are visually overpowered by the gingival tissues.

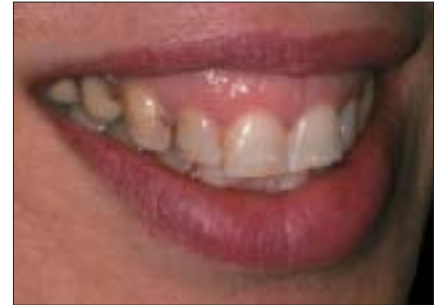
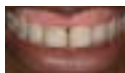
Figure 35. Extraoral lateral view of the same patient. Excessive development of the maxilla is highly evident.

Table 4

Comprehensive summary table for each condition of STS identifying the different diagnoses, etiologies, and treatment regimens recommended

Condition	Etiology	Diagnostic Features	Treatment Regimens
Altered Passive Eruption	Gingival margin fails to recede to a level near the CEJ during tooth eruption	Gingival margin located incisal to the CEJ	Depends on the amount of the attached gingiva and the position of the alveolar crest relative to the CEJ <ul style="list-style-type: none"> – Gingivectomy – Flap surgery with or without ostectomy – Apical positioning of flap
Altered Active Eruption	Osseous crest fails to resorb to a level 2.0 mm apical to the CEJ	Gingival margin located incisal to the CEJ	Periodontal surgery with ostectomy
Compensatory Eruption	Tooth surface loss – Pathologic or excessive	1. Reduction in facial height Increased freeway space (Generalized) 2. VDO unaffected, freeway space constant (Localized)	1. Increase vertical dimension (generalized) 2. Crown lengthening (localized)
Delayed Eruption	Early loss of primary maxillary incisors Delayed eruption of maxillary permanent incisors Over-eruption of mandibular incisors	1. Class III maxillo-mandibular relationship 2. Over-erupted mandibular incisors 3. Short maxillary incisors	1. Selective incisal reduction followed by crown lengthening or orthodontic intrusion of mandibular incisors 2. Orthodontic extrusion of maxillary incisors or restoration
Vertical Maxillary Excess	Skeletal dysplasia such as hyperplastic growth of the maxillary skeletal base	1. Teeth positioned farther away from skeletal base 2. Excessive gingival display	Depends on severity of gingival display <ul style="list-style-type: none"> – Orthodontics – Periodontics – Elective Endodontic Therapy – Restorative Therapy – Orthognathic Surgery



SHORT TOOTH

and 34). This results in the teeth being positioned farther away from the basal skull with excessive display of the gingival dento-alveolar housing below the inferior border of the upper lip (Figure 35). The diagnosis is predicated upon the degree of severity and the classification consists of three degrees depending upon the amount of gingival display (Table 3). The treatment management is quite different for each degree category.

In vertical maxillary excess (the gummy smile) careful evaluation of tooth size is critical. If the clinical crown length is "short" compared to average tooth lengths then a crown-lengthening procedure with the removal of tissue and/or bone is appropriate. If the clinical crown is of normal length but appears short because

of a high lip line and there is a large display of gingival tissues, lengthening these teeth may result in teeth that are too long and can be esthetically unacceptable (Figure 36). This problem can be resolved by shortening the incisal edges of the teeth. However, careful analysis of the periodontal root length, pulp chamber size, and incisal guidance/anterior occlusal scheme must be done prior to deciding on this course of action since there are associated negative consequences such as compromised periodontal support, endodontic involvement, and loss of incisal guidance, respectively.

Summary

The periodontal-restorative team is uniquely positioned to provide the esthetic procedures that today's sophis-

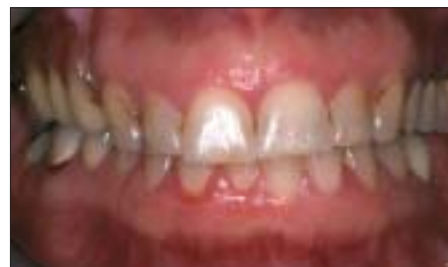
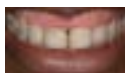
Figure 36. Intraoral view of patient in Figures 34 and 35. Intraoral view is deceptive since excessive growth of maxilla is not obvious in this view and teeth appear to be normal in dimension except for some evidence of generalized incisal attrition. The amount of tooth exposure is predicated upon the smile line to be created, the root length in bone, potential endodontic involvement, and incisal guidance required for anterior disclusion.



SHORT TOOTH

ticated patient population has come to expect. Enhancing one's appearance has become the mantra of the maturing "baby boomer" population. Not only is health and function of great desire but also esthetics is in demand. Armed with periodontal-plastic procedures and technically advanced restorative materials, the periodontal-restorative team can provide these patient needs. The challenge becomes making the correct diagnosis and selecting the appropriate treatment regimen. Each individual patient must be carefully analyzed as to whether their deficiency is anatomic, functional, or both and the consequences of treatment must be fully understood in order to provide the utmost in esthetic periodontal-restorative care (**Table 4**). **CDA**

Reference / 1. Rufenacht CR, Principles of Esthetic Integration: *Quintessence Books*, Carol Stream, IL, 2000.

2. Huntley HE, *The Divine Proportion*, New York, Dover Publications, 1970.

3. Cahill DR, Marks SC Jr., Tooth eruption: evidence for the central role of the dental follicle. *J Oral Pathol Med* 9:189-200, 1980.

4. Wise GE, Frazier-Bowers S, D'Souza RN, Cellular, molecular, and genetic determinations of tooth eruption. *Crit Rev Oral Biol Med* 13(4):323-34, 2002.

5. Garguilo, AW, Wentz FM, Orban B, Dimensions and relations of the dentogingival junction in humans. *J Periodontol* 32:261-7, 1961.

6. Allen EP, Use Of Mucogingival Surgical Procedure To Enhance Esthetics. *Dent Clin North Am* 32:307-330, 1988.

7. Weinberg MA, Eskow R, *An Overview Of Delayed Passive Eruption Compendium*, 21(6) 511, 2000.

8. *Goldman and Cohen Periodontal Therapy*, ed 6. St. Louis.: CV Mosby, p 775, 1980.

9. Evian CI, Cutler SA, Rosenberg ES, Altered Passive Eruption: The Undiagnosed Entity, *JADA* Vol. 124, 107-10, October 1993.

10. Ahmad I, Geometric Considerations in Anterior Dental Aesthetics: Restorative Principles. *Pract Periodont Aesthet Dent* 10(7):813-22, 1998.

11. Kois JC, Altering Gingival Levels: The Restoration Connection. Part I: Biologic Variables.

J Esthet Dent 6:3-9, 1994.

12. Coslet JG, Vandarsall R, Weisgold A: Diagnosis and Classification of delayed passive eruption of the dentogingival junction in the adult. *Alpha Omegan* 70(3):24-8.

13. Davies SJ, Gray RJM, Qualtrogh AJE, Management of Tooth Surface Loss. *BDJ* 192(1):11-23, 2002.

14. Graber TM, Vanarsdall RL, Jr., *Orthodontics: Current principles and techniques*. Mosby Publishing Co., St. Louis, MO, 2000.

To request a printed copy of this article, please contact / Stephen J. Chu, DMD, MSD, CDT, MDT, 205 East 64th St., New York, NY 10021.